



## Case Report

Journal Homepage: <http://crp.tums.ac.ir>

# Hypercalcemia and Lytic Bone Lesions as a Rare Presentation of Acute Lymphoblastic Leukemia: A Case Report



Marjan Mouodi<sup>1</sup>, Soghra Rabizadeh<sup>1</sup>, Hasan Jalaeikhoo<sup>2</sup>, Manouchehr Nakhjavani<sup>1\*</sup>

1. Endocrinology and Metabolism Research Center, Tehran University of Medical Sciences, Tehran, Iran.
2. AJA Cancer Research Center (ACRC), AJA University of Medical Sciences, Tehran, Iran.



**Citation:** Mouodi M, Rabizadeh S, Jalaeikhoo H, Nakhjavani M. Hypercalcemia and Lytic Bone Lesions as a Rare Presentation of Acute Lymphoblastic Leukemia: A Case Report Case Reports in Clinical Practice .2020; 5(2):47-50.

**Running Title:** Hypercalcemia and Acute Lymphoblastic Leukemia

**Article info:**

**Received:** 16 April 2020

**Revised:** 27 April 2020

**Accepted:** 09 May 2020

**Keywords:**

Leukemia; Hypercalcemia; Bone marrow examination

**ABSTRACT**

Acute Lymphoblastic Leukemia (ALL) is a type of leukemia that generates from white blood cells in the bone marrow. ALL could present with different nonspecific symptoms. Hypercalcemia is a rare presentation in B-cell ALL. We reported a middle-aged man presented with hypercalcemia and osteolytic bone lesions without bone pain and a definitive diagnosis of B-cell ALL.

**Introduction**

**H**ypercalcemia is a complication of malignancy and usually presents with nonspecific symptoms, although it could manifest as a life-threatening emergency [1].

Acute Lymphoblastic Leukemia (ALL) is a type of leukemia that results in the malignant proliferation of the

lymphoblast in the bone marrow. ALL accounts for 15% of adult leukemia. Hypercalcemia, in conjunction with the osteolytic bone lesion, is a common feature of several diseases, including multiple myeloma and adult T-cell lymphoma [2]. However, it is a rare manifestation in adult B-cell ALL, and few relevant cases have been reported. The main presentation in the reported cases was bone pain and systemic symptoms, including fever and weight loss. We reported a middle-aged man

\* Corresponding Author:

**Manouchehr Nakhjavani, MD.**

**Address:** Endocrinology and Metabolism Research Center, Tehran University of Medical Sciences, Tehran, Iran.

**E-mail:** [nakhjavanim@tums.ac.ir](mailto:nakhjavanim@tums.ac.ir)

presented with hypercalcemia and osteolytic bone lesions without bone pain and a definitive diagnosis of B-cell ALL.

### Case presentation

A 54-year-old man presented with polyuria and polydipsia. Symptoms started 2 weeks before admission. He reported no complain of bone pain or weight loss. Routine laboratory examination indicated hypercalcemia, and he was referred to the endocrine department for hypercalcemia evaluation.

Past medical history was unremarkable, except for a renal stone that manifested 12 years ago. The physical examination result was normal; he had no lymphadenopathy or hepatosplenomegaly, and spine tenderness.

Laboratory examination revealed the following data: calcium: 12.9 mg/dL , phosphorus: 2.6 mg/dL, serum PTH: 5 pg/mL, 25 OH Vit. D: 23 ng/mL, White Blood Cells (WBC): 6000, hemoglobin: 15 gr/dL, and platelet: 130000. Peripheral blood smear was normal. The other obtained date were as follows: serum albumin: 4.6 g/dL, creatinine:1.3 mg/dL, serum Lactate Dehydrogenase (LDH): 285 U/L, ALKP:140 U/L, and ESR: 13 mm/h. Angiotensin-Converting Enzyme (ACE) level was equal to 25 IU/L (8-65), and 1.25 OH Vit. D was 8pg/mL (15-90) .

ECG result was normal. Skull X-Ray and pelvic X-Ray demonstrated multiple osteolytic lesions. For evaluating malignancy abdominopelvic, a chest Computed Tomography (CT) scan was performed. Accordingly, multiple lytic lesions in the scapula, vertebra, and pelvic

bones were found. Whole-body bone scintigraphy data were normal (Figure 1).

Serum and urine immunoelectrophoresis and immunofixation were normal without monoclonal gammopathy. A Bone Marrow Aspiration and Biopsy (BMA&B) revealed bone trabecular and marrow spaces with 100% cellularity composed of a monomorphous population of large atypical cells with high N/C ratio, fine chromatin, and prominent nucleoli. Megakaryocytes were also decreased. The immunostaining study reported strong staining for CD 34, moderate staining for TdT, and negative results for CD117 and MPO.

According to BMA&B and flow cytometry, acute lymphoblastic leukemia was diagnosed (Figure 2). The patient was treated with Cyclophosphamide, Vincristine, and Adriamycin, Dexamethasone (CVAD chemotherapy regimen). Evaluation conducted after the treatment revealed complete hematological response and serum calcium reduced to 8.5 mg/dL. However, after one year, the patient developed sepsis with mucormycosis infection and passed away.

### Discussion:

We described a patient presented with polyuria and polydipsia due to hypercalcemia. Despite lytic bone lesions, he reported no complain of bone pain and demonstrated no constitutional symptoms. He had no anemia, and ESR was normal. B-cell ALL rarely presents with hypercalcemia in adults. We could find 10 cases in the literature, i.e., illustrated in Table 1 [7-12]. In the reported cases, the range of patients' age was 22-53 years.

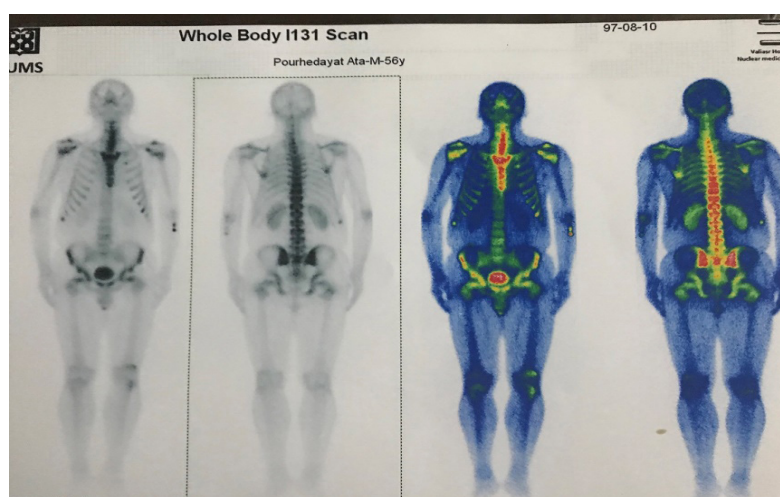
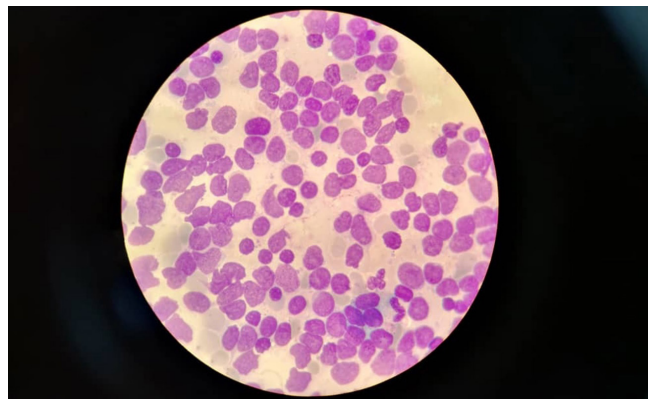


Figure 1. Whole-body bone scintigraphy

\*There was no evidence of uptake in the bone lesions.



**Figure 2.** The bone marrow aspiration suggesting multiple immature lymphocytes in favor of acute leukemia



Bone pain and systemic symptoms, such as fever and weight loss, were the main presentations. Nine of ten reported cases had anemia.

Hypercalcemia is an uncommon albeit well-recognized biochemical feature of childhood malignancies,

including acute lymphoblastic leukemia [1]. ALL is the most prevalent hematologic malignancy in children. Additionally, 0.3% to 4.8% of patients present comorbid hypercalcemia and lytic bone lesions [2]. Hypercalcemia, in conjunction with osteolytic bone lesions,

**Table 1.** ALL case reports with hypercalcemia and lytic bone lesions

Study	Age (y)/Gender (Male/Female)	Presentation	Lab Data	Imaging	Diagnosis
EL-Ashwah, 2018	28/M	Bone pain, weight loss	Ca: 12.5 Hgb: 9.2	Osteolytic bone lesion	B-ALL
EL-Ashwah, 2018	27/F	Frequency, bone pain	Ca: 13.1 Hgb: 8.9	Osteolytic bone lesion	B-ALL
Narayanan, 2017	43/M	Backache, weight loss, vomiting	Ca: 18.2 Hgb: 8.5	Osteolytic bone lesion	B-ALL
K Mahmood, 2017	22/M	Generalized fatigue, bone pain	Ca: 14.6 Hgb: 6.2	Osteolytic bone lesion	B-ALL
Grancher, 2017	34/M	Back pain	Ca: 12.6 PLT: 79000	Osteolytic bone lesion	B-ALL
Zou, 2017	47/M	Abdominal pain, vomiting, bone pain	Ca: 17.8 Hgb: 10.1	Osteolytic bone lesion	B-ALL
Virijevic, 2016	28/M	Weight loss, bone pain, hepatosplenomegaly	Ca: 10.4 Hgb: 10.7	Osteolytic bone lesion	B-ALL
Neupane, 2015	23/M	Fever, night sweats	Ca: 14, PTHrp: 0.4 pmol/L Hgb: 12	Osteolytic bone lesion	B-ALL
Fukasawa, 2001	53/F	Nausea, drowsiness, bone pain	Ca: 15.2, PTHr<1.1 Hgb: 7.7	Osteolytic bone lesion	B-ALL
Antunovic, 1998	24/M	Weakness, bone pain, vomiting	Ca: 4 meq/L Hgb: 7.4	Osteolytic bone lesion	T-ALL
Our report	54/M	Polyuria and polydipsia	Ca: 12 Hgb: 15	Osteolytic bone lesion	B ALL

\*Age in years; M: Male; F: Female; Ca: Calcium; Hgb: Hemoglobin



is a frequent feature of multiple myeloma. Negative serum and urine protein electrophoresis in the setting of hypercalcemia and lytic bone lesions should prompt physicians to consider alternative diagnoses, including lymphoma and leukemia [3].

Skeletal manifestations are rare presenting features in adult patients with ALL [4]. The mechanisms leading to the lytic lesions in ALL remain uncertain [5]. Two general mechanisms explain malignancy-associated hypercalcemia, osteolytic lesions due to the direct invasion of the skeleton by tumor cells and the ectopic production of circulating factors that activate osteoclastic bone resorption. The main factors are the osteolytic PTH-related protein (PTHrp) [6].

## Conclusion:

We presented a patient with hypercalcemia and osteolytic bone lesions. The results of further evaluations, such as serum and urine protein electrophoresis and total bone scan, were normal. Acute B-cell ALL was diagnosed according to BMA&B.

## Ethical Considerations

### Compliance with ethical guidelines

Compliance with ethical guidelines: All ethical principles were considered in this article.

### Funding

This work was supported, in part, by the Imam Khomeini Hospital Complex research center.

### Conflict of interest

The authors declared no conflicts of interest.

## References

- [1] Trehan A, Cheetham T, Bailey S. Hypercalcemia in acute lymphoblastic leukemia: An overview. *Journal of Pediatric Hematology/Oncology*. 2009; 31(6):424-7. [DOI:10.1097/MPH.0b013e3181a1c12b] [PMID]
- [2] Mahmood K, Ubaid M, Taliya Rizvi S. Multiple osteolytic lesions causing hypercalcemia: A Rare presentation of acute lymphoblastic leukemia. *Case Reports in Medicine*. 2017; 2017:2347810. [DOI:10.1155/2017/2347810] [PMID] [PMCID]
- [3] Alhaj Moustafa M, Seningen JL, Jouni H. Hypercalcemia, renal failure, and skull lytic lesions: Follicular lymphoma masquer-

ading as multiple myeloma. *Journal of Investigative Medicine High Impact Case Reports*. 2013; 1(2):2324709613486356. [DOI:10.1177/2324709613486356] [PMID] [PMCID]

- [4] Narayanan G, Unnikrishnan P, Kumar BS. Hypercalcemia and osteolytic lesion as presenting feature in an adult PH positive acute lymphoblastic leukemia patient mimicking multiple myeloma. *European Journal of Pharmaceutical and Medical Research*. 2017; 4(3):490-1. [https://www.ejpmr.com/home/abstract\\_id/2173](https://www.ejpmr.com/home/abstract_id/2173)
- [5] El-Ashwah S, Eisa N, Denewer M, Essam Y, Atef B, El-Badrawy A, et al. Hypercalcemia with disseminated osteolytic lesions: A rare presentation of adulthood acute lymphoblastic leukemia. *Journal of Hematology*. 2018; 7(4):154-7. [PMID] [PMCID]
- [6] Bechir A, Haifa R, Atef BA, Emna B, Asma A, Nesrine BS, et al. Osteolytic bone lesions, severe hypercalcemia without circulating blasts: Unusual presentation of childhood acute lymphoblastic leukemia. *The Pan African Medical Journal*. 2017; 26:244. [DOI:10.11604/pamj.2017.26.244.10506] [PMID] [PMCID]
- [7] Granacher NCP, Berneman ZN, Schroyens W, Van de Velde ALR, Verlinden A, Gadisseur APA. Adult acute precursor B-cell lymphoblastic leukemia presenting as hypercalcemia and osteolytic bone lesions. *Experimental Hematology & Oncology*. 2017; 6:9. [DOI:10.1186/s40164-017-0071-8] [PMID] [PMCID]
- [8] Zou S, Shen Y, Zhu D, Zhang D, Zhu X. Adult B-cell acute lymphoblastic leukemia dominated by osteolytic bone involvement on CT but less impressive PET on FDG PET/CT images. *Clinical Nuclear Medicine*. 2017; 42(6):467-70. [DOI:10.1097/RLU.0000000000001653] [PMID]
- [9] Virijevic M, Vidović A, Colović N, Džunić I, Mitrović M, Suvajdžić-Vuković N, et al. Hypercalcemia with multiple osteolytic lesions and increased circulating tumor necrosis factor in an adult patient with B-cell acute lymphoblastic leukemia. *Srpski Arhiv za Celokupno Lekarstvo*. 2016; 144(3-4):207-10. [DOI:10.2298/SARH1604207V] [PMID]
- [10] Fukasawa H, Kato A, Fujigaki Y, Yonemura K, Furuya R, Hishida A. Hypercalcemia in a patient with B-cell acute lymphoblastic leukemia: A role of proinflammatory cytokine. *The American Journal of the Medical Sciences*. 2001; 322(2):109-12. [DOI:10.1097/00000441-200108000-00009] [PMID]
- [11] Antunovic P, Marisavljevic D, Kraguljac N, Jelusic V. Severe hypercalcemia and extensive osteolytic lesions in an adult patient with T cell acute lymphoblastic leukemia. *Medical Oncology*. 1998; 15(1):58-60. [DOI:10.1007/BF02787346] [PMID]
- [12] Neupane S, Clines GA, Auchus RJ, Arvan P. Hypercalcemia and osteolytic bone lesions: a surprising etiology. *The Endocrine Society's 97<sup>th</sup> annual meeting and expo*, March 6, 2015. <https://endo.confex.com/endo/2015endo/webprogram/Paper19482.html>