



## A New Physical Modality for Renal Stone Management: A Case Report

Gholamreza Raissi<sup>1</sup>, Maryam Rafiei<sup>2</sup>, Tannaz Ahadi<sup>1</sup>

1- Department of Physical Medicine and Rehabilitation, School of Medicine, Neuromusculoskeletal Research Center, Iran University of Medical Sciences, Tehran, Iran

2- Department of Physical Medicine and Rehabilitation, School of Medicine, Neuromusculoskeletal Research Center, Iran University of Medical Sciences, Tehran, Iran

**Received:** 18 July 2016

**Revised:** 9 October 2016

**Accepted:** 2 November 2016

### ARTICLE INFO

Corresponding author:  
Tannaz Ahadi

Email:  
[tannaz.ahadi@yahoo.com](mailto:tannaz.ahadi@yahoo.com)

Keywords:  
Kidney calculi;  
Rehabilitation;  
Ultrasound wave

### ABSTRACT

This report described an innovative nonsurgical method for management of unsuccessful renal stone expulsion. Our patient was a 43-year-old physician with a history of two distinct episodes of renal stone entrapping in distal ureter and nonresponsive to shock wave lithotripsy, and oral medication recommended to treat by surgery. Fortunately, renal stones were expelled by whole body vibration technique without any surgical procedure.

**Citation:** Raissi G, Rafiei M, Ahadi T. **A New Physical Modality for Renal Stone Management: A Case Report.** *Case Rep Clin Pract* 2016; 1(3): 78-80.

### Introduction

Renal stones are a common problem with substantial morbidities and economic costs. Shock wave lithotripsy (SWL) is one of the most common techniques that significantly reduce the morbidity of stone removal and it is the treatment of choice for most small renal calculi; however, it is not an ideal modality for the management of complex or large calculi. Whole body vibration (WBV) generates an oscillating movement on a plate

and transmits vertical acceleration to muscle and bone. Skeletal muscles vibration causes muscle spindles response termed a “tonic vibration reflex.” The results of our study may be explained by causing intermittent contraction of ureters and urethra wall muscles and facilitation of stone fragments passage via usage of WBV after SWL.

### Case Report

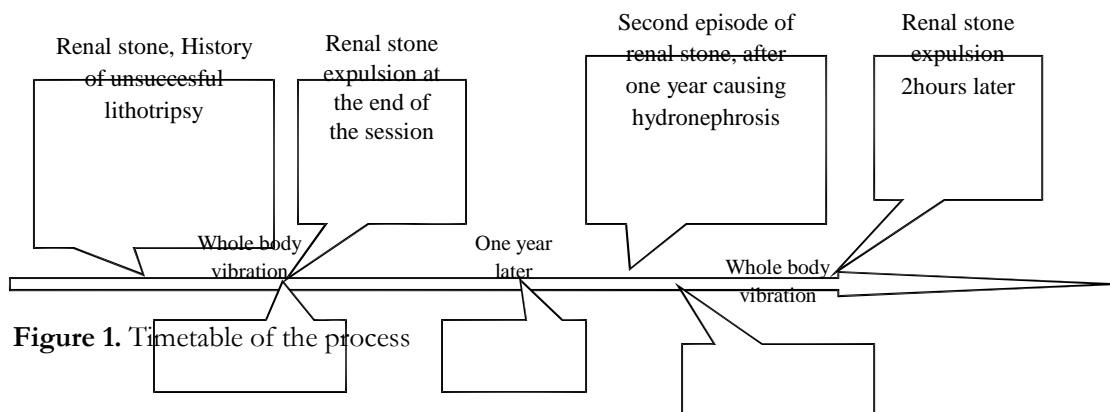
A 43-year-old male physician, experienced 10 mm renal stone 2 years ago, the stone was

in upper part of urethra; shock wave was prescribed. Unfortunately, a 6 mm stone was entrapped in distal ureter, a course of Tamsulosin, ibuprofen was not effective, considering the presence of hydronephrosis, surgical intervention was recommended. A course of WBV was tried. It was performed in different frequency from 25 to 50 Hz with 5 Hz interval (NetWBV, Iran) and different positions including standing, sitting, sitting with knee bending sitting and bending to each side for 45 minutes each episode was 90 seconds with short restes between sessions. Renal stone was expelled at the end of 45 minutes of WBV. One year later, another episode of renal stone was experienced. The stone was in distal urethral part with Grade 1 hydronephrosis. Another session of WBV for 45 minutes was tried. The stone was expelled about two hours after WBV figure 1.

**Discussion**

Renal stones are a common problem worldwide with substantial morbidities and economic costs. The lifetime risk for kidney stone disease currently exceeds 6-12% in the general population (1). Considerable progress has been made in the management of nephrolithiasis over the last 20 years, but approximately, 10-20% of all kidney stones still require surgical removal. SWL is one of the most common techniques that significantly reduce the morbidity of stone removal and it is the treatment of choice for most small renal calculi. However, SWL is not an ideal modality for the management of

complex or large calculi. The guidelines suggest that for patients with a ureteral stone < 10 mm and well-controlled symptoms, a period of observation along with medical expulsive therapy is an option for initial treatment, and recommend  $\alpha$ -1 blockers as the preferred agents for medical expulsion therapy (2). WBV is a relatively new exercise training mode that has shown to improve muscle strength and mass (3, 4), bone mineral density (5), and glycemic control (6). It generates an oscillating movement on a plate and transmits vertical acceleration to muscle and bone (7). Its mechanism of stimulating muscle spindles and alpha motor neurons initiates reflex muscle contractions (8). A single bout of whole body low-intensity vibration has been shown to increase systemic and regional (i.e., skin) blood flow (9-12). Application of vibration to skeletal muscles causes a response harmonized to frequencies of vibration in muscle spindles, termed a “tonic vibration reflex” (13, 14). Underlying mechanism involves the stimulation of the neuromuscular spindles by rapid and transient muscle stretching, which boosts the feedback of the myelinated Ia fibers. The effect of vibration on smooth muscles has been studied mainly in vascular system. To date, the effects of WBV on the peripheral vasculature perfusion remain inconclusive. Whether, mechanical WBV has mechanical effect or effects on ureter peristalsis may help to find the appropriate vibration frequency. Further research in this field may reveal potential effects of WBV in renal stone management.



**Figure 1.** Timetable of the process

### Conflict of Interests

Authors have no conflict of interests.

### Acknowledgments

The authors appreciate guidance of Draius Reissi MD, nephrologist, for his comments and guidance.

### References

1. Stamatelou KK, Francis ME, Jones CA, Nyberg LM, Curhan GC. Time trends in reported prevalence of kidney stones in the United States: 1976-1994. *Kidney Int* 2003; 63(5): 1817-23.
2. Preminger GM, Tiselius HG, Assimos DG, Alken P, Buck C, Gallucci M, et al. 2007 guideline for the management of ureteral calculi. *J Urol* 2007; 178(6): 2418-34.
3. Machado A, Garcia-Lopez D, Gonzalez-Gallego J, Garatachea N. Whole-body vibration training increases muscle strength and mass in older women: a randomized-controlled trial. *Scand J Med Sci Sports* 2010; 20(2): 200-7.
4. Delecluse C, Roelants M, Verschueren S. Strength increase after whole-body vibration compared with resistance training. *Med Sci Sports Exerc* 2003; 35(6): 1033-41.
5. Verschueren SM, Roelants M, Delecluse C, Swinnen S, Vanderschueren D, Boonen S. Effect of 6-month whole body vibration training on hip density, muscle strength, and postural control in postmenopausal women: a randomized controlled pilot study. *J Bone Miner Res* 2004; 19(3): 352-9.
6. Baum K, Votteler T, Schiab J. Efficiency of vibration exercise for glycemic control in type 2 diabetes patients. *Int J Med Sci* 2007; 4(3): 159-63.
7. Rauch F, Sievanen H, Boonen S, Cardinale M, Degens H, Felsenberg D, et al. Reporting whole-body vibration intervention studies: recommendations of the International Society of Musculoskeletal and Neuronal Interactions. *J Musculoskelet Neuronal Interact* 2010; 10(3): 193-8.
8. Rauch F. Vibration therapy. *Dev Med Child Neurol* 2009; 51(Suppl 4): 166-8.
9. Lohman EB 3<sup>rd</sup>, Petrofsky JS, Maloney-Hinds C, Betts-Schwab H, Thorpe D. The effect of whole body vibration on lower extremity skin blood flow in normal subjects. *Med Sci Monit* 2007; 13(2): CR71-CR76.
10. Stewart JM, Karman C, Montgomery LD, McLeod KJ. Plantar vibration improves leg fluid flow in perimenopausal women. *Am J Physiol Regul Integr Comp Physiol* 2005; 288(3): R623-R629.
11. Adams JA, Mangino MJ, Bassuk J, Kurlansky P, Sackner MA. Regional blood flow during periodic acceleration. *Crit Care Med* 2001; 29(10): 1983-8.
12. Maloney-Hinds C, Petrofsky JS, Zimmerman G. The effect of 30 Hz vs. 50 Hz passive vibration and duration of vibration on skin blood flow in the arm. *Med Sci Monit* 2008; 14(3): CR112-CR116.
13. Burke D, Hagbarth KE, Skuse NF. Recruitment order of human spindle endings in isometric voluntary contractions. *J Physiol* 1978; 285: 101-12.
14. Hagbarth KE, Eklund G. Tonic vibration reflexes (TVR) in spasticity. *Brain Res* 1966; 2(2): 201-3.