



A 16-Year-Old Man with Vivax Malaria and Very Severe Thrombocytopenia

Fereshteh Ghasvand¹, Hamid Emadi-Kuchak², Mohammadreza Salehi²

1- Department of Infectious Diseases, School of Medicine, Imam Khomeini Hospital, Tehran University of Medical Sciences, Tehran, Iran

2- Department of Infectious Diseases, School of Medicine, Tehran University of Medical Sciences, Tehran, Iran

Received: 22 December 2016

Revised: 17 January 2017

Accepted: 16 March 2017

ARTICLE INFO

Corresponding author:
Fereshteh Ghasvand

Email:
ghiasvand_62@yahoo.com

Keywords:
Malaria;
Plasmodium vivax;
Thrombocytopenia

ABSTRACT

Thrombocytopenia during the clinical course of *Plasmodium falciparum* malaria has been reported in different studies. However, for *Plasmodium vivax* malaria, profound thrombocytopenia (i.e., a platelet count below 20,000/ μ l), is infrequent. In this paper, we want to report of a case of vivax malaria with very severe thrombocytopenia. A 16-year-old man was examined in the emergency department because of fever, epistaxis, and very severe thrombocytopenia. In his phosphate-buffered saline evaluation, malaria vivax was confirmed. Artesunate because of severe malaria was begun. The fever was stopped after 24 hours. The last platelets count was 185,000, and the patient was discharged with good condition. In conclusion, very severe thrombocytopenia as a complication of *P. vivax* malaria is rare; however, it may be manifested by the skin and mucous membrane bleeding and result in more severe complications, therefore prompt antimalarial treatment may lead to satisfactory outcome.

Citation: Ghasvand F, Emadi-Kuchak H, Salehi M. A 16-Year-Old Man with Vivax Malaria and Very Severe Thrombocytopenia. Case Rep Clin Pract 2017; 2(1): 5-8.

Introduction

Thrombocytopenia during the clinical course of *Plasmodium falciparum* malaria has been reported in different studies. However, for *Plasmodium vivax* malaria, profound thrombocytopenia is infrequent. Peripheral destruction of platelets is induced by *P. falciparum*, in

which immune complexes generated by malarial antigens result in sequestration of the destroyed platelets by macrophages in the spleen, but this mechanism has not been explained in *P. vivax* malaria (1). In this paper, we want to report of a case of vivax malaria with very severe thrombocytopenia.

Case Report

A 16-year-old man was examined in the emergency department because of fever, epistaxis, and thrombocytopenia.

10 days earlier, he becomes from Afghanistan, during the trip, he did not have any problems, and after 5 days, he had fever with chills, nausea, vomiting, and abdominal pain. His fever was persistent. His abdominal pain was occasionally and was generalize. He had received serum therapy as an outpatient but he was not being well. After 4 days of beginning the fever, he had a self-limit epistaxis and tomorrow of that day, he came to the emergency department of this hospital with severe epistaxis and fever as high as 39 °C. He did not have the history of mosquito netting or contact with animals. He did not use alcohol, tobacco, or illicit drugs. He did not have any sexual contact. He did not have any vaccination history too.

In physical examination, he had temperature rose as high as 39 °C orally. His blood pressure was about 100/80 mmHg; respiratory rate was 22 and pulse rate was 110. He had an icteric sclera and petechial rash in generalized of skin. Other examinations were normal. Hematologic laboratory tests were performed (Table 1). The urine analysis was normal without hematuria. The levels of calcium, phosphorus, electrolytes, magnesium, amylase, and lipase were normal.

The complete blood count at the first time had 2100 white blood cell, 8000 platelets; the hemoglobin was about 11/7 mg/dl. His liver function test was abnormal (aspartate transaminase: 105, alanine transaminase: 76, alkaline phosphatase: 406, total bilirubin: 11/5, direct bilirubin: 7/7, international normalized ratio: 1/8, prothrombin time: 25, and partial thromboplastin time: 30). His blood sugar was 45. Cultures of two blood samples and a culture of the urine were sterile. At first, he had peripheral blood smear without evidence of malaria. He received 10-unit platelet and because of his fever and hemorrhage, doubt to Crimean-Congo hemorrhagic fever, he received ribavirin, and because of probable bacteremia ceftriaxone and clindamycin were gave to patient, then his phosphate-buffered saline evaluate again, and malaria vivax was confirmed (Figure 1).

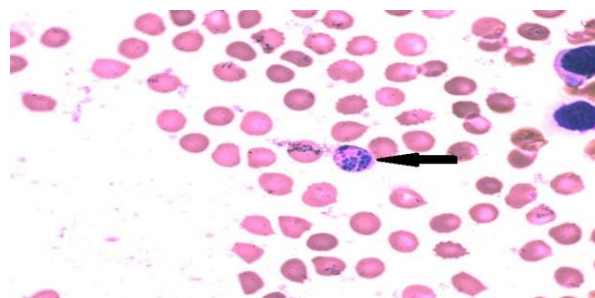


Figure 1. Peripheral-blood smear showing a *Plasmodium vivax* schizont within a red cell

Table 1. Hematologic laboratory data

Variable	1 st day	2 nd day	3 rd day	Last day
Hemoglobin	11/7	9/6	9/1	9/1
White cells (per mm ³)	2100	3100	3600	6800
Platelet count (per mm ³)	8000	4000	3000	185,000
Erythrocyte sedimentation rate (mm/h)	25			
Total bilirubin (mg/dl)	11.5	1.3		
Phosphorus (mg/dl)	3			
Albumin (g/dl)	2.7			
Sodium (mmol/l)	134			
Potassium (mmol/l)	4			
ALT	75			
AST	105			
ALP	406			
PT	25			
PTT	30			
INR	1.8			

ALT: Alanine transaminase; AST: Aspartate aminotransferase; ALP: Alkaline phosphatase; INR: International normalized ratio; PT: Prothrombin time; PTT: Partial thromboplastin time

The ribavirin and clindamycin were held and artesunate because of his severe epistaxis and thrombocytopenia were begun. The dose of artesunate was 2/4 mg/kg for 3 times with 12 hours' duration, and then, patient received it daily for 7 days. One dose of fansidar (three tablets) was given to him. Glucose-6-phosphate dehydrogenase was checked, and it was sufficient and he received primaquine (15 mg daily) at the 3rd day of treatment. The fever was stopped after 24 hours, but thrombocytopenia continued. The patient received platelets for 3 days. The last platelets count was 185,000. The percent of a parasitemia reduced after treatment. The patient was discharged with primaquine and good condition.

Discussion

Severe complicated malaria is a known feature of *P. falciparum* malaria which usually manifests as cerebral malaria, but other complications such as severe thrombocytopenia frequently are seen. These associations with *P. vivax* are very rare although a few cases have been reported in literature (2).

So far, thrombocytopenia and its pathogenesis in malaria remain contemplative. Fajardo (3) hypothesized that directs lytic effect of the parasite on the platelets result in thrombocytopenia.

Other earlier studies revealed disseminated intravascular coagulation as an etiology of this situation, but it was shown that most such cases did not show degradation of fibrin products that is characteristic of disseminated intravascular coagulation (4).

Elevated recombinant-macrophage colony-stimulating factor levels in malaria may lead to platelet destruction because of enhanced macrophage activity (5).

Other probable mechanisms are bone marrow dysmyelopoiesis (6) and platelet phagocytosis (7).

Except India, a large number of endemic countries, including the Greater Mekong subregion, Northeast China, North Korea,

Bangladesh, Afghanistan, the Middle East (except Qatar), Somalia, and Madagascar, do not report severe vivax malaria.

Although vivax malaria is an important cause of hospital admission in endemic areas, a major problem in detecting the real incidence and prevalence of severe vivax malaria is that severe disease has been considered relatively infrequent in vivax malaria (8).

In contrast, Antinori et al.'s study (9) proposes that the prognostic role of severe thrombocytopenia is not clear in the absence of severe hemorrhagic complications and its use as diagnostic criterion of malaria severity may lead to overestimation of severe *P. vivax* malaria cases. This study concluded that because of the shortage of studies, at present it is ambiguous if severe thrombocytopenia in the setting of *P. vivax* malaria should be considered indicative of severe malaria.

In a very large hospital-based surveillance study, almost two thirds of patients with acute malaria had thrombocytopenia (platelet count < 150,000 platelets/ μ l), but platelet counts of < 50,000 platelets/ μ l was seen just in 13% of patients and of course the greatest risk of severe thrombocytopenia was in patients infected with *P. falciparum* and very severe thrombocytopenia (platelet count < 20000 platelets/ μ l) was seen in patient with *P. falciparum* much more than patients with vivax malaria, the results of this study revealed that severe thrombocytopenia can increase the risk of death from falciparum or vivax malaria in both children and adults (10).

Our patient did not have documented platelet count before his hospitalization. However, the absence of a history of bleeding problems suggests that the present episode of profound thrombocytopenia (i.e., 8000 platelets/ μ l) was the result of the infection by the vivax malarial parasite.

As a conclusion, Very severe thrombocytopenia as a complication of *P. vivax* malaria is rare; however, it may be manifested by the skin and mucous membrane bleeding and result in more severe

complications; therefore, prompt antimalarial treatment may lead to the satisfactory outcome.

Conflict of Interests

Authors have no conflict of interests.

Acknowledgments

Authors would like to thank Dr. Arash Seifi for editing an earlier version of this manuscript.

References

1. Rodriguez-Morales AJ, Sanchez E, Vargas M, Piccolo C, Colina R, Arria M, et al. Occurrence of thrombocytopenia in Plasmodium vivax malaria. *Clin Infect Dis* 2005; 41(1): 130-1.
2. Harish R, Gupta S. Plasmodium vivax malaria presenting with severe thrombocytopenia, cerebral complications and hydrocephalus. *Indian J Pediatr* 2009; 76(5): 551-2.
3. Fajardo L. Malarial parasites within human platelets. *JAMA* 1974; 229(9): 1205-7.
4. Stuart J. Intravascular coagulation in falciparum malaria. *Br Med J* 1978; 2(6139): 774.
5. Lee SH, Looareesuwan S, Chan J, Wilairatana P, Vanijanonta S, Chong SM, et al. Plasma macrophage colony-stimulating factor and P-selectin levels in malaria-associated thrombocytopenia. *Thromb Haemost* 1997; 77(2): 289-93.
6. Ghosh K, Shetty S. Blood coagulation in falciparum malaria--a review. *Parasitol Res* 2008; 102(4): 571-6.
7. Jaff MS, McKenna D, McCann SR. Platelet phagocytosis: A probable mechanism of thrombocytopenia in Plasmodium falciparum infection. *J Clin Pathol* 1985; 38(11): 1318-9.
8. Rahimi BA, Thakkestian A, White NJ, Sirivichayakul C, Dondorp AM, Chokejindachai W. Severe vivax malaria: a systematic review and meta-analysis of clinical studies since 1900. *Malar J* 2014; 13: 481.
9. Antinori S, Corona A, Ridolfo AL, Galimberti L, Ricaboni D, Milazzo L, et al. Imported Plasmodium vivax malaria with severe thrombocytopenia: Can it be severe malaria or not? *Malar J* 2016; 15: 105.
10. Lampah DA, Yeo TW, Malloy M, Kenangalem E, Douglas NM, Ronaldo D, et al. Severe malarial thrombocytopenia: a risk factor for mortality in Papua, Indonesia. *J Infect Dis* 2015; 211(4): 623-34.