



Case Report

Journal Homepage: <http://crp.tums.ac.ir>

The Occurrence of Extensive Subcutaneous Emphysema and Pneumothorax after Endotracheal Tube Removal: A Case Report

Alireza Rahat Dahmardeh¹, Aliakbar Keykha^{2,3*}

1. Department of Anesthesiology and Critical Care, School of Medicine, Zahedan University of Medical Sciences, Zahedan, Iran.

2. Community Nursing Research Center, Zahedan University of Medical Sciences, Zahedan, Iran.

3. Department of Medical-Surgical Nursing, School of Nursing and Midwifery, Zahedan University of Medical Sciences, Zahedan, Iran.

Use your device to scan and read the article online



Citation Rahat Dahmardeh A, Keykha A. The Occurrence of Extensive Subcutaneous Emphysema and Pneumothorax after Endotracheal Tube Removal: A Case Report. Case Reports in Clinical Practice. 2024; 9(6): 281-288. DOI:10.18502/crcp.v9i6.18949

Running Title Subcutaneous Emphysema and Pneumothorax after Endotracheal Tube Removal

**Article info:**

Received: November 13, 2024

Revised: November 29, 2024

Accepted: December 17, 2024

Keywords:

Pneumothorax; Mechanical ventilation; Subcutaneous emphysema; Foreign body aspiration; Respiratory aspiration

ABSTRACT

Both pneumothorax and subcutaneous emphysema (SCE) after extubation are very rare. Pneumothorax occurs due to lung structure rupture, whereas SCE develops if an air leak persists. In this case report, we describe a patient with stone aspiration who developed severe SCE and pneumothorax after extubation. The patient was a 5-year-old Iranian boy of Baluch ethnicity who had accidentally aspirated a stone. The otolaryngologist attempted removal via bronchoscopy but was unsuccessful and ordered the patient's transfer to a better-equipped center. We attempted to extubate the patient before his transfer; however, after the endotracheal tube was removed, he developed severe SCE. As a result, we had to re-intubate the patient and place him on mechanical ventilation. Pneumothorax is an underappreciated complication of foreign body aspiration (FBA) that can occur even in the absence of high-pressure ventilation. The timing of pneumothorax development can be unpredictable, and clinicians should maintain a high level of suspicion for quick diagnosis and treatment.

Introduction

Foreign body aspiration (FBA) is common in children [1]. Insufficient chewing due to incomplete tooth growth, laughing and running while eating, an underdeveloped swallowing mechanism, curiosity, and carelessness are common causes of FBA in children [2].

The symptoms of FBA depend on both the size

of the object and the severity of obstruction. If the foreign body causes partial or complete obstruction, it can lead to stridor, choking, or asphyxia [3]. FBA may be asymptomatic in some children, while others might experience shortness of breath and coughing [1]. Some cases may develop complications such as aerodermectasia, pneumonia, atelectasis, pneumonectasis, pneumothorax, pneumomediastinum, pulmonary abscess, and hemothorax [4].

*** Corresponding Author:****Aliakbar Keykha**

Address: Community Nursing Research Center, Zahedan University of Medical Sciences, Zahedan, Iran. AND Department of Medical-Surgical Nursing, School of Nursing and Midwifery, Zahedan University of Medical Sciences, Zahedan, Iran.

E-mail: aliakbar.keykha@gmail.com



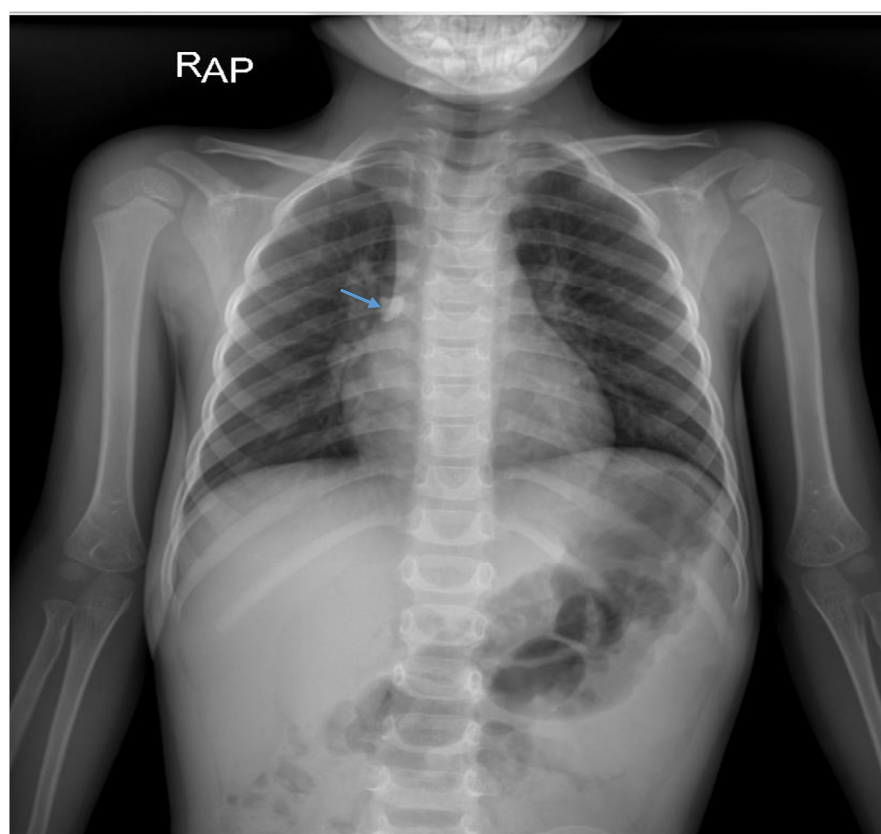


Fig. 1. Chest X-ray reveals a small, high-density opacity at the right bronchus, consistent with FBA (blue arrow).

Pneumothorax may occur simultaneously with FBA; however, pneumothorax and pneumomediastinum may also develop several days after FBA [5]. Bronchoscopic foreign body removal from the trachea or bronchi carries a risk of iatrogenic pneumothorax [6]. Positive pressure ventilation increases the risk of pneumothorax following FBA [7,8].

We report a case of FBA in a child and review the literature regarding its clinical manifestations, treatment, and complications.

Case Presentation

The patient was a 5-year-old Iranian boy of Baluch ethnicity who held a stone in his mouth and accidentally aspirated it into his trachea while playing. His parents took him to Razi Hospital in Saravan, located in Sistan and Baluchestan Province, Iran. At the hospital, a chest X-ray was performed, revealing a stone lodged at the beginning of the right bronchus [Figure 1].

Since the patient did not exhibit shortness of breath or decreased arterial blood oxygen saturation and the hospital lacked an otolaryngologist, he was

transferred to Khatam Al-Anbia Hospital in Zahedan, Iran, for hospitalization and bronchoscopy.

The patient was conscious during the clinical examination and had no respiratory distress. On lung auscultation, a localized wheeze was audible. His blood pressure was 105/57 mmHg, respiratory rate was 28 bpm, heart rate was 118 bpm, temperature was 37 C°, and oxygen saturation was 99%.

He had no known medical history or medication use.

Preoperative tests were as follows: WBC= $12/5 \times 10^3$ /mm, RBC= 5/1 mil/mm, HB= 9/3g/dl, HCT= 31/4%, PLT= 377×1000 , PT= 13/sec, PTT= 28/sec, INR= 1, BS= 89 mg/dl, BUN= 16 mg/dl, CR= 0/7 mg/dl, K= 4/5 meq/l, Na= 142 meq/l, ABG (PH= 7/42, PaCO₂= 34/4, HCO₃= 22/2, BE= -1/4, PaO₂= 85, O₂Sat= 99/5).

Ceftriaxone 500 mg BD and dexamethasone 4 mg TDS were administered to reduce inflammation and prevent pneumonia before the patient was transferred to the operating room for bronchoscopy.

After anesthesia induction in the OR, rigid bronchoscopy revealed a stone in the right bronchus.

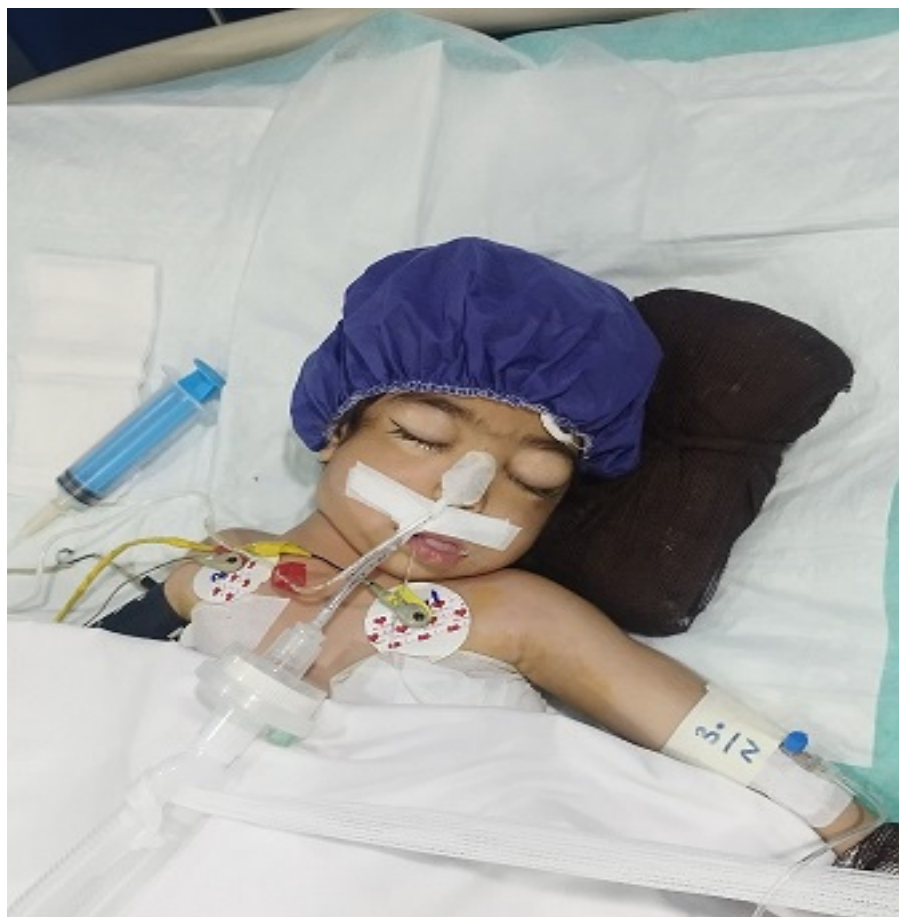

Fig. 2. Photograph of a patient with severe preorbital, facial, neck, and chest SCE after extubation.

However, due to the stone's size and shape, each time the otolaryngologist attempted to grasp it with forceps, it slipped out of the Break of the forceps. Since the hospital did not have a retrieval basket for stone removal, no further attempts were made to prevent bronchial damage. As a result, the patient was transferred to a well-equipped center with appropriate bronchoscopy equipment for stone extraction by an otolaryngologist.

The patient was transferred to the intensive care unit with an endotracheal tube and placed on mechanical ventilation with mode AC/VC+ (PRVC) and the following specifications.

TV= 150 CC, RR= 25, Ti= 0/8, PEEP= 3 and FIO₂= 100-40%

Due to an increased risk of aspiration during bronchoscopy and the need for anaerobic coverage, the patient's medication regimen was expanded to include clindamycin 100 mg BD, N-acetylcysteine 1 g BD, and pantoprazole 10 mg BD, in addition to ceftriaxone and dexamethasone.

Mechanical ventilation was continued for 24 hours to assess possible injuries during bronchoscopy. To prevent ventilator dyssynchrony, sedation with fentanyl (10 micrograms) and midazolam (1 mg/hour) was infused. Another chest X-ray was performed after 24 hours, indicating no abnormalities other than the presence of a foreign body.

Since pneumothorax and hemothorax had been ruled out, sedation was discontinued to prepare the patient for extubation and subsequent transfer to another provincial center, reducing the risk associated with transportation. After four hours, the patient became fully conscious and was first placed on spontaneous mode with 5 cmH₂O PSV and 3 cmH₂O PEEP. Once we ensured adequate respiratory function, a spontaneous breathing trial (SBT) was conducted for 30 minutes using a T-piece. Given the patient's appropriate respiratory rate and volume, absence of respiratory distress, stable Spo₂ levels, and normal vital signs, he was successfully extubated.

Immediately after extubation, the patient developed severe subcutaneous emphysema (SCE) in the head

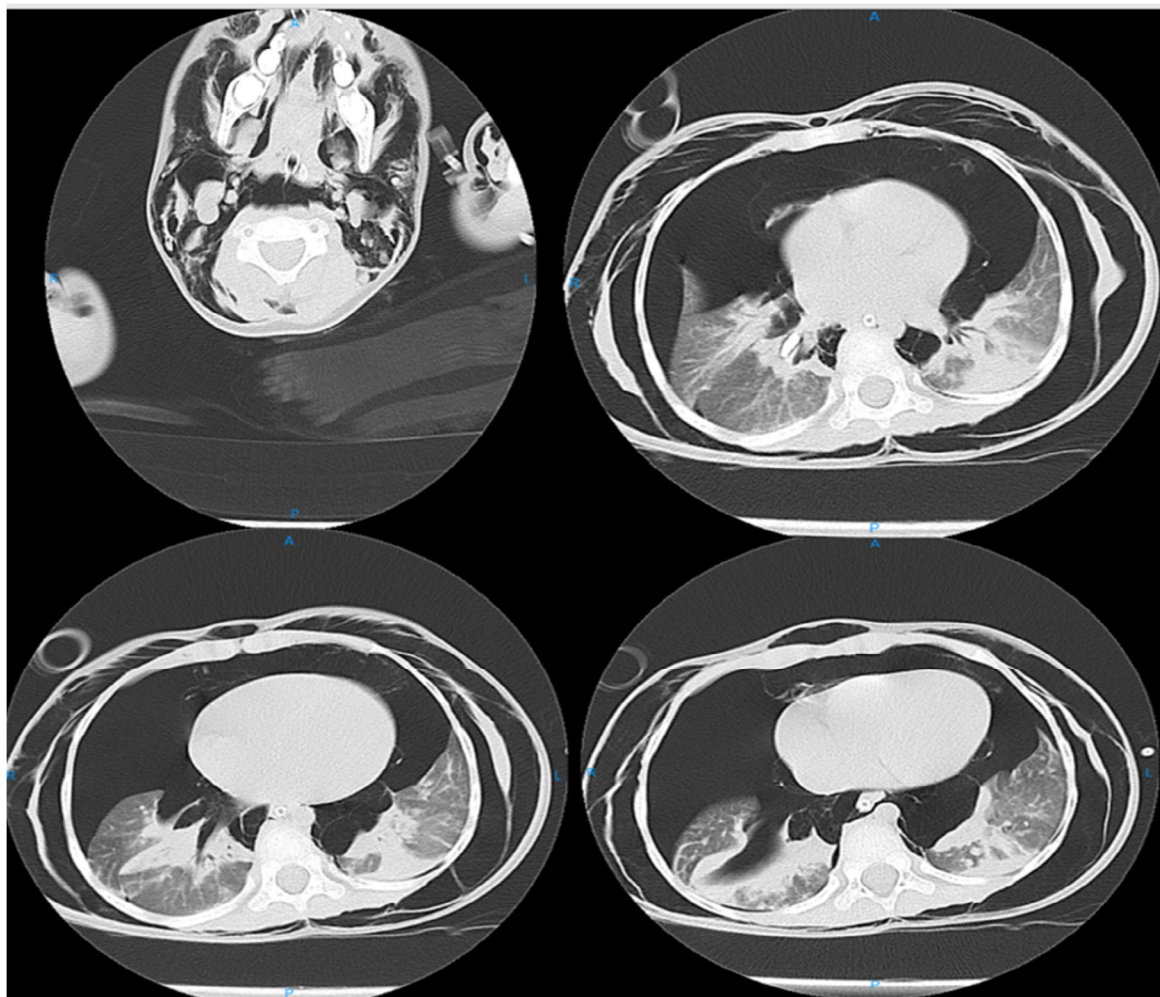


Fig. 3. A chest CT showed extensive SCE, severe bilateral pneumothorax, pneumomediastinum with bilateral lung collapse, and ground glass opacities in each lobe related to aspiration pneumonia, foreign body in the right bronchus along with a defect in the posteromedial wall of the right bronchus.

and neck [Figure 2]. Suspecting tracheal injury during bronchoscopy, we hypothesized that while the endotracheal tube was in place, its inflatable cuff had prevented air leakage from the damaged area. Consequently, the patient was reintubated and placed on mechanical ventilation using the previous mode.

We immediately performed a chest CT scan to assess possible injuries. A chest CT showed extensive subcutaneous emphysema in the head, neck, and thorax. There was severe bilateral pneumothorax, pneumomediastinum with bilateral lung collapse, and evidence of ground glass opacities in each lobe. Also, a hyperdense area (foreign body) measuring $5 \times 7 \times 11$ mm was evident in the right bronchus, along with a defect in the posteromedial wall adjacent to the foreign body. Severe swelling was also visible around the larynx and nasopharynx (Figure 3).

After a definitive diagnosis confirmed that the

rupture of the right bronchus occurred due to the displacement of a foreign body, an urgent surgical consultation was conducted for chest tube placement. The surgeon placed chest tubes on both sides of the patient's chest.

The patient underwent mechanical ventilation for four days to stabilize his respiratory and hemodynamic conditions. A follow-up chest CT was then performed, which showed a significant reduction in pneumothorax, pneumomediastinum, and subcutaneous emphysema (SCE) [Figure 4].

Due to the improvement in the patient's pulmonary condition and the inability to dispatch him, we decided to remove the foreign body via open surgery. Under general anesthesia, the surgeon made an anterolateral incision in the fourth to fifth intercostal space and successfully removed the stone from the right bronchus.

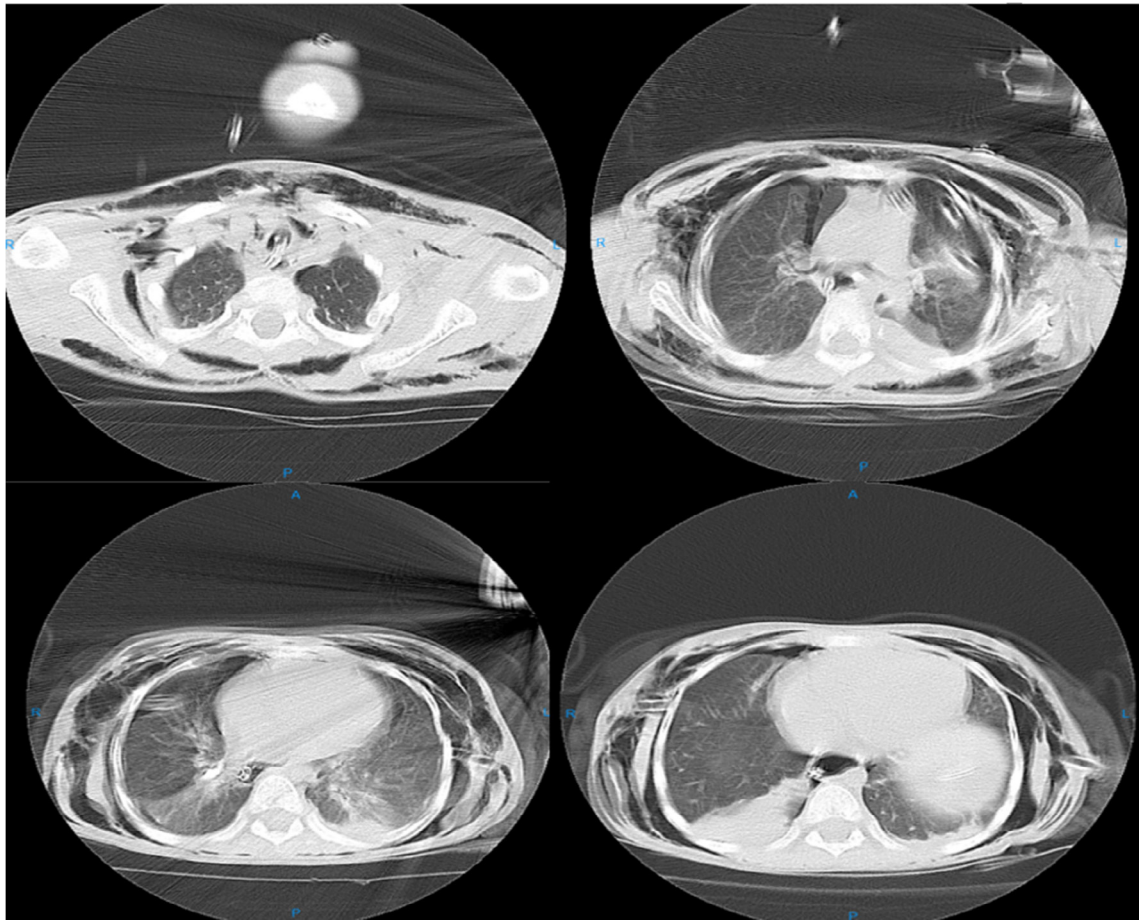


Fig. 4. A chest CT showed a foreign body in the right bronchi that resulted in the collapse of the lower lobe of the right lung. The mild left and medium right pneumothorax are evident. SCE is observed in the neck and thorax. Mild Pneumomediastinum is also visible. Consolidation is evident in both lungs' posterior and inferior areas. The amount of pneumothorax, Pneumomediastinum, and emphysema significantly decreased compared to the previous CT (Figure 3).

After five days of drug treatment, the patient was extubated due to improved clinical status, including reduced emphysema, normal laboratory findings, and no pneumothorax on chest X-ray. The chest tubes were removed the following day.

The patient remained in the ICU for two additional days before being transferred to the surgical ward due to the resolution of pulmonary infection symptoms and overall good condition.

Discussion

FBA accounts for 7% of childhood deaths [9]. Diagnosing FBA in children requires strong clinical acumen, as it is challenging to identify without clear signs such as dyspnea and stridor. Patients with FBA may present with refractory otitis media, pneumonia, or asthma. Pneumothorax is a rare complication of FBA [10].

The pathophysiology of pneumothorax in FBA involves either abrasion or tearing of the bronchial wall or bronchial obstruction creating a ball-valve effect [11]. Pneumothorax caused by barotrauma or airway manipulation is associated with poor outcomes [12]. Foreign body removal requires careful technique to prevent irreversible iatrogenic lung injury. Hospitals must have readily available rigid and flexible bronchoscopes, forceps, and retrieval baskets for airway foreign body removal [13].

Various forceps are available for foreign body extraction. Toothed forceps (rat-tooth, shark-tooth, alligator) are effective for grasping hard objects like coins or plastic, whereas friable objects like food should be avoided to prevent fragmentation [3,14,15]. Retrieval baskets are particularly effective for extracting large, irregular airway foreign objects, outperforming forceps, especially when using flexible bronchoscopy, with minimal complications

[3,14,16,17]. Examples of retrieval baskets include mini-grasping baskets, grasping baskets, zero-tip airway retrieval baskets, and fishnet baskets [12].

There is no consensus on whether rigid or flexible bronchoscopy is preferred for foreign body removal in children and adults [3,18]. However, flexible bronchoscopy may result in fewer complications [3,19]. A case report documented the successful removal of three large metal objects using flexible bronchoscopy after multiple attempts, without complications. In contrast, minimal effort to remove the object in this case led to severe pneumothorax [19].

The risk of iatrogenic pneumothorax is higher in children than adults during invasive procedures [20-22].

Iatrogenic pneumothorax can result from laryngeal trauma, endotracheal tube (ETT) cuff issues, intubation/extubation events, positive-pressure ventilation, or central line placement [22,23]. In the present case, the pneumothorax likely resulted from bronchial perforation during foreign body removal. If solely due to this, its symptoms should have occurred during positive-pressure ventilation, as the risk of pneumothorax is higher when the patient is on positive-pressure ventilation [7,24]. However, in this case, pneumothorax developed post-extubation. Increased respiratory effort and lung movement causing foreign body displacement may have contributed to bronchial perforation and pneumothorax.

A similar case involved a 2-year-old girl with cough and wheezing who developed right-sided facial emphysema while on oxygen. Crying during an IV line change worsened the emphysema, spreading it to the head, face, and chest. Bronchoscopy revealed a foreign body in the right bronchus; chest tube placement improved her condition, and she was extubated the next day [25].

In children with unexplained subcutaneous emphysema or pneumomediastinum, foreign body aspiration (FBA) should be suspected. Management includes immediate airway assessment, foreign body removal, chest tube placement (if required), and supportive care [25,26]. Antibiotics may be necessary for respiratory infections post-aspiration, though not all cases of FBA cause infection [15].

Post-FBA airway infection data remain limited, but oropharyngeal flora aspiration is common. Antibiotics should target oropharyngeal flora, including *Streptococcus pneumoniae*, *Haemophilus influenzae*,

and *Moraxella catarrhalis*, while considering secondary infections [27]. Aspiration pneumonia in older adults with poor hygiene often involves oropharyngeal flora, including *S. pneumoniae*, *H. influenzae*, *Staphylococcus aureus*, anaerobes, Gram-negative bacilli, and *Pseudomonas aeruginosa*. Therefore, treating pneumonia with broad-spectrum cephalosporins and clindamycin may be sufficient [28].

Conclusion

Pneumothorax after foreign body aspiration (FBA) can present with insidious and unpredictable symptoms. Therefore, FBA should be considered in any child presenting with dyspnea, abnormal breath sounds, subcutaneous emphysema, or refractory pulmonary infections.

Abbreviations

- **SCE** = Subcutaneous Emphysema
- **FBA** = Foreign Body Aspiration
- **BD** = Twice daily
- **TDS** = Three times daily
- **PSV** = Pressure Support Ventilation
- **PEEP** = Positive End-Expiratory Pressure
- **SBT** = Spontaneous Breathing Trial
- **ICU** = Intensive Care Unit
- **AC/VC+ (PRVC)** = Assist-Control/Volume Control+ (Pressure-Regulated Volume Control)
- **RR** = Respiratory Rate
- **TV** = Tidal Volume
- **Ti** = Time Inspiration

Acknowledgments

The authors thank the otolaryngology, surgery, and radiology teams for their contributions to the patient's treatment and for providing essential information.

Ethical Considerations

Ethics approval

The study protocol was approved by the ethics committee of Zahedan University of Medical Sciences (ethical code: IR.ZAUMS.REC.1403.408).

Funding

The authors did not receive any funding for this work.

Conflict of Interests

The authors declare that they have no competing interests.

References

- [1] Favre NM, Powers KF, Viola FC, Carr MM. Foreign body aspiration complicated by pneumothorax in children: HCUP-KID perspective. *Ann Otol Rhinol Laryngol*. 2023;132(10):1222-7. <https://doi.org/10.1177/00034894221140775>
- [2] Mun IK, Ju YR, Lee SJ, Woo SH. A case of bilateral tension pneumothorax after the successful CO₂ laser-assisted removal of a bronchial foreign body in a child. *Med Lasers*. 2020;9(1):65-70. <https://doi.org/10.25289/ML.2020.9.1.65>
- [3] Shostak E. Foreign body removal in children and adults: review of available techniques and emerging technologies. *AME Med J*. 2018;3:75. <https://doi.org/10.21037/amj.2018.07.02>
- [4] Chiu CY, Wong KS, Lai SH, Hsia SH, Wu CT. Factors predicting early diagnosis of foreign body aspiration in children. *Pediatr Emerg Care*. 2005;21(3):161-4.
- [5] Skoulakis CE, Doxas PG, Papadakis CE, Proimos E, Christodoulou P, Bizakis JG, et al. Bronchoscopy for foreign body removal in children. A review and analysis of 210 cases. *Int J Pediatr Otorhinolaryngol*. 2000;53(2):143-8. [https://doi.org/10.1016/S0165-5876\(00\)00324-4](https://doi.org/10.1016/S0165-5876(00)00324-4)
- [6] Gómez-Ramos JJ, Marín-Medina A, Castillo-Cobian AA, Felipe-Diego OG. Successful management foreign body aspiration associated with severe respiratory distress and subcutaneous emphysema: case report and literature review. *Medicina (Kaunas)*. 2022;58(3):396. <https://doi.org/10.3390/medicina58030396>
- [7] Rahat Dahmardeh A, Keykha A. Large pneumothorax associated with mechanical ventilation in patients with chronic respiratory disease. *Arch Anesthesiol Crit Care*. 2024;11(2):247-55. <https://doi.org/10.18502/aacc.v11i2.17973>
- [8] Dias RJ, Dave NM, Chaskar VP, Garasia MB. Late onset pneumothorax following bronchoscopic foreign body removal. *J Anaesthesiol Clin Pharmacol*. 2017;33(2):280-2. <https://doi.org/10.4103/0970-9185.173378>
- [9] Tbini M, Hafyene A, Ben Ammar C, El Bessi S, Ben Salah M. Pneumothorax following rigid bronchoscopy for foreign body removal in a child: a case report. *Int J Surg Case Rep*. 2024;124:110361. <https://doi.org/10.1016/j.ijscr.2024.110361>
- [10] Newby MD, Thomas D, Mullett CJ, Vijay C, Carr MM. Foreign body aspiration presenting as pneumothorax in a child. *Cureus*. 2020;12(5):e8161. <https://doi.org/10.7759/cureus.8161>
- [11] Lowe DA, Vasquez R, Maniaci V. Foreign body aspiration in children. *Clin Pediatr Emerg Med*. 2015;16(3):140-8. <https://doi.org/10.1016/j.cpem.2015.07.002>
- [12] Amaniti E, Provitsaki C, Papakonstantinou P, Tagarakis G, Sapalidis K, Dalakakis I, et al. Unexpected tension pneumothorax-hemothorax during induction of general anaesthesia. *Case Rep Anesthesiol*. 2019;2019:5017082. <https://doi.org/10.1155/2019/5017082>
- [13] Okonkwo OC, Simons A, Nichani J. Paediatric airway foreign body - the human factors influencing patient safety in our hospitals. *Int J Pediatr Otorhinolaryngol*. 2016;91:100-4. <https://doi.org/10.1016/j.ijporl.2016.10.016>
- [14] Bajaj D, Sachdeva A, Deepak D. Foreign body aspiration. *J Thorac Dis*. 2020;13(8):5159-75. <https://doi.org/10.21037/jtd.2020.03.94>
- [15] Sarkar A, Murthy V. Foreign body aspiration: a review of current strategies for management. *Shanghai Chest*. 2020;5:38. <https://doi.org/10.21037/shc-20-38>
- [16] Hatziaiorou E, Kirvassilis F, Ntaflos A, Skouras A, Kontzoglou G, Tsanakas J. Foreign body removal by flexible bronchoscopy using retrieval basket in children. *Eur Respir J*. 2020;56(Suppl 64):3512. <https://doi.org/10.1183/13993003.congress-2020.3512>
- [17] Kim K, Lee HJ, Yang EA, Kim HS, Chun YH, Yoon JS, et al. Foreign body removal by flexible bronchoscopy using retrieval basket in children. *Ann Thorac Med*. 2018;13(2):82-5. https://doi.org/10.4103/atm.ATM_337_17
- [18] Nunes Caldeira J, Fernandes L, Rodrigues Sousa S, Martins Y, Barata F. Flexible bronchoscopy as the first-line strategy for extraction of tracheobronchial foreign bodies. *Open Respir Arch*. 2022;4(3):100174. <https://doi.org/10.1016/j.opresp.2022.100174>
- [19] Ramos-Rossy J, Cantres O, Torres A, Casal J, Otero Y, Arzon-Nieves G, et al. Flexible bronchoscopic removal of 3 foreign objects. *Fed Pract*. 2018;35(9):24-6.
- [20] Sedman A, Harris JM 2nd, Schulz K, Schwalenstocker E, Remus D, Scanlon M, et al. Relevance of the Agency for Healthcare Research and Quality Patient Safety Indicators for children's hospitals. *Pediatrics*. 2005;115(1):135-45. <https://doi.org/10.1542/peds.2004-1083>
- [21] Furia S, Breda C. Primary spontaneous pneumothorax in children and adolescents: a systematic review. *Pediatr Med*. 2019;2:1. <https://doi.org/10.21037/pm.2019.04.01>
- [22] da Silva PSL, de Aguiar VE, Fonseca MCM. Iatrogenic pneumothorax in mechanically ventilated children: incidence, risk factors and other outcomes. *Heart Lung*. 2015;44(3):238-42. <https://doi.org/10.1016/j.hrtlng.2015.01.005>
- [23] Kumar S, Kabi A, Bamba C. Post-operative pneumothorax with

- subcutaneous emphysema in a pre-eclamptic patient. *Indian J Anaesth.* 2016;60(7):527-8. <https://doi.org/10.4103/0019-5049.186024>
- [24] Hsu CW, Sun SF. Iatrogenic pneumothorax related to mechanical ventilation. *World J Crit Care Med.* 2014;3(1):8-14. <https://doi.org/10.5492/wjccm.v3.i1.8>
- [25] Hu M, Green R, Gungor A. Pneumomediastinum and subcutaneous emphysema from bronchial foreign body aspiration. *Am J Otolaryngol.* 2013;34(1):85-8. <https://doi.org/10.1016/j.amjoto.2012.09.005>
- [26] Huang Y, Huang H, Li Q, Browning RF, Parrish S, Turner JF Jr, et al. Approach of the treatment for pneumothorax. *J Thorac Dis.* 2014;6(Suppl 4):S416-20.
- [27] Gruber M, van Der Meer G, Ling B, Barber C, Mills N, Neeff M, et al. The bacterial species associated with aspirated foreign bodies in children. *Auris Nasus Larynx.* 2018;45(3):598-602. <https://doi.org/10.1016/j.anl.2017.07.014>
- [28] Bai AD, Srivastava S, Digby GC, Girard V, Razak F, Verma AA. Anaerobic antibiotic coverage in aspiration pneumonia and the associated benefits and harms: a retrospective cohort study. *Chest.* 2024;166(1):39-48. <https://doi.org/10.1016/j.chest.2024.02.025>