



Double Aortic Arch Anomaly Mimicking Asthma and Laryngomalacia: Two Case Reports

Mohammad Tajdini¹, Mansoureh Shariat¹, Mohammadreza Mirzaaghayan¹, Sara Memarian¹, Parisa Rahmani¹, Mohammadtaghi Majoon¹

1- Department of Pediatrics, School of Medicine, Children's Medical Center, Tehran University of Medical Sciences, Tehran, Iran

Received: 25 December 2016

Revised: 20 January 2017

Accepted: 18 February 2017

ARTICLE INFO

Corresponding author:
Mohammadtaghi Majoon

Email:
107majnoon@gmail.com

Keywords:
Aortic arch;
Asthma;
Laryngomalacia;
Respiratory distress

ABSTRACT

This report describes two patients (a 7-year-old boy and a 3-month-old boy) who have had chronic and recurrent respiratory distress and wheezing episodes since infancy. The elder one had been treated for hyper-reactive airway disease and asthma, and the other had been diagnosed with laryngomalacia. The problems had been associated with cyanosis and did not improve with routine treatment; therefore, we considered other underlying diseases, such as cardiovascular problems. The diagnostic workups revealed the “double aortic arch” which had not been diagnosed previously.

Citation: Tajdini M, Shariat M, Mirzaaghayan M, Memarian S, Rahmani P, Majoon M. **Double Aortic Arch Anomaly Mimicking Asthma and Laryngomalacia: Two Case Reports.** Case Rep Clin Pract 2017; 2(1): 16-20.

Introduction

Congenital anomalies of the aortic arch and its clinical correlation to swallowing difficulty have been mentioned since 18th century. During the 1930s, barium esophagography was the main diagnostic procedure for arch abnormalities, and it was in the 1960s and 1970s that angiography became the gold standard for this disorder. A vascular ring is an abnormality of an aortic arch which encircles the trachea and esophagus. The

clinical presentation includes respiratory problems such as stridor, pneumonia, cough, a posture of hyperextension of the neck, and less commonly reflex apnea associated with feeding. The typical medical history is that an infant, 1-3 months old, having noisy breathing since birth who will have respiratory distress by upper respiratory infection or less commonly a toddler with swallowing difficulty or chock with feeding. Some patients may have wheezing which can be mistaken with asthma. These

children usually have normal oxygen saturation and sometimes in severe cases elevated PCO₂, however patients with bronchiolar obstruction usually are hypoxemic with normal values of PCO₂ (1).

Case Report

Case 1: A 7-year-old boy was brought to the emergency department of our hospital with the chief complaint of dyspnea, wheezing, and productive cough. The current problem had started 1 week ago with fever and dry cough, following an upper viral respiratory disease, and the signs and symptoms did not improve by antihistamine, salbutamol, corticosteroids, and antibiotics. The chest plain radiography showed hyperinflation and peri-bronchial thickening (Figure 1).

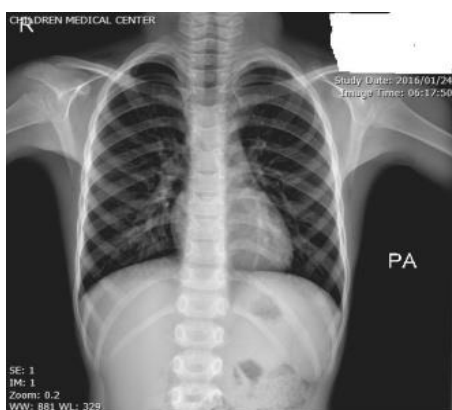


Figure 1. Hyperinflation and peri-bronchial thickening in both lungs

On the first clinical examination in the emergency ward, he had dyspnea, with intercostal respiratory muscle retraction, tachypnea, and was dehydrated and cyanotic. His weight was 19 kg (under the 10th percentile of weight for age). His vital signs were as follows: respiratory rate: 35 breaths per minute, heart rate: 104 beats per minute, temperature: 39 °C, and blood pressure: 90/65 mmHg. On auscultation of the lungs, wheezing and crackles were heard on all parts of both lungs, no murmurs on heart auscultation were audible. On throat examination, post-nasal drip was seen. Abdominal and other examinations were normal.

His past medical history was significant for having episodic choking attacks during feeding from 2 months of age and her mother had to feed him in little amounts and more frequently. The problem got worse since 6 months of age, especially after getting cold and viral respiratory diseases. He has always had coughing and noisy breathing. He had been hospitalized 2 times for respiratory distress in 11 and 18 months of age with the diagnosis of “hyper-reactive airway disease” and had been treated for asthma (salbutamol and fluticasone metered dose inhaler (MDI) and occasional systemic prednisolone).

In the emergency ward, the first treatment administered was nebulized bronchodilators, systemic antibiotics, and corticosteroids. However, his condition got better gradually, but the respiratory distress was not resolved completely and his pulse oximetry remained about 85% in the ambient air.

Due to the refractory nature of the disease and the presence of cyanosis, the emergency doctors considered other underlying diseases and performed more workups. A spirometry showed a mixed obstructive and restrictive pattern (there was flattening in the inspiratory and expiratory flow-volume loop). Immunodeficiency diseases and cystic fibrosis (by sweat test) were also evaluated and ruled out.

As the treatment of the suspected asthma was not satisfying and cyanosis persisted, an echocardiography was performed and an abnormal aortic arch was reported, and the computerized angiography revealed “vascular ring and double aortic arch (Figure 2).”

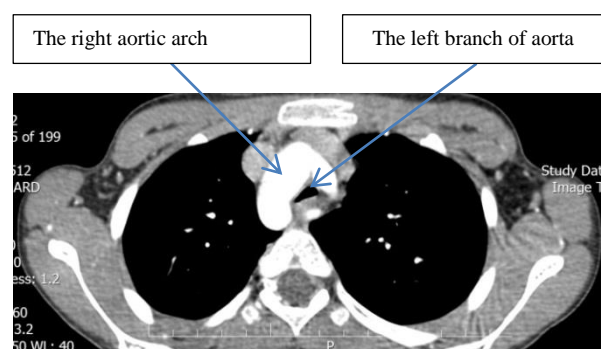


Figure 2. The right and left branches of the aorta that encircle and compress the esophagus

The bronchoscopic examination showed the pressure effect of the vascular ring on the inferior third of the trachea which tightened the entrance of the right middle lobe (Figure 3).

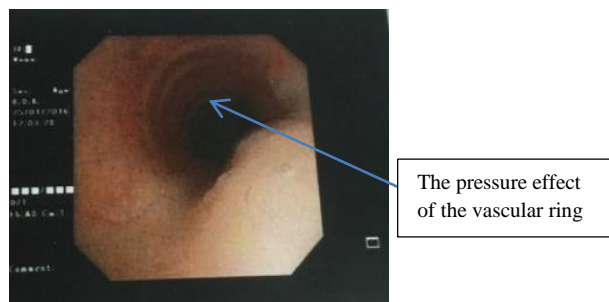


Figure 3. The pressure effect of the vascular ring on the inferior third of the trachea

The FISH study for DiGeorge syndrome revealed “No deletion of chromosome 22q11.” He was referred to a cardiac surgeon and the lesion was corrected by surgery. On the follow-up visits till 1 year after the surgery, he was in a good condition without any respiratory symptoms.

Case 2: A 3-month-old boy was referred to our hospital because of respiratory distress and tachypnea. On physical examination, his weight was 6700 g and he had fever (axillary temperature = 38 °C), subcostal retraction and tachypnea (respiratory rate = 58 breaths/minute), and the heart rate was 130 beats/minute. He had fine crackles on both lungs. Other examinations were not remarkable. In the past medical history, it was found that he always had noisy breathing from birth time which became aggravated while being fed. Her mother told us that after and during feeding he occasionally had blue lips for < 1 minute. He had been diagnosed to have laryngomalacia. He had been hospitalized 3 times for aspiration pneumonia.

Having the history of aspiration, a barium esophagogram was performed which revealed a fixed pressure point on esophagus (Figure 4). Considering the episodes of cyanosis and aspiration during feeding and the result of barium swallow examination, a computed tomography (CT) angiography was recommended by the cardiologist consultant

which revealed vascular ring compressing esophagus and trachea and right aortic arch with retro-esophageal component (Figure 5). He was referred to cardiac surgery department for further treatment.

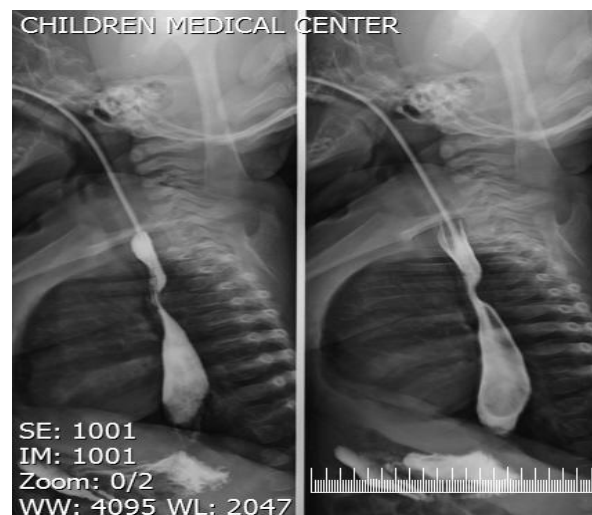


Figure 4. Barium esophagogram showing a fixed pressure point on esophagus (arrows)

Discussion

The term “vascular ring” was mentioned by Gross in 1945 for the first time in “New England Journal of Medicine” (2). Congenital abnormalities of the aortic arch and the major branches lead to composition of vascular rings around the airway and esophagus and putting pressure on these organs (3).

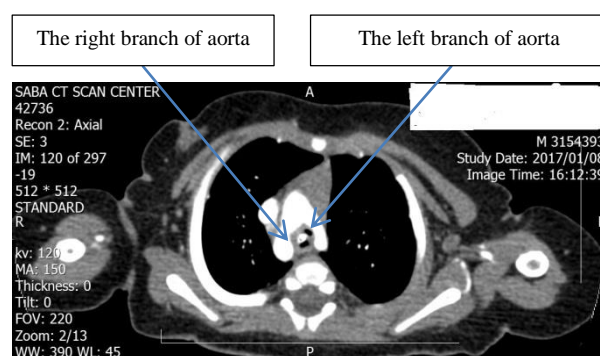


Figure 5. Computed tomography angiography showing vascular ring compressing esophagus and trachea and right aortic arch with retro-esophageal component

In “double aortic arch,” the ascending aorta bifurcates and ends to right- and left-

sided arches which surround the esophagus and trachea and then join together to compose the descending aorta (4). The right arch is often larger than the left arch (2).

Vascular ring is among the differential diagnoses of chronic cough. Other possible causes of chronic cough include gastroesophageal reflux disease, cystic fibrosis, inhaled foreign body, infection, tracheomalacia, immunodeficiency, vocal cord dysfunction, bronchiectasis, chronic sinusitis with or without postnasal drip, allergic disease, and branchial cleft cysts (2).

The clinical signs and symptoms of vascular ring in children vary from a completely asymptomatic patient to severe respiratory distress in a neonate. The most prevalent presentations in children are nonspecific and include choking, vomiting, dysphagia, cough, stridor, wheezing, and episodes of upper respiratory tract infection (2). The clinical presentation of double aortic arch most often occurs in infancy. External pressure on the airway by vascular ring causes respiratory and feeding problems (5). Feeding problems such as slow feeding, difficult swallowing, and hyperextension of head during eating may occur later in life, since these problems typically present when solid foods are introduced (6). Chronic wheezing is aggravated by eating, crying, and neck flexion, while neck extension alleviates the noisy breathing (3). Severe problems such as apnea and cyanosis may also occur (7).

The plain chest X-ray is not often useful, and echocardiography with CT or magnetic resonance imaging is the diagnostic imaging method (3). Many patients with vascular ring have gastrointestinal complaints and maybe diagnosed by barium esophagography (2). Some studies suggest the association between vascular ring and deletion in band 22q11 (8).

In the presence of tracheal compression, surgery is advised (3). Usually, patients have a good prognosis after the surgery, especially for the isolated vascular ring. In case of other cardiac comorbidities, the prognosis is dependent on the coexisting problem.

Persistence of the respiratory problems is the most common post-surgical complaint. Tracheomalacia after the surgery is most prevalent in the very young patients. Chylothorax and recurrent laryngeal and phrenic nerve injuries are also among the possible complications of the surgery (2).

Patients with vascular rings usually present with nonspecific and vague complaints and can mimic asthma or hyper-reactive airway disease. Physicians should consider vascular rings in the list of differential diagnosis of chronic cough, respiratory problems, and refractory asthma to prevent the unnecessary interventions and procedures and delaying the diagnosis.

Conflict of Interests

Authors have no conflict of interests.

Acknowledgments

We would like to thank all the staff of the Children's Medical Center for their valuable efforts in managing and helping the sick children and our patient.

References

1. Weinberg Paul M, Shobha N, Rogers Lindsay S. Aortic arch and vascular anomalies. In: Allen HD, Editor. Moss and Adams' heart disease in infants, children, and adolescents: Including the fetus and young adult. 8th ed. Philadelphia, PA: Lippincott Williams & Wilkins; 2013. p. 758-98.
2. Savoy ML, Crawford-Faucher AD. A 3-month-old girl with a persistent cough and respiratory distress [Online]. [cited 2005]; Available from: URL: <https://pdfs.semanticscholar.org/5430/cf48f17a2cefd5da590e47c0840734d8a28c.pdf>
3. Bernstein D. Other congenital heart and vascular malformations. In: Kliegman RM, Stanton BM, Geme J, Schor NF, Editors. Nelson textbook of pediatrics E-Book. 20th ed. Philadelphia, PA: Elsevier Health Sciences; 2016. p. 2235-8.
4. Juraszek AL, Guleserian KJ. Common aortic arch anomalies: Diagnosis and management. *Curr Treat Options Cardiovasc Med* 2006; 8(5): 414-8.
5. Uchida DA. Late presentation of double aortic

- arch in school-age children presumed to have asthma: The benefits of spirometry and examination of the flow-volume curve. *Respir Care* 2009; 54(10): 1402-4.
6. Etesami M, Ashwath R, Kanne J, Gilkeson RC, Rajiah P. Computed tomography in the evaluation of vascular rings and slings. *Insights Imaging* 2014; 5(4): 507-21.
 7. Frederic Moes CA, Freedom RM. Rare types of aortic arch anomalies. *Pediatr Cardiol* 1993; 14(2): 93-101.
 8. Bakker DA, Berger RM, Witsenburg M, Bogers AJ. Vascular rings: A rare cause of common respiratory symptoms. *Acta Paediatr* 1999; 88(9): 947-52.