

Malignancy in Left-Sided Gall Bladder: A Case Report



Dipak Dhanajirao Thorat¹, Somanath Malage², Rahul R³, Ashish Singh^{*4}

Sanjay Gandhi Postgraduate Institute of Medical Sciences, Lucknow, Uttar Pradesh, India.

Use your device to scan
and read the article online



Citation Dhanajirao Thorat D, Malage S, R Rahul, Singh A. Malignancy in Left-Sided Gall Bladder: A Case Report. Case Reports in Clinical Practice. 2025; 10(6): 289-292. DOI:10.18502/crcp.v10i6.21617

Running Title Malignancy in Left-Sided Gall Bladder



Article info:

Received: November 22, 2025

Revised: December 16, 2025

Accepted: December 20, 2025

Keywords:

Left-sided gallbladder;
Gallbladder carcinoma;
Congenital biliary anomaly;
Extended cholecystectomy;
Hepatobiliary malignancy

ABSTRACT

Left-sided gallbladder (LSGB) is an exceedingly rare congenital anomaly; the occurrence of malignancy in a left-sided gallbladder is even rarer, making this case particularly unique. To the best of our knowledge, this is the first reported case of malignancy in an LSGB.

A 65-year-old male presented with a two-month history of right upper quadrant abdominal pain with no history of jaundice or weight loss. Ultrasound of the abdomen revealed a suspicious mass in the gallbladder. CT scan of the abdomen confirmed an LSGB with diffuse irregular enhancing thickening of the gallbladder walls in the region of the body and fundus, infiltrating segment III of the liver and forming a moderate-sized intrahepatic soft tissue lesion measuring 43*33 mm, with TNM stage T3N0. The patient's blood investigations were within normal limits, with CA 19.9 levels at 70 U/ml. The patient underwent staging laparoscopy and open extended cholecystectomy, which involved resecting the gallbladder along with a 3 cm wedge of liver (segments III, IVb) with clear gross margins, along with lymphadenectomy of stations 8, 9, 12, 13, and the right side of station 9. The patient had an uneventful postoperative recovery and was discharged on postoperative day 4. Histopathological examination revealed a pT3N0 (0/16) poorly differentiated adenocarcinoma with clear margins. The patient received adjuvant chemotherapy with 6 cycles of capecitabine. At one-year follow-up, the patient was doing well with no evidence of recurrence.

In conclusion, malignancy in a left-sided gallbladder is a very rare occurrence, this being the first case report of such a condition. Successful management requires a thorough knowledge of biliary and hepatic anatomy, good preoperative imaging work-up, and a tailored surgical approach to achieve optimal outcomes.

Introduction

Left-sided gallbladder (LSGB), first described by Hochstetter in 1856, is a rare congenital anomaly in which the gallbladder is located on the left side of the round ligament [1]. The reported incidence of LSGB is approximately 0.3–1.2% in the general population [2]. The occurrence of malignancy in a left-sided gallbladder is even rarer, making this case report

particularly unique. To the best of our knowledge, this is the first reported case of malignancy in an LSGB. This case report aims to discuss the challenges encountered during surgical intervention and the management strategy adopted.

Case report

A 65-year-old male presented with a two-month history of mild to moderate right upper quadrant

* Corresponding Author:

Ashish Singh

Address: Sanjay Gandhi Postgraduate Institute of Medical Sciences, Lucknow, Uttar Pradesh, India.

E-mail: singhashishald@gmail.com

abdominal pain with no history of jaundice or weight loss. On examination, the patient had mild tenderness in the right upper quadrant without palpable mass or organomegaly. Initial evaluation with ultrasound revealed mild hepatomegaly and a suspicious mass in the gallbladder. CT triple phase abdomen confirmed a diffuse irregular enhancing thickening of gall bladder wall in the region of body and fundus infiltrating segment III of liver forming intrahepatic soft tissue lesion of size 43*33mm. Right posterior portal vein was the first branch of the main portal vein and the segment 4 branches of left portal vein was seen extending into segment 8 of liver. A prominent segment 4 artery arising from left hepatic artery was

also noted (Figures 1 and 2). The lesion was resectable with no evidence of distant metastasis.

Patient's blood investigations were within normal limits, with CA 19.9 levels being 70 U/ml. The patient underwent staging laparoscopy, which confirmed the presence of an LSGB extending to the left of the falciform ligament attached to segment III, with no evidence of peritoneal or distant metastasis (Figure 3).

An open extended cholecystectomy was performed, which involved resecting the gallbladder along with a 3 cm wedge of liver (segments III, IVb) along with

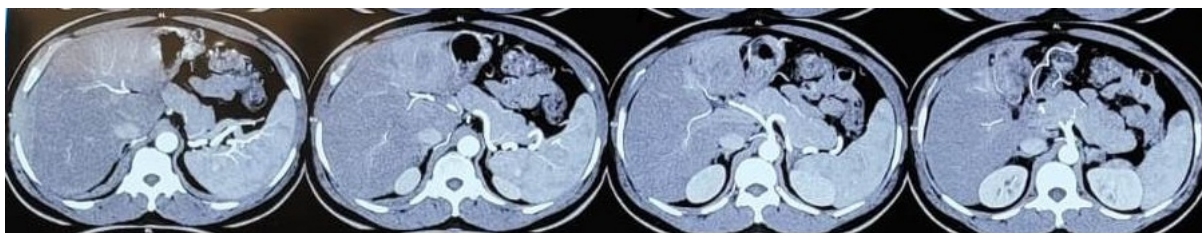


Fig. 1. From RT to LT: Proper Hepatic Artery dividing into right & left hepatic artery (RHA, LHA) and artery to segment 4.

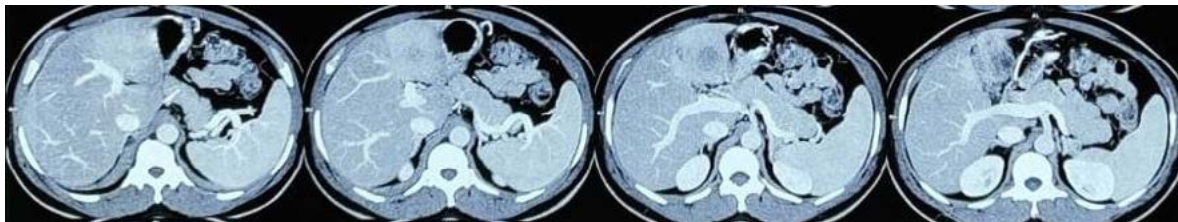


Fig. 2. From RT to LT: relation of left portal vein to lesion, early division of RPPV, lesion is located left to LPV. Diffuse irregular enhancing thickening of gall bladder in the region of body and fundus infiltrating segment III of liver forming moderate sized intrahepatic soft tissue lesion of size 43*33mm.

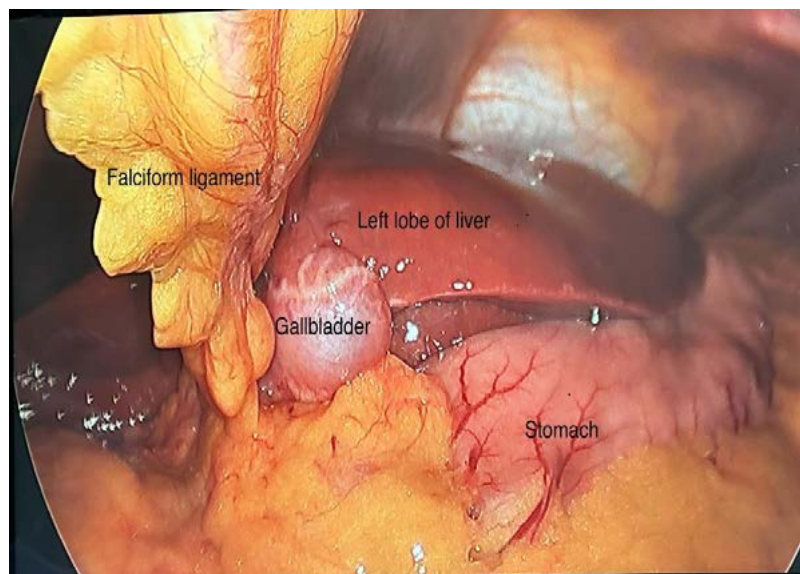


Fig. 3. On staging laparoscopy gall bladder is located to the left of falciform ligament

lymphadenectomy of stations 8, 12, 13 and the right side of station 9. Cystic duct was joining at the right side of the common bile duct and cystic artery was arising from RHA. Right anterior portal vein was opening into left portal vein (LPV) and right posterior portal vein (RPPV) joining separately lower down, forming a Type IIIB anatomy by Choi classification.

This aberrant anatomy increased the difficulty in achieving the wider margins of liver resection due to the proximity of portal pedicles to the resection margins. Despite this, with careful pre-operative planning and meticulous dissection a negative resection margin was achieved by dissecting just over left and right anterior sector portal pedicles.

The patient had an uneventful postoperative recovery and was discharged on postoperative day 4. Histopathological examination revealed a poorly differentiated adenocarcinoma, pathological stage T3N0 (0/16), with R0 resection. The patient received adjuvant chemotherapy with 6 cycles of capecitabine, which he tolerated well. The patient was followed at 3-month intervals with clinical examination, CA 19-9, and ultrasound of the abdomen. At one-year follow-up, the patient was doing well with no evidence of recurrence, with a CA 19-9 level of 13 U/ml.

Discussion

Until now 150 cases of LSGB have been reported in literature with majority of them being detected incidentally during surgery. LSGB should be suspected when ultrasound or CT scan shows small segment 4, lack of umbilical portion of left lateral portal vein and a club shaped right anterior portal vein [3].

Among the three recognized variants of LSGB a true LSGB is defined when the gall bladder is located to the left of the round ligament without situs inversus. LSGB is usually associated with the anomalies of intrahepatic portal venous branching, extra and intrahepatic biliary ductal anomalies, segment 4 atrophy, gall bladder duplication and congenital liver cysts. Portal venous anomalies include an early branching of right posterior portal vein and the crossing over of segment 4 branches of left portal vein into segment 8. Hepatic arterial anomalies include dual cystic arteries and accessory right or left hepatic arteries [4]. Biliary ductal anomalies include an abnormal insertion of cystic duct into the right side of common bile duct (CBD) coursing anteriorly, duplication of bile ducts, infraportal bile duct, hypoplasia of bile duct and an APBDJ (abnormal pancreatobiliary ductal junction) [5]. Symptoms secondary to pathology in LSGB can

still present as right upper quadrant pain as it is noted that the visceral pain fibers does not cross over with the change in position of gall bladder [4].

The challenges encountered during a laparoscopic cholecystectomy in LSGB have been described in literature with respect to the port positions and variations in cystic artery and cystic duct. Almodhaiberi et al and Abe et al. have reported the challenges encountered during hepatectomies who had LSGB. The presence of LSGB in can present as contraindication to donor hepatectomy in liver transplantation. These findings suggest that the preoperative detection of a LSGB mandates the careful study of the associated biliovascular anomalies for the safe conduct of the surgical procedure [6,7]. The presence of malignancy in a LSGB introduces significant surgical challenges due to the altered anatomy and proximity of the tumor to critical structures. The standard procedure for a carcinoma gall bladder in its usual position (T1b and above) is extended cholecystectomy with 2 cm liver wedge of segment 4b, 5 and lymphadenectomy of station 8, 12 and 13 [8]. As the lymphatic and venous drainage of a LSGB is not known decisively management of carcinoma in LSGB requires careful planning to achieve complete tumor removal while preserving vital biliary and vascular structures in the vicinity. In this case, the large tumor's location near the liver hilum and umbilical fissure complicated the surgery. The left portal vein and the right anterior portal vein location near to the malpositioned gall bladder limited the ability to achieve wider resection margins. Intraoperative ultrasound can help assist in identifying the vital structures during wedge resection of segment 3, 4b. We successfully performed an extended cholecystectomy with negative margins.

The lymphatic drainage of carcinoma gall bladder is through three different pathways. The cholecysto-retropancreatic, cholecysto-celiac and cholecysto-mesenteric pathway. The cholecysto-retropancreatic pathway being the predominant route of spread. However the lymphatic spread in a carcinoma of LSGB has not been described [9]. Due to the location of the LSGB it can be suspected that cholecysto-celiac route of spread may be predominant in this scenario. We did a lymphadenectomy of station 9 along with stations 8, 12 and 13.

Given the rarity of malignancy in LSGB, there is limited literature on the optimal surgical approach. Key oncology principles with respect to achieving R0 resection, thorough lymphadenectomy, and minimizing injury to vital structures, remain critical. Postoperative management and follow-up protocols are similar to that for gallbladder carcinoma in the

typical anatomical position. Adjuvant chemotherapy is recommended for advanced disease (T2 and above). Here, the poorly differentiated nature of the adenocarcinoma and the T stage warranted the use of adjuvant chemotherapy with Capecitabine despite no nodal involvement (pT3N0). This case highlights the need for detailed preoperative imaging such as good quality multiphase CT scan and biliary mapping with MRCP, which can pick any associated aberrancy in vascular and biliary system apart from disease staging. Although MRCP was not done pre-operatively in this patient, we did notice the cystic duct insertion on the right of CBD coursing anteriorly.

This case report contributes by being the first case reported on malignancy in LSGB, providing valuable insights into the pre-operative planning and on-table surgical strategy for such a rare condition. Studies exploring the venous and lymphatic drainage of LSGB can be of help in planning the exact extent of liver resection and lymphadenectomy in cases of carcinoma in LSGB.

Author Contributions

Dipak Dhanajirao Thorat (DDT): Conception and design of the study; drafting of the manuscript.

Somanath Malage (SM): Acquisition of data; analysis and interpretation of data.

Rahul R (RR): Analysis and interpretation of data; critical revision of the manuscript for important intellectual content.

Ashish Singh (AS): Conception and design of the study; critical revision of the manuscript for important intellectual content.

All authors reviewed and approved the final version of the manuscript.

Ethical Considerations

Compliance with ethical guidelines

There were no ethical considerations to be considered in this article.

Funding

No funding was received to assist with the preparation of this manuscript.

Conflict of Interests

The authors have no conflict of interest to declare.

References

- [1] Idu M, Jakimowicz J, Iuppa A, Cuschieri A. Hepatobiliary anatomy in patients with transposition of the gallbladder: implications for safe laparoscopic cholecystectomy. *Br J Surg.* 1996 Oct;83(10):1442-3. <https://doi.org/10.1002/bjs.1800831037>
- [2] Deka M, Kalita J. Left-sided gallbladder: a systematic review of literature. *J Hepatobiliary Pancreat Sci.* 2018;25(5):179-86.
- [3] Hsu SL, Chen TY, Huang TL, Sun CK, Concejero AM, Tsang LL, Cheng YF. Left-sided gallbladder: its clinical significance and imaging presentations. *World J Gastroenterol.* 2007 Dec 21;13(47):6404-9. <https://doi.org/10.3748/wjg.v13.i47.6404>
- [4] Lee DH, Kim D, Park YH, Kim JS. Clinical significance and characteristics of left-sided gallbladder: case series study of 10 patients. *Ann Surg Treat Res.* 2019 Dec;97(6):302-8. <https://doi.org/10.4174/ast.2019.97.6.302>
- [5] Nagendram S, Lynes K, Hamada A. A case report on a left sided gallbladder: A rare finding during cholecystectomy. *Int J Surg Case Rep.* 2017 Nov 14;41:398-400. <https://doi.org/10.1016/j.ijscr.2017.11.004>
- [6] Almodhaiberi H, Hwang S, Cho YJ, Kwon Y, Jung BH, Kim MH. Customized left-sided hepatectomy and bile duct resection for perihilar cholangiocarcinoma in a patient with left-sided gallbladder and multiple combined anomalies. *Korean J Hepatobiliary Pancreat Surg.* 2015 Feb;19(1):30-4. <https://doi.org/10.14701/kjhbps.2015.19.1.30>
- [7] Abe T, Kajiyama K, Harimoto N, Gion T, Shirabe K, Nagaie T. Resection of metastatic liver cancer in a patient with a left-sided gallbladder and intrahepatic portal vein and bile duct anomalies: A case report. *Int J Surg Case Rep.* 2012;3(5):147-50. <https://doi.org/10.1016/j.ijscr.2012.01.003>
- [8] Lee SE, Kim KS, Kim WB, Kim IG, Nah YW, Ryu DH, et al. Practical guidelines for the surgical treatment of gallbladder cancer. *J Korean Med Sci.* 2014 Oct;29(10):1333-40. <https://doi.org/10.3346/jkms.2014.29.10.1333>
- [9] Ito M, Mishima Y, Sato T. An anatomical study of the lymphatic drainage of the gallbladder. *Surg Radiol Anat.* 1991;13(2):89-104. <https://doi.org/10.1007/BF01623880>