



## Brachymetatarsia; How Important Can It Be in Adolescence?

Mojgan Mirabdolhagh<sup>1</sup>, Sahar Karimpour Reyhan<sup>2\*</sup>, Mahsa Abbaszadeh<sup>2</sup>

1- Endocrinology and Metabolism Research Center (EMRC), Vali-Asr Hospital, Imam Khomeini Hospital Complex, Tehran University of Medical Sciences, Tehran, Iran

2- Department of Medicine Internal, Imam Khomeini Hospital Complex, Tehran University of Medical Sciences, Tehran, Iran

Received: 29 March 2018

Revised: 18 April 2018

Accepted: 12 May 2018

### ARTICLE INFO

Corresponding author:  
Sahar Karimpour Reyhan

Email:  
[skarimpour@sina.tums](mailto:skarimpour@sina.tums)

Keywords:  
Hypocalcaemia;  
Adolescence;  
Pseudohypoparathyroidism (PHP)

### ABSTRACT

Hypocalcaemia is a dangerous electrolyte imbalance with 18% prevalence in hospital admitted patients. 1 Regulation of calcium level is by 3 main calcium-regulating hormones. These hormones are parathyroid hormone (PTH), vitamin D, and calcitonin; and they act by effecting on the bowel, kidneys, and skeleton. Causes of hypocalcaemia includes vitamin D deficiency, hypoparathyroidism, renal diseases, hypomagnesaemia, hungry bone disease after parathyroidectomy, drugs like calcium chelators, massive blood transfusion, critical illness, parathyroid hormone resistance, vitamin D resistance. Pseudohypoparathyroidism (PHP) refers to a group of metabolic disorders in which resistance to parathyroid hormone leads to hypocalcaemia, hyperphosphatemia, and elevation of serum PTH level in the setting of normal renal function. Herein we report an interesting case of hypocalcaemia who came to the emergency department with suspicion of intracranial hemorrhage and lead to the diagnosis of pseudohypoparathyroidism.

**Citation:** Mirabdolhagh M, Karimpour Reyhan S, Abbaszadeh M. **Brachymetatarsia; How Important Can It Be in Adolescence?** Case Rep Clin Pract 2018; 3(2): 38-41.

### Introduction

Hypocalcaemia is a dangerous electrolyte imbalance with 18% prevalence in hospital admitted patients (1). Regulation of calcium level is by 3 main calcium-regulating hormones- including parathyroid hormone (PTH), vitamin D, and calcitonin effecting on the bowel, kidneys, and

skeleton, respectively (2).

Causes of hypocalcaemia includes vitamin D deficiency, hypoparathyroidism, renal diseases, hypomagnesaemia, hungry bone disease after parathyroidectomy, drugs like calcium chelators, massive blood transfusion, critical illness, parathyroid hormone resistance, and vitamin D resistance (1, 3).

Pseudohypoparathyroidism (PHP) refers to a group of metabolic disorders in which resistance to parathyroid hormone leads to hypocalcaemia, hyperphosphatemia, and elevation of serum PTH level in the setting of normal renal function (4).

PHP has 5 subtypes: 1a, 1b, 1c, 2 and pseudopseudohypoparathyroidism. 1a and 1c have characteristic Albright's Hereditary Osteodystrophy (AHO) that demonstrates with round face, short stature, obesity, dental hypoplasia, brachymetacarpals, brachymetatarsals and soft tissue calcifications (5).

### Case Report

A 53-year-old lady brought to our emergency department with chief complaint of headache and paresthesia. She had a history of hypertension from about five years ago and hypothyroidism from ten years ago. She denied any other past medical history. She was on Levothyroxine 0.1 mg for her hypothyroidism and Losartan 50 mg daily for her hypertension. She does not use any cigarettes or alcohol. On physical examination she was a little fat (W=75 Kg, H=156 cm, BMI=30.81). Her blood pressure was 170/100 mmHg, and her pulse rate was 70. Phondoscopic examination was normal and had not any neck stiffness. Visual field and neurologic examination were within normal limits. Other physical exams were normal. In her brain CT scan there was small hyper densities in Thalamus, Temporal and parietal lobes (Figure 1). Thus, she was admitted with diagnosis of intra-cranial hemorrhage. After the lab tests was done, because of hypocalcaemia and hyperphosphatemia an internal medicine consultation was requested. She had just history of paresthesia and on physical examination she had positive Chvostek sign, round face, little fingers, and especially she had bilateral short forth feet fingers (Figure 2). On the lab data, her CBC was normal, her calcium was 6.5 mg/dl and phosphorus was 6.1 mg/dl, Mg was 1.8mg/dl, TSH was 2.1 mIU/l, Cr level was 1 mg/dl and vitamin D level was 26 ng/ml. Other lab tests and electrolytes were within normal limits. So, we thought maybe she had hypoparathyroidism and those hyper densities in her CT scan were calcification. Accordingly, PTH level was tested; it was 209 pg/ml (9-94). With her lab tests and body feature she was diagnosed with Pseudohypoparathyroidism. Because of her HTN secondary work up was done. Every test was

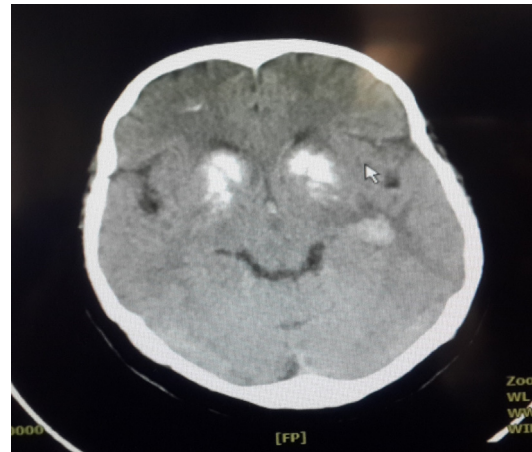


Figure 1. Her brain CT scan

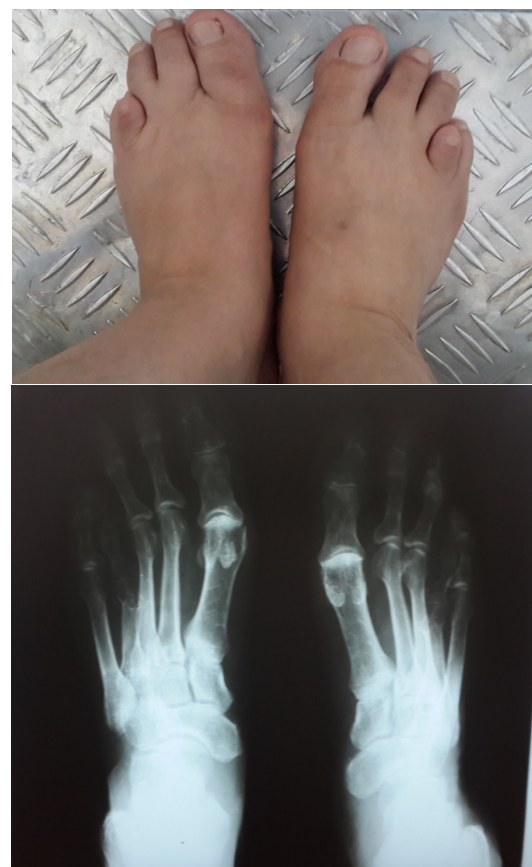

Figure 2. Radiography of her feet

normal and we ruled out Hyperaldosteronism, Cushing disease and Pheochromocytoma.

### Discussion

Hypocalcaemia is a dangerous electrolyte imbalance with 18% prevalence in hospital admitted patients. Mild or chronic hypocalcaemia could be asymptomatic (1). Regulation of calcium level is by 3 main calcium-regulating hormones. These hormones

are parathyroid hormone (PTH), vitamin D, and calcitonin; and they act by effecting on the bowel, kidneys, and skeleton. Nearly half of total serum calcium is bound to protein especially albumin, so serum calcium levels must be corrected for the albumin level before confirming the diagnosis of hypocalcaemia (2).

Sign and symptoms of hypocalcaemia include numbness and tingling sensation in fingers and toes, spontaneous muscle cramps, diminished deep tendon reflexes, papilledema, mental changes, weakness, fatigue, irritability, memory loss, confusion, delusion, hallucination (6), and in severe cases even seizure presents. In clinical examination carpopedal spasms which are dominant in hands than feet, Chvostek's or Trousseau's sign can be detected (7).

Causes of hypocalcaemia includes vitamin D deficiency, hypoparathyroidism, renal diseases, hypomagnesaemia, hungry bone disease after parathyroidectomy, drugs like calcium chelators, massive blood transfusion, critical illness, parathyroid hormone resistance, and vitamin D resistance.<sup>1,3</sup> In our case hypomagnesaemia and hypovitaminose D were ruled out by lab tests. Serum Cr level was normal. She did not have any surgical history and did not use calcium chelators. So, in the next step we study PTH level to investigate if she had hypoparathyroidism.

Hypoparathyroidism results from the destruction of the parathyroid glands. It could be surgical or autoimmune. Other factors that lead to Hypoparathyroidism are abnormal parathyroid gland development, altered regulation of parathyroid hormone production or impaired PTH action. PTH regulates calcium level by direct effect on bone metabolism and kidney (8, 9). Hypoparathyroidism demonstrates with low serum calcium levels, elevated serum phosphorus levels, and absent or inappropriately low levels of parathyroid hormone (10).

Brachymetatarsia or hypoplastic metatarsal is a rare physical finding in adolescence that can be seen after trauma or in some genetic disorders like Aarskog syndrome, Albright's hereditary osteodystrophy and Apert syndrome (11).

Pseudohypoparathyroidism (PHP) refers to a group of metabolic disorders in which resistance to parathyroid hormone leads to hypocalcaemia, hyperphosphatemia, and elevation of serum PTH level in the setting of normal renal function (4). It was the first hormone resistance that was first described by

Albright et al (12). The prevalence of this disorder is approximately 1/100000 (13). PHP has 5 subtypes: 1a, 1b, 1c, 2 and pseudopseudohypoparathyroidism. 1a and 1c have characteristic of Albright's hereditary osteodystrophy (AHO) that demonstrates with round face, short stature, obesity, dental hypoplasia, brachymetacarpals, brachymetatarsals and soft tissue calcifications.<sup>5</sup> In our patient we had hypocalcaemia, hypophosphatemia against high PTH levels, and intracranial calcification with characteristic AHO phenotype, that reminds us to the diagnosis of PHP type 1a or 1c. The interesting point of this patient was 4<sup>th</sup> finger brachymetatarsal and intracranial calcification which was confused with intracranial hemorrhage.

## References

1. Cooper MS, Gittoes NJ. Diagnosis and management of hypocalcaemia. *Bri Med J*. 2008;336(7656):1298.
2. Fong J, Khan A. Hypocalcemia. *Canad Fam Physic*. 2012;58(2):158-162.
3. Hoorn EJ, Zietse R. Disorders of calcium and magnesium balance: a physiology-based approach. *Pediatr Nephrol*. 2013;28(8):1195-1206.
4. Weinstein LS. Albright hereditary osteodystrophy, pseudohypoparathyroidism, and Gs deficiency. *G proteins, receptors, and disease*, Springer: 1998:23-56.
5. Chen H, Tseng F, Su D, Chen H, Tsai K. Multiple intracranial calcifications and spinal compressions: rare complications of type 1a pseudohypoparathyroidism. *J Endocrinol invest*. 2005;28(9):646-650.
6. Juan D. Hypocalcemia: Differential diagnosis and mechanisms. *Arch Int Med*. 1979;139(10):1166-1171.
7. Guise TA, Mundy GR. Clinical review 69: Evaluation of hypocalcemia in children and adults. *J Clin Endocrinol Metabol*. 1995;80(5):1473-1478.
8. Shoback D. Hypoparathyroidism. *New Eng J Med*. 2008;359(4):391-403.
9. Feldman EC. Hypocalcemia and primary hypoparathyroidism. *Canine and Feline Endocrinology: Fourth Edition*, Elsevier Inc. 2014.
10. Bilezikian JP, Khan A, Potts JT, Brandi Jr ML, Clarke BL, Shoback D, et al. Hypoparathyroidism in the adult: Epidemiology, diagnosis, pathophysiology, targetorgan involvement, treatment, and challenges for future research. *J Bone Mine Res*. 2011;26(10):2317-2337.

11. Schimizzi A, M. Brage. Brachymetatarsia. *Foot Ankle Clin.* 2004;9(3):555-570.
12. Mantovani G. Pseudohypoparathyroidism: diagnosis and treatment. *J Clin Endocrinol Metabol.* 2011;96(10):3020-3030.
13. Underbjerg L, Sikjaer T, Mosekilde L, Rejnmark L. Pseudohypoparathyroidism—epidemiology, mortality and risk of complications. *Clin Endocrinol.* 2016;84(6):904-911.