

A Long-Term Chronic Scrotal Actinomyces in a Middle-Aged Patient in Kerman



Nasim Eftekhari^{1*} , Mehdi Khaleghinia²

1. Department of Microbiology, Kerman Branch, Islamic Azad University, Kerman, Iran.
 2. Department of Infectious Diseases, Razi Firoz Hospital, Kerman, Iran.



Citation: Eftekhari N, Khaleghinia M. A Long-Term Chronic Scrotal Actinomyces in a Middle-Aged Patient in Kerman. Case Reports in Clinical Practice. 2018; 3(3):68-72.

Running Title: Scrotal Actinomyces.



Article info:

Received: 02 July 2018

Revised: 08 August 2018

Accepted: 18 September 2018

Keywords:

Actinomyces; Scrotum; Testis; Malignancy

ABSTRACT

Actinomyces species are non-spore forming Gram-positive bacilli. They are part of human/animal's micro-flora and are also among soil inhabitants. Actinomyces is an opportunistic, indolent, slow growing, chronic progressive and granulomatous infection caused primarily by *Actinomyces israelii*. Less than 100 cases of *Actinomyces neuii* isolates have been reported in the literature. Our case is a 47-year-old man who recognized two painless nodules in his scrotum six months after military training. He did not reveal his problem. Ten years later, both lesions inflamed and ruptured. He had been treated empirically. About 15 years later, the inflammation reappeared along with general sign and symptoms of acute disseminated infectious disease. In microbiology examination, *Actinomyces neuii* was isolated from purulent aspirate of scrotal lesions. Along with surgical drainage of abscess, he was treated with antibiotics.

Physicians must remember that chronic, not purulent lesions of Actinomyces may be misdiagnosed with malignancies, too. Some patients like our case may ignore mild sexual disease for its anatomic site. This ignorance may lead to a severe infection.

Introduction

A

Actinomyces spp. belong to Actinomyces genus and are anaerobic/aerotolerant, branching, filamentous, and slow growing Gram-positive bacilli [1-3].

In human, the most frequent locations infected by the *Actinomyces* spp. are cervicofacial area mainly because of poor bucco-dental hygiene. Less frequently, abdominal and pelvic locations are involved often an extension of a dispositive intrauterine [4].

* Corresponding Author:

Nasim Eftekhari, PhD.

Address: Department of Microbiology, Kerman Branch, Islamic Azad University, Kerman, Iran.

E-mail: nasim.eftekhari180@gmail.com

Actinomycosis is an opportunistic, indolent, slow growing, chronic progressive and granulomatous infection caused primarily by *Actinomyces israelii* [5, 6]. It has a tendency to form external sinuses and or multiple abscesses [7]. It is an infrequent sporadic invasive bacterial disease that has been recognized for over one century [2]. To date, multiple different clinical features of Actinomycosis have been described in various anatomical sites such as face, bone and joint, respiratory or digestive tract, central nervous system, skin, soft tissue structures and genitourinary tract [2].

In women, the genital Actinomyces infection usually represent a complication of the usage of intrauterine device that often presents as a pelvic mass mimicking pelvic malignancy [5]. However in men, Actinomyces infections are uncommon and sporadic which present as nodular lesions on the testis or other parts of urogenital tract [6-8]. When it only affects the testicles, the presentation can mimic malignancy [6]. Performing a microbiology test can discriminate an easy curable infectious disease from a life treating problem. We present a case of long-term chronic scrotal Actinomycosis in a middle-aged patient that could be related to his military training.

Case Presentation

A 47-year-old man was admitted to the office of a pulmonary disease specialist complaining of fever, chill and tachypnea. The patient seemed to be ill with fever, tachycardia and tachypnea signs. His physical exam revealed testicular enlargement with skin induration and tenderness on palpation. He was married with one child. There was no history of diabetes or other underlying diseases. He was referred to the surgery ward of Arjomand Hospital, a private and general hospital in Kerman City, Iran. His medical history at the age of 20 revealed that 6 months after military training, he realized two lesions (nodules) on his scrotum with no pain or discharge. He was not concerned about them up to ten years later, when the lesions got enlarged and ruptured, along with fever and chill. Then, he had been treated empirically. However, around 15 years later, the lesions got inflamed suddenly with intensive pain, edema, and redness, simultaneous with fever, chill and tachypnea.

The laboratory blood tests revealed mild leukocytosis ($12700/\text{mm}^3$) with 75% neutrophils. Erythrocytes Sedimentation Rate (ESR) was 27 mm/h. The rest of the laboratory test results were insignificant. Concurrent with surgical drainage of the abscess, he was treated with sulfamethoxazole /trimethoprim 1000 mg every 6 h and ceftazidime 2 g every 8 h.

About 1.5–2 mL of purulent aspirate was sent to the medical microbiology laboratory. In macroscopic analysis, there were no sulfur granules in the pus. Two smears were prepared for direct microscopic examination and the remainder was inoculated in the biphasic thioglycollate broth (CONDA- Spain). After two days, the growth signs appeared (Figure 1). It was then subcultured on the Sheep Blood Agar (SBA) (Biolife, Italy). In direct study (methylene bleu and Gram staining), no distinct bacterium was identified among many inflammatory cells.

Translucent, pinpoint smooth colonies of bacteria were appeared 48 hours after subculture and incubation (35°C in 5% to 10 % CO_2) (Figure 2). Gradually in following days, they turned to the non-hemolytic opaque and white colonies. Gram staining revealed Gram-positive bacilli with irregular [V & Y] arrangement and no branching growth (Figure 3). They were non-motile, positive in catalase, and negative in oxidase and urease testes. They also fermented glucose, maltose and sucrose.

According to the morphological and arrangement features, especially the absence of branching and the result of biochemical testes, the isolates would most likely were *Actinomyces neuii* [1, 2]. The patient was discharged with normal blood test and continuing treatment with sulfamethoxazole/trimethoprim, ceftazidime and

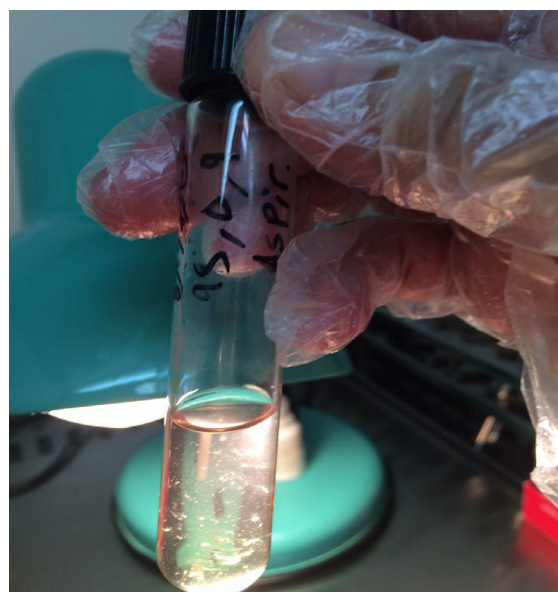


Figure 1. The growth of *A. neuii* in the thioglycollate medium after 48 hours

Notice the growth of bacteria in both aerobic and anaerobic portion with the figure of bacterial colonies that mimic bread crumbles.

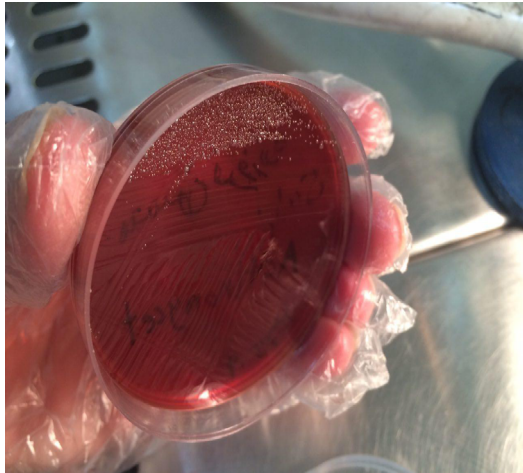


Figure 2. Translucent and white, pinpoint and smooth colonies of *A. neuii*

They were appeared about 48 hours after subculture and incubation in 35°C with 5% to 10% CO₂.

clindamycin 300 mg every 8 hours for two weeks. According to direct patient's report, the lesions were gradually resolved in 4-6 weeks. Written informal consent got from the patient for publication in the paper.

Discussion

The commensal germ *Actinomyces* spp. can rarely become pathogenic. The contamination typically done by

ascendant pathway follows up by an eruption from the cutaneous or mucosal barrier [4, 7]. It occurs worldwide and men are more infected than women [5].

Primary skin and soft tissue Actinomycosis must be differentiated from chronic inflammatory skin diseases, cutaneous mycobacterial infections, and sporotrichosis. Actinomycosis may mimic the malignancy process in various anatomical sites [2]. Talking about male genitourinary tract Actinomycosis, Lin (2005) reported that they found only 9 documented cases of *Actinomyces* affecting testis in the English literature [6]. Actinomycosis of the penis is also an uncommon malady. Up to 2008, only 5 cases had been reported in English articles [8].

In 2014, Crescencio in the USA reported testicular Actinomycosis abscess with bacteremia in a young man, probably, due to contamination from environment/by instrument four weeks after orchietomy [1]. In India, a poor middle-aged man was referred to a public clinic for multiple areas of painless purulent discharge from buttocks [5]. *Actinomyces israelii* was isolated from the culture. In veterinary field, Ayrs (1977) reported a case of Actinomycosis of testes and spermatic cord in a 4-year-old German shepherd dog [9].

Although *Actinomyces israelii* is the most common pathogenic species in man [5, 6], other *Actinomyces* such as *A. naeslundii*, *A. viscosus*, *A. odontolyticus* [4, 10] and in a few cases *A. neuii* have also been isolated

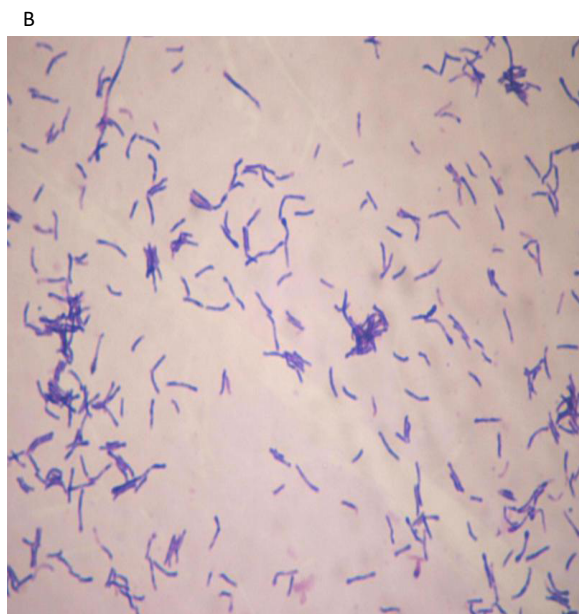
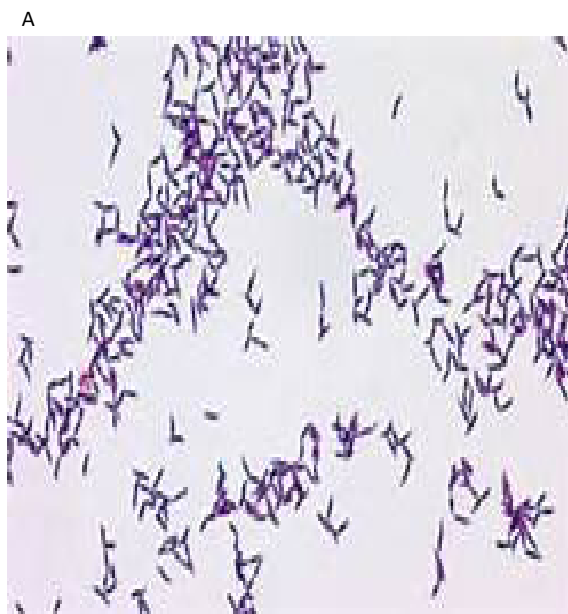
Figure 3. Two pictures of microscopic character of *A. neuii*

A: Gram Staining, and B: Methylene blue Staining.

Notice about the arrangement of bacteria that resemble Coryneform with no branching filaments.



from urogenital infections [1, 3, 8]. Totally, less than 100 *Actinomyces neuii* cases have been reported in the literature [7]. In other words, *Actinomyces neuii* represent 17% of all clinical *Actinomyces* isolates [1]. In a review article, Zelyas et al. (2016) reported a case of post-operative *A. neuii* scrotal abscess in a 68-year-old patient in Canada [8]. Cha case in 2008 had penile shaft Actinomycosis coexisting with fibrous pseudo-tumor of testis [10].

Unlike a few cases of genital/anorectal Actinomycosis, no linked predisposing factors were reported [5, 10]. Before 1994, *A. neuii* was classified as member of CDC (center for disease control) fermentative coryneform group 1 or group 1-like [8]. Similar to other *Actinomyces* spp, they are Gram-positive non-motile rods, catalase positive, urease negative, esculin hydrolysis negative, alpha/non-hemolytic and maybe CAMP positive [8]. Moreover, they ferment glucose, maltose and some other carbohydrates [7]. However in contrast to most *Actinomyces* spp, they tolerate aerobic condition with irregular arrangement that do not display the typical branching filaments of *Actinomyces* spp [1, 8]. In the presented case, according to the microscopic feature, growth, and biochemical characters, the bacterial isolate was *A. neuii*.

For the reason of miscellaneous phenotypic types of *Actinomyces* species, the precise identification of strains is performed by 16S rRNA gene sequence analysis [1]. However, the required facilities were not available in our laboratory. During desert training, military personnel often suffer from the superficial infections [11]. In a 7-year retrospective study, Rahimi et al. reported 2.1% of superficial fungal infections in army personnel [11]. In the presented case, concerning the time of appearance of first nodules, the lesions were probably the result of invasion of *Actinomyces* from dusty clothing or soil. Apparently, in the second and final recurrence, he was examined by pulmonary specialist because of fever and tachypnea. He had probably forgotten or ignored his main infection foci.

Testicular Actinomycosis has a tendency to form external sinuses [12]. Therefore, its diagnosis and treatment become easy. However, some cases mimic metastatic malignant tumors like Lin's case, reported in 2005, who had multiple testicular lesions with history of gastric adenocarcinoma [6]. In the presented case of Abi (2017), a 22 years old man had no specific external signs except permanent pain at left bursa [4]. Juni presented a case (in 1990) that suffered from disseminated Actinomycosis, presenting as a testicular mass [7]. Preoperative diagnosis of his patient was testicular carcinoma.

As for medical chemotherapy, the treatment of the presented case was begun with sulfamethoxazole/trime-thoprim and ceftazidime before receiving culture results. Jani believed that many patients with less severe disease due to *Actinomyces* spp, require only prolonged penicillin [7]. However, Zelyas in a review article compared the MICs (minimum inhibitory concentrations) of penicillin G, amoxiclav, imipenem, vancomycin and clindamycin against *Actinomyces* that were isolated from different sites of different cases [8]. He concluded that all verified isolates were generally quite susceptible to the tested antibiotics [8]. Crescencio started vancomycin, gentamycin and clindamycin [1]. Then, he continued the treatment after surgery of testicular abscess due to *Actinomyces neuii* with piperacillin/tazobactam and vancomycin IV. Pending culture results, he discharged the patient with ertapenem and vancomycin IV for 14 days [1].

Ignorance or insufficient treatment of primary Actinomycosis can turn it into a chronic, relapsing disease that its treatment might be difficult. For the reason of mild discomfort and or specific anatomical site of lesion (s), the patient may pay no attention to the symptoms of the infection. Like the presented case, this ignorance can lead to a serious problem. The organism *Actinomyces neuii* is typically aerotolerant Gram-positive rods that do not grow branching filaments. Contrary to most *Actinomyces* spp., their growth rate is rather fast. Therefore in the laboratory identification, they may misdiagnosed with *Diphtheroid* spp. (contaminating agent).

Ethical Considerations

Compliance with ethical guidelines

All ethical principles were considered in this article. The participant was informed about the purpose of the research and its implementation stages.

Funding

This research did not receive any specific grant from funding agencies in the public, commercial, or not-for-profit sectors.

Conflict of interest

The authors declare no conflict of interest.

Acknowledgements

We sincerely appreciate Dr. Zahra Eslaminejad who kindly performed all bacteriology tests in her Medical Microbiology Lab, Kerman, Iran.

References

- [1] Crescencio JC, Koshy R. Postoperative testicular abscess with bacteremia due to *Actinomyces neuii*. IDCases. 2014; 1(3):36-7. [DOI:10.1016/j.idcr.2014.05.002] [PMID] [PMCID]
- [2] Valour F, Sénéchal A, Dupieux C, Karsenty J, Lustig S, Breton P, et al. Actinomycosis: Etiology, clinical features, diagnosis, treatment, and management. Infection and Drug Resistance. 2014; 7:183-97. [doi: 10.2147/IDR.S39601] [PMID] [PMCID]
- [3] Tille PM. Bailey & Scott's diagnostic microbiology. Saint Louis: Elsevier; 2017.
- [4] Abi R, Tagajdid MR, Janvier F, Bousquet A, Larréché S, Mérens A. Scrotal abscess caused by actinomycosis turicensis: About an observation and literature review. International Journal of Research in Medical Sciences. 2017; 5(4):1692-4. [DOI:10.18203/2320-6012.ijrms20171288]
- [5] Chatterjee M. Gluteal primary cutaneous actinomycosis. Indian Journal of Dermatology. 2005; 50(3):152-4. [DOI:10.18203/2320-6012.ijrms20171288]
- [6] Lin CY, Jwo SC, Lin CC. Primary testicular actinomycosis mimicking metastatic tumor. International Journal of Urology. 2005; 12(5):519-21. [DOI:10.1111/j.1442-2042.2005.01092.x] [PMID]
- [7] Jani AN, Casibang V, Mufarrij WA. Disseminated actinomycosis presenting as a testicular mass: A case report. The Journal of Urology. 1990; 143(5):1012-4. [DOI:10.1016/S0022-5347(17)40172-8]
- [8] Zelyas N, Gee S, Nilsson B, Bennett T, Rennie R. Infections caused by *actinomyces neuii*: A case series and review of an unusual bacterium. Canadian Journal of Infectious Diseases and Medical Microbiology. 2016; 2016:6017605. [DOI:10.1155/2016/6017605] [PMID] [PMCID]
- [9] Ayers KM, Wroe GE, de Paoli A. Actinomycosis of the testes and spermatic cord in a dog. Veterinary Pathology. 1997; 14(3):287-8. [DOI:10.1177/030098587701400312] [PMID]
- [10] Cha EJ, Jang KY, Park HS, Park JK, Lee CS, Chung MJ, et al. Actinomycosis of the penile shaft coexisting with fibrous pseudotumor of the testis pseudotumors of the testis. The Korean Journal of Pathology. 2008; 42:50-3.
- [11] Rahimi Dehgolan S, Hosseini Shokouh SJ, Noorifard M, Dabagh Moghaddam A, Tabibian E. Epidemiology of superficial fungal infections in Iran army personnel. Journal of Archives in Military Medicine. 2014; 2(2):1-4. [DOI:10.5812/jamm.18643]
- [12] Chudackova E, Geigerova L, Hrabak J, Bergerova T, Liška V, Scharfen J. Seven isolates of *actinomyces turicensis* from patients with surgical infections of the anogenital area in a Czech hospital. Journal of Clinical Microbiology. 2010; 48(7):2660-1. [DOI:10.1128/JCM.00548-10] [PMID] [PMCID]