



# A Rare Case of Lumbar Chondroma and Review of Literature in This Topic



Babak Mirzashahi<sup>\*</sup>, Mohammad Javaad Dehghani Firoozabadi, Furqan Mohammed Yaseen Khan, Mehdi Hishmatifar

Department of Orthopedic Surgery, School of Medicine, Tehran University of Medical Sciences, Tehran, Iran.



**Citation** Mirzashah B, Dehghani Firoozabadi MJ, Yaseen Khan FM, Hishmatifar M. A Rare Case of Lumbar Chondroma and Review of Literature in This Topic. Case Reports in Clinical Practice. 2018; 3(4):100-105.

**Running Title** Lumbar Chondroma Case Report



## Article info:

**Received:** 08 October 2018

**Revised:** 05 November 2018

**Accepted:** 09 December 2018

## Keywords:

Spine; Lumbar vertebrae;  
Enchondroma; Scoliosis

## ABSTRACT

Enchondroma is a kind of bone hamartoma and a benign hyaline cartilage tumor. Although it is the most common benign tumor of bone, it is quite rare in the spine, especially the lumbar spine. We report a case of chondroma that was located in the lumbar spine, which extended from L2 to L5 in a 4.5-year-old child. He visited our clinic with a complaint of spine deformity and limping for 3 years. Surgical resection of large ossified mass was performed and pathologically confirmed to be a benign hamartoma of hyaline cartilage with enchondral ossification. Resection of mass released the tethering effect and balanced the growth speed of spine bilaterally. It is suggestive of a congenital developmental malformation with hamartomatous features and reactive changes.

## Introduction

**E**nchondroma is a kind of bone hamartoma and a benign hyaline cartilage tumor. Enchondroma is mostly seen in long bones of extremities, in bones of foot and hand, infrequently in ribs and pelvis, and rarely in intracranial bones [1].

Although it is the most common benign tumor of bone, it is quite rare in the spine, especially the lumbar spine [2]. Chondroma in the spine comprises 3% of all chondroma and is commonly encountered in the thoracic spine [3]. To our knowledge, only 16 cases of chondroma in lumbar spine have been reported in the literature since 1928 [2, 4]. Our patient was 4.5 years old with chondroma of lumbar spine extending from L2

## \* Corresponding Author:

**Babak Mirzashahi, MD.**

**Address:** Department of Orthopedic Surgery, School of Medicine, Tehran University of Medical Sciences, Tehran, Iran.

**E-mail:** [babakmirzashahi@gmail.com](mailto:babakmirzashahi@gmail.com)

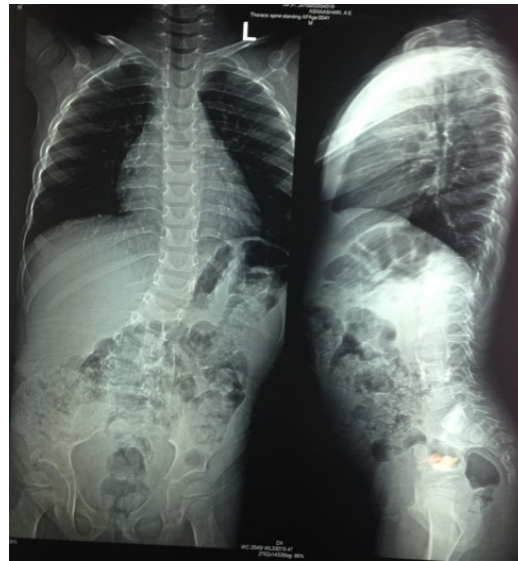

Figure 1. AP and lateral view of Lumbo-sacral spine

to L5. There was no report of such cases in patients as young as our case.

### Case Presentation

A 4.5-year-old child presented with progressive spine deformity since the age of 6 months. The patient developed painless claudication, limping from the time when he started walking. The patient's family consulted several physicians and received different treatments without any improvement. When all therapeutic attempts failed and he was 4 years old, he was referred to our clinic due to progressive spine deformity and limping.

Examinations revealed excessive lumbar lordosis, left lumbar scoliosis, pelvic obliquity, and hip flexion con-

tracture. No neurologic deficit was noted. X-ray images showed a radiopaque homogenous left paraspinal mass in lumbar spine which extended from L2 to L5 (Figure 1). In CT scan, a large irregular ossified mass (45×25×20 mm) within left psoas muscle was revealed which extended from L2 to L5 levels and had pressure effect upon the left side of the vertebral body and lumbar vertebrae (L2 to L5) were deformed due to this pressure effect (Figure 2). MRI confirms large ossified component in the left side of the lumbosacral spine as mentioned above resulting in dextroscoliosis with no interval change comparing with previous MRI (Figure 3). Electrophysiological study (EMG-NCV) and all laboratory investigations were normal. The patient was elected for surgery for resection of mass and correction of the deformity.

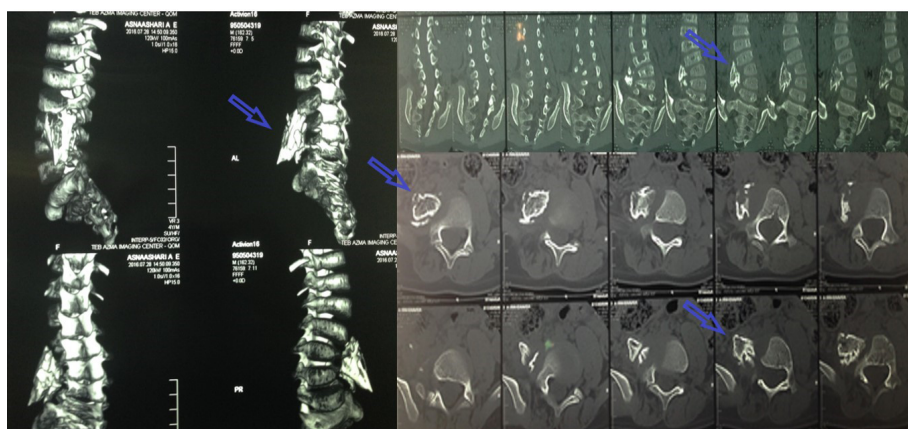
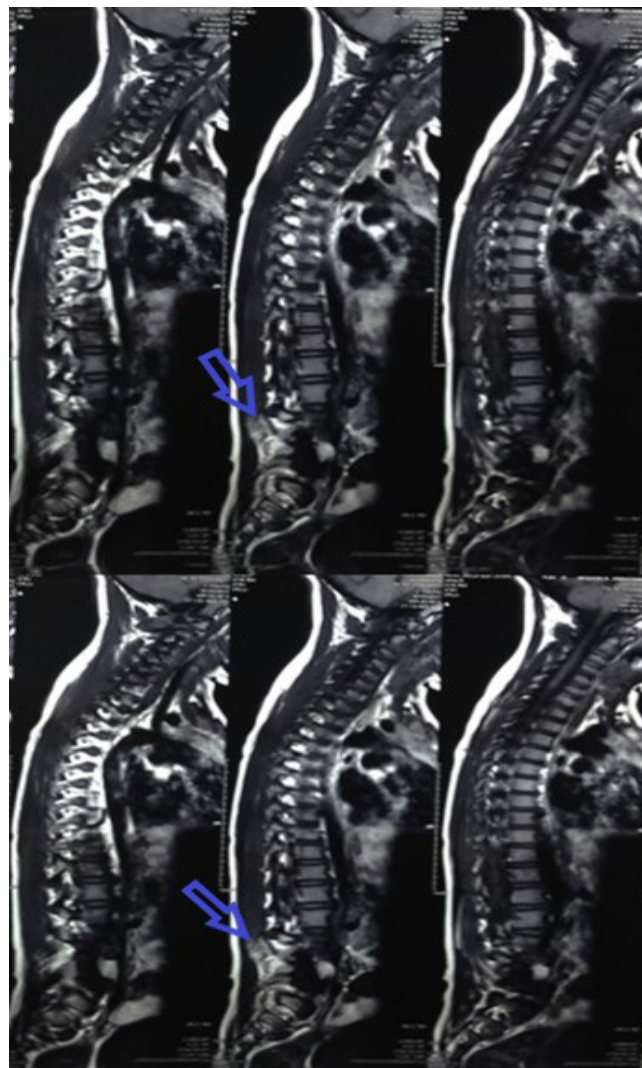


Figure 2. CT scan of the lumbar spine



**Figure 3.** MRI scan of the whole spine revealing large ossified component on left lumbosacral spine resulting in dextroscoliosis



### Surgical technique

The patient was positioned in left lateral decubitus, and lateral retroperitoneal approach was used by a 10-cm incision. Abdominal muscles were dissected in layers and at first, the ureter and major vessels were explored by a general vascular surgeon. Then, a large bony mass with huge fibrosis attached to L2, L3, L4, L5 vertebra, and sacrum was seen. The mass was removed as piecemeal. The mass appeared to be dense with cortical bone-like consistency and had a firm attachment to the lateral side of vertebral bodies. In surgery, we tried to remove all the mass to release the spine and remove its tethering effect.

### Postop and follow-up

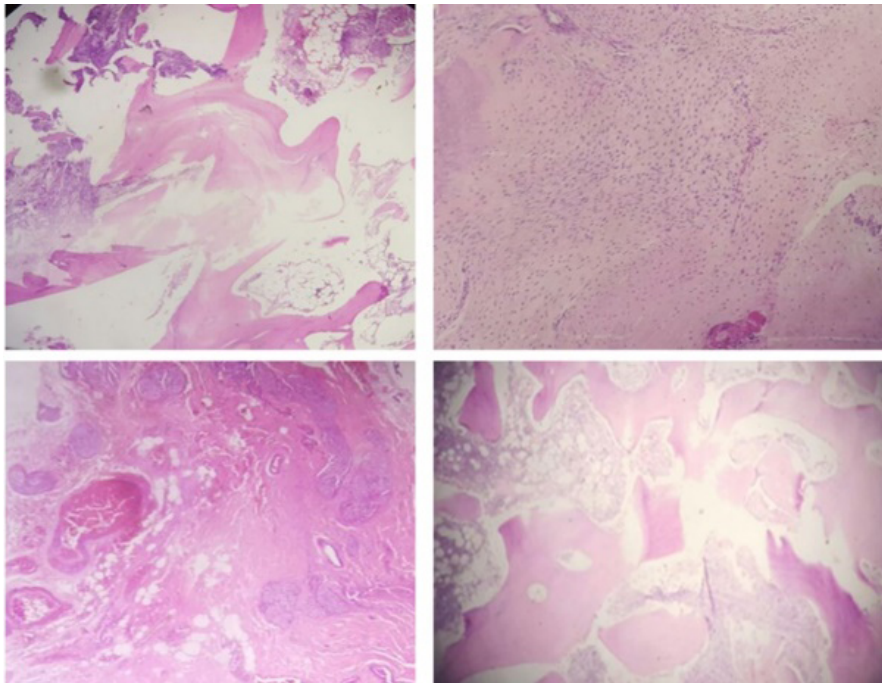
After the surgery, the neurologic examination was normal. The drain was removed after 48 hours and the

patient was mobilized; he was able to walk by himself. He was discharged 3 days later. On follow up after 2 weeks, the patient had no problems and the surgical wound was completely healed. The pathologic result was hyaline and elastic cartilage in some foci with endochondral ossification (Figure 4). Postoperative X-ray and CT scan showed spine free of mass and a relative improvement of lumbar scoliosis (Figure 5).

After 4 months, the patient had no pain and limping; in the physical examination, there was no pelvic obliquity and both iliac crests were at the same level. A mild degree of flexion contracture was noted in both hips. The patient and family were satisfied with the results.

### Discussion

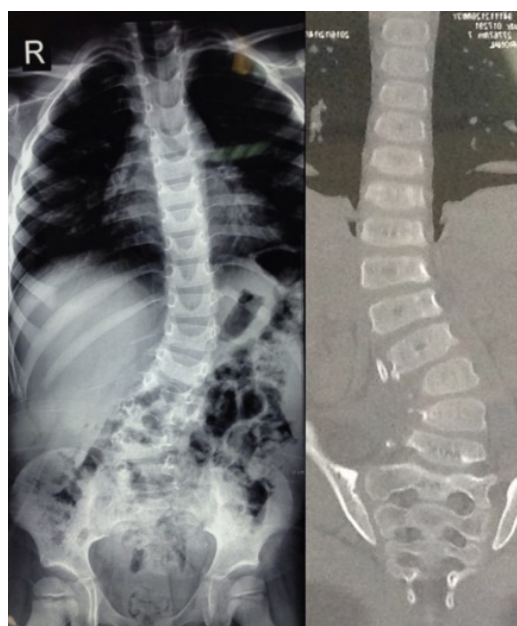Hamartoma is a tumor-like lesion, which contains different kinds of growing cells and tissues. It grows in any



**Figure 4.** Histological slides of resected tumor

part of the body as a developmental malformation [3]. It may appear like a disease or a set of the syndromes. For example, it may appear in bone as a benign tumor or pathological fracture. Bone hamartoma can be classified into four groups: fiber forming, bone forming, cartilage forming, and benign non-matrix forming. Another kind of bone hamartoma is histopathologically reported as enchondroma [2, 4].

Chondroma is a benign bony tumor, which is known as well-differentiated hyaline cartilage tumor. Enchondroma contributes 12-14% of the benign bone tumors and 3-10% of all bone neoplasms [5]. About 30% of these patients may progress to a malignant tumor and 25% of the patients may develop sarcoma [6-8]. Bone cartilage tumors are classified into 4 groups: Osteochondroma,



**Figure 5.** Postoperative X-ray and CT scan

chondroma, chondroblastoma, and chondromyxoid fibroma [9].

Although chondroma will manifest as enchondroma and periosteal chondroma, enchondroma mostly seen in upper extremities, especially in hand. Other rare regions of involvement are long bones, ribs, and spine [9-11]. Spinal enchondroma is very rare [12, 13], especially in the lumbar spine [2]. Progressive neurologic signs will appear in rare cases because of slow tumor growth [3, 11]. Enchondroma in the spine is presented by localized pain, palpable mass, pathologic fracture, and spinal cord compression [14, 15]. But in this case, the patient had no pain and presented with progressive lordoscoliosis in lumbar spine and claudication.

In X-ray images, enchondroma appears in metaphyseal or diaphyseal part of long bones and it might be heavily or partially mineralized. Mineralized patterns show ring, arch, or stippled radiodensities in X-ray. Because of similar manifestation in MRI, differentiation between low-grade chondrosarcoma and enchondroma is very important [10].

MRI is useful in evaluating for soft tissue extension and confirming the diagnosis. Enchondroma appears as well-circumscribed lobulated masses replacing marrow [16]. T1 weighted images of MRI shows intermediate to low-signal intensity. In T1–Gad, enhancement is variable and may be seen both peripherally or of translesional septae. A similar pattern of enhancement may be seen in chondrosarcomas [17, 18]. T2 images show typically background high signal intensity which can be focal regions of signal drop out where calcification is present; it shows no bone marrow or soft tissue edema.

Russo et al. reported a case of cervical spine chondroma and claimed that its differentiation from low-grade chondrosarcoma is problematic, as they can have very similar appearances. However, the increased uptake in the bone scan is diagnostic. Wide or marginal excision with neurovascular preservation and stability of the spine is a treatment of choice in spine enchondroma [19].

The recurrence rate in enchondroma is less than 10% [9, 14]. Ogata et al. claimed that radiotherapy is effective when the tumor is not completely resected or a positive histologic margin exists. There is no significant evidence for neoadjuvant chemotherapy in these cases [9, 20].

To our knowledge, the enchondroma of the spine is very rare and there are only a handful of such cases reported in the literature. In this case, because of the uni-

lateral mass with its compression effect on the left side of lumbar vertebral bodies, progressive scoliosis and limping were the presenting symptoms of the tumor. It was affecting the spine as a unilateral mass which was very similar to the unilateral unsegmented bar in congenital scoliosis. With this concept, we decided to remove the mass to release the spine and equalize the growth speed on both sides of the spine and gradually spine deformity resolved. For this patient, a close biopsy was not made because there was not any malignant indication and the lesion seemed a congenital anomaly.

## Ethical Considerations

### Compliance with ethical guidelines

This case is reported in accordance with ethical guidelines of Tehran University of Medical Sciences. Informed consent was taken before reporting.

### Funding

This research did not receive any specific grant from funding agencies in the public, commercial, or not-for-profit sectors.

### Conflict of interest

The authors declared no conflict of interest.

## References

- [1] Erten F, Koçak A, Mizrak B, Kutlu R, Çolak A. An end-plate chondroma mimicking calcified lumbar disc herniation. *Neurosurgical Review*. 1999; 22(2-3):145-8. [DOI:10.1007/s101430050051] [PMID]
- [2] Kim DH, Nam KH, Choi BK, Han I. Lumbar spinal chondroma presenting with acute sciatica. *Korean Journal of Spine*. 2013; 10(4):252-4. [DOI:10.14245/kjs.2013.10.4.252] [PMID] [PMCID]
- [3] Lozes G, Fawaz A, Perper H, Devos P, Benoit P, Krivosic I, et al. Chondroma of the cervical spine: Case report. *Journal of Neurosurgery*. 1987; 66(1):128-30. [DOI:10.3171/jns.1987.66.1.0128] [PMID]
- [4] Antić B, Roganović Z, Tadić R, Ilić S. Chondroma of the cervical spinal canal. Case report. *Journal of Neurosurgical Sciences*. 1992; 36(4):239-41. [PMID]
- [5] Damron TA, Sim FH, Unni KK. Multicentric chondrosarcomas. *Clinical Orthopaedics and Related Research*. 1996; (328):211-9. [PMID]
- [6] Boriani S, Laus M. Chondromas and chondromatosis (A study of 265 cases, 200 with long term follow up). *Italian Journal of Orthopaedics and Traumatology*. 1978; 4(3):353-7. [PMID]

- [7] Liu J, Hudkins PG, Swee RG, Unni KK. Bone sarcomas associated with Ollier's disease. *Cancer*. 1987; 59(7):1376-85. [DOI:10.1002/1097-0142(19870401)59:73.0.CO;2-F]
- [8] Greenspan A. Tumors of cartilage origin. *Orthopedic clinics of North America*. 1989; 20(3):347-66. [PMID]
- [9] Fahim DK, Johnson KK, Whitehead WE, Curry DJ, Luerssen TG, Jea A. Periosteal chondroma of the pediatric cervical spine: Case report. *Journal of Neurosurgery: Pediatrics*. 2009; 3(2):151-6. [DOI:10.3171/2008.11.PEDS08231] [PMID]
- [10] Douis H, Saifuddin A. The imaging of cartilaginous bone tumours. II. Chondrosarcoma. *Skeletal Radiology*. 2013; 42(5):611-26. [DOI:10.1007/s00256-012-1521-3] [PMID]
- [11] Kondrom LS. Lumbar spinal chondroma presenting with radiculopathy: Case report. *Turkish Neurosurgery*. 2008; 18(4):397-9. [PMID]
- [12] Slowik T, Bittner-Manioka M, Grochowski W. Chondroma of the cervical spine: Case report. *Journal of Neurosurgery*. 1968; 29(3):276-9. [DOI:10.3171/jns.1968.29.3.0276] [PMID]
- [13] Willis BK, Heilbrun MP. Enchondroma of the cervical spine. *Neurosurgery*. 1986; 19(3):437-40. [DOI:10.1227/00006123-198609000-00017] [PMID]
- [14] McLoughlin GS, Sciubba DM, Wolinsky JP. Chondroma/chondrosarcoma of the spine. *Neurosurgery Clinics of North America*. 2008; 19(1):57-63. [DOI:10.1016/j.nec.2007.09.007] [PMID]
- [15] Singh AP, Singh AP, Mahajan S. Periosteal chondroma of the sacrum. *Canadian Journal of Surgery*. 2008; 51(5):E105-6. [PMID] [PMCID]
- [16] Walden MJ, Murphey MD, Vidal JA. Incidental enchondromas of the knee. *American Journal of Roentgenology*. 2008; 190(6):1611-5. [DOI:10.2214/AJR.07.2796]
- [17] Murphey MD, Flemming DJ, Boyea SR, Bojeskul JA, Sweet DE, Temple HT. Enchondroma versus chondrosarcoma in the appendicular skeleton: Differentiating features. *Radiographics*. 1998; 18(5):1213-37. [DOI:10.1148/radiographics.18.5.9747616] [PMID]
- [18] Aoki J, Sone S, Fujioka F, Terayama K, Ishii K, Karakida O, et al. MR of enchondroma and chondrosarcoma: Rings and arcs of Gd-DTPA enhancement. *Journal of Computer Assisted Tomography*. 1991; 15(6):1011-6. [DOI:10.1097/00004728-199111000-00021] [PMID]
- [19] Russo V, Platania N, Graziano F, Albanese V. Cervical spine chondroma arising from C5 right hemilamina: A rare cause of spinal cord compression. Case report and review of the literature. *Journal of Neurosurgical Sciences*. 2010; 54(3):113-7. [PMID]
- [20] Ogata T, Miyazaki T, Morino T, Nose M, Yamamoto H. A periosteal chondroma in the lumbar spinal canal: Case report. *Journal of Neurosurgery: Spine*. 2007; 7(4):454-8. [DOI:10.3171/SPI-07/10/454] [PMID]