



## Unilateral Thalamic and Basal Ganglia Edema Associated with Deep Venous Thrombosis Following Bacterial Meningitis

Abbas Tafakhori<sup>1</sup>, Seyed Sadeq Kalantar<sup>1</sup>, Amirhossein Modabbernia<sup>1</sup>, Vajiheh Aghamollai<sup>1</sup>

1- Iranian Center of Neurological Research, Tehran University of Medical Sciences, Tehran, Iran

Received: 20 June 2015

Revised: 8 August 2015

Accepted: 21 October 2015

### ARTICLE INFO

Corresponding author:  
Amirhossein Modabbernia

Email:  
amirh899@gmail.com

Keywords:  
Meningitis,  
Basal ganglia,  
Cerebral deep venous  
thrombosis,  
Thalamus

### ABSTRACT

A 40-year-old woman visited our emergency department due to a 3-day history of headache. She was found to have deep cerebral vein thrombosis, which was worsened after initiation of heparin treatment. We present her as the only reported case of unilateral thalamic and basal ganglia edema in the setting of deep vein thrombosis secondary to bacterial meningitis

**Citation:** Tafakhori A, Kalantar SS, Modabbernia A, Aghamollai V. **Unilateral Thalamic and Basal Ganglia Edema Associated with Deep Venous Thrombosis Following Bacterial Meningitis.** Case Rep Clin Pract 2016; 1(1): 4-6.

### Introduction

Deep cerebral venous thrombosis (DCVT) frequently causes bilateral thalamic/basal ganglia (BG) edema and infarction. Unilateral thalamic/BG edema following DCVT, however, has been reported in less than ten cases in the literature. Herein, we report the first case of unilateral thalamic/BG edema in the setting of DCVT occurring as a complication of bacterial meningitis.

### Case Report

A 40-year-old woman visited our emergency

department due to a 3-day history of headache and altered mental status. She had a history of rheumatoid arthritis for the past 10 years and took prednisolone 5 mg/day. In physical examination, fever and neck stiffness were absent. The patient was obtunded and disoriented. Optic disk was normal. Mild right hemiparesis was detected and a brain computed tomography (CT) scan showed mild hypodensity in the left basal ganglia.

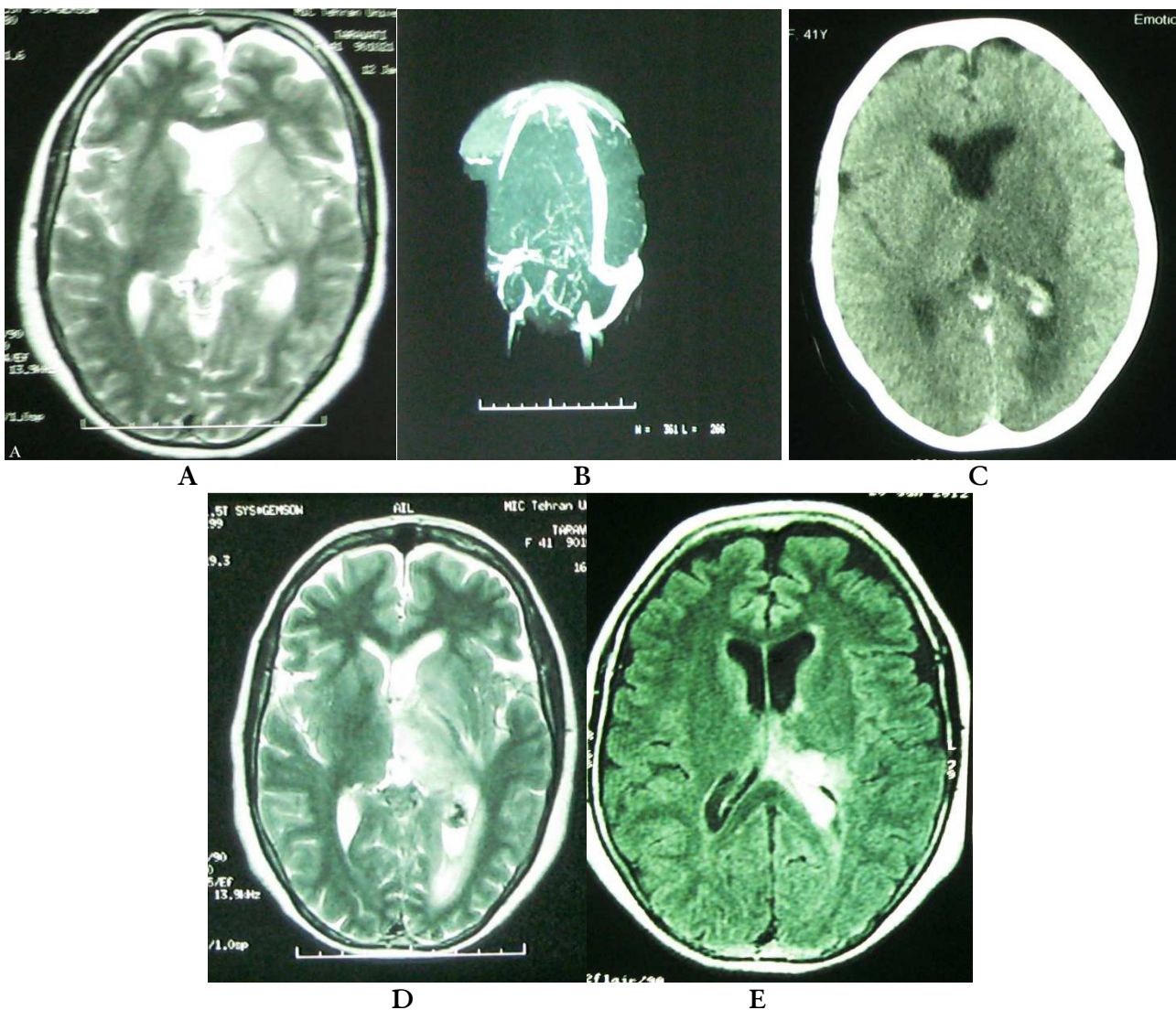
Brain magnetic resonance imaging (MRI) located an area of edema and enlargement in the left caudate, putamen, and thalamus and a mild hemorrhage of left choroid plexus

(Figure 1-A). These findings suggested thrombosis of deep cerebral veins which was then confirmed using magnetic resonance venography (MRV) (Figure 1-B).

Patient was immediately placed on heparin. Serial CT scans showed an expansion of choroid plexus hemorrhage (Figure 1-C). Simultaneously, a mild fever of 37.8 °C was detected. Heparin was stopped and the patient underwent a lumbar puncture (LP). Cerebrospinal fluid (CSF) glucose concentration was 35 mg/dl

(simultaneous blood glucose = 100 mg/dl) with protein of 120 mg/dl and white blood cells (WBC) of 2000 (predominance of polymorphonuclear cells).

Both clinical and neuroimaging conditions of the patient were markedly improved after initiation of antibiotics (Figure 1-D). Following treatment imaging showed an improvement of the BG edema and hemorrhage. The patient was discharged 35 days later with mild residual right-sided hemiparesis (Figure 1-E).



**Figure 1.** Neuroimaging studies, A. T2 weighted magnetic resonance imaging (MRI) prior to starting heparin: unilateral basal ganglia enlargement; B. Magnetic resonance venography (MRV) on admission: deep cerebral venous thrombosis; C. Brain computed tomography (CT) scan after heparin and before antibiotic therapy: hypodensity in the basal ganglia and ipsilateral choroid plexus hemorrhage; D. T2 weighted magnetic resonance imaging (MRI) three days after initiation of antibiotic therapy: improvement of basal ganglia edema and hyperintensity; E. Magnetic resonance imaging (MRI) fluid attenuated inversion recovery (FLAIR) cut 16 days after antibiotic treatment: improvement in basal ganglia and sequel of thalamic infarction and old hemorrhage of choroid plexus

## Discussion

DCVT may sometimes present with bilateral edema and infarction of thalamus and basal ganglia, but unilateral involvement is quite rare. Medical literature has reported less than ten cases of unilateral thalamic edema and/or infarction following deep venous thrombosis (1-6).

What was more important in our patient was not this association but its underlying cause. Bacterial meningitis is rarely if ever associated with DCVT. To the best of our knowledge, there is no report of such association in the published studies, although some cases of CVT (but not necessarily DCVT) have been reported in the setting of bacterial meningitis. As an example, in two large multicenter studies comprising 291 patients with CVT, three cases of CVT were associated with bacterial meningitis (7, 8).

The association of the DCVT with unilateral thalamic edema on the one hand, and the etiologic role of meningitis on the other hand, made our presented case a unique one in the medical literature. Few –if any– evidence has been published about the rate of hemorrhage expansion after introduction of anticoagulants in DCVT, but the incidence seems to be low (9).

Here, we should emphasize the central role of LP in management of this patient. Antibiotic was life-saving in our case, both acting on the underlying etiology and the symptoms of the patient, improving the lesions which should be normally removed by administering heparin.

## Conflict of Interests

Authors have no conflict of interests.

## Acknowledgments

None.

## References

1. Haug V, Linder-Lucht M, Zieger B, Korinthenberg R, Mall V, Mader I. Unilateral venous thalamic infarction in a child mimicking a thalamic tumor. *J Child Neurol* 2009; 24(1): 105-9.
2. Herrmann KA, Sporer B, Yousry TA. Thrombosis of the internal cerebral vein associated with transient unilateral thalamic edema: a case report and review of the literature. *AJNR Am J Neuroradiol* 2004; 25(8): 1351-5.
3. Nijjima Y, Odaka M, Nakamura T, Hirata K. [A case of unilateral thalamic and striatal lesions associated with deep venous thrombosis]. *Brain Nerve* 2010; 62(2): 177-9.
4. Owler BK, Warriar S, Besser M. Traumatic unilateral deep cerebral venous infarction. *J Clin Neurosci* 2004; 11(7): 767-70.
5. Wada Y, Motooka R, Yanagihara C, Nishimura Y. Unilateral thalamic edema associated with deep venous thrombosis. *Internal Medicine* 2012; 51(3): 339-40.
6. Wieshmann NH, Amin S, Hodgson R. A case of unilateral thalamic hemorrhagic infarction as a result of the vein of Galen and straight sinus thrombosis. *J Stroke Cerebrovasc Dis* 2009; 18(1): 28-31.
7. Khealani BA, Wasay M, Saadah M, Sultana E, Mustafa S, Khan FS, et al. Cerebral venous thrombosis: a descriptive multicenter study of patients in Pakistan and Middle East. *Stroke* 2008; 39(10): 2707-11.
8. Wasay M, Bakshi R, Bobustuc G, Kojan S, Sheikh Z, Dai A, et al. Cerebral venous thrombosis: analysis of a multicenter cohort from the United States. *J Stroke Cerebrovasc Dis* 2008; 17(2): 49-54.
9. Saposnik G, Barinagarrementeria F, Brown RD, Bushnell CD, Cucchiara B, Cushman M, et al. Diagnosis and management of cerebral venous thrombosis: a statement for healthcare professionals from the American Heart Association/American Stroke Association. *Stroke* 2011; 42(4): 1158-92.