



Traumatic Herniation of the Buccal Fat Pad



Reza Erfanian¹ , Saeed Shakiba² , Mohammad Sadeq Najafi² , Saeed Sohrabpour^{1*}

1. Otolaryngology Head and Neck Research Center, Tehran University of Medical Sciences, Tehran, Iran.

2. Department of Otolaryngology, School of Medicine, Tehran University of Medical Sciences, Tehran, Iran.

Use your device to scan
and read the article online



Citation Erfanian R, Shakiba S, Sadeq Najafi M, Sohrabpour S. Traumatic Herniation of the Buccal Fat Pad. Case Reports in Clinical Practice. 2019; 4(1):14-16.

Running Title Traumatic BFP Herniation



Article info:

Received: 26 December 2018

Revised: 20 January 2019

Accepted: 12 March 2019

Keywords:

Buccal fat pad; Oral mass;
Traumatic herniation

ABSTRACT

Buccal Fat Pad is an encapsulated mass of adipose tissue located within the buccal facial spaces, between the buccinator and masseter muscles. Intraoral traumatic herniation of Buccal Fat Pad, often seen in young children, has been reported as a rare case. In this report, we present a case of traumatic Buccal Fat Pad herniation which at first was misdiagnosed as a malignant tumor.

Introduction

Intraoral traumatic herniation of the Buccal Fat Pad (BFP) is a rare clinical entity that occurs in young children after facial trauma [1]. The Buccal Fat Pad also called “suckling pad” or “Buccal Fat Pad of Bichat” is one of several encapsulated fat masses in the cheek. In infants and neonates, it

is relatively large and visible on the cheeks of children of different ages [2].

Small perforation of the buccal mucosa and buccinator muscle can allow the Buccal Fat Pad to extend to oral cavity [3]. It is frequently characterized by a pedunculated mass of adipose tissue emanating from the buccal mucosa inside the oral cavity [4]. It is wedged between the buccinator and masseter muscles [5]. The herniated

* Corresponding Author:

Saeed Sohrabpour, PhD.

Address: Otolaryngology, Head and Neck Research Center, Tehran University of Medical Sciences, Tehran, Iran.

E-mail: sohrabpour1364@gmail.com

BFP commonly resembles a tumorous mass in the oral cavity; therefore, it could be misdiagnosed by physicians due to heedless patient workup and history taking [6]. Here we report an unusual case of herniation of Buccal Fat Pad secondary to falling injury in a 4-year-old boy confused for tumor.

Case Presentation

A 4-year-old boy was brought to Amir A'lam Hospital with a complaint of a pedunculated mass on the left buccal mucosa. The approximately 2x2 cm mass had yellowish and necrotic appearance and was well-encapsulated (Figure 1). Computed Tomographic (CT) scan with contrast depicted a defect in the left buccal area with adjacent infiltration and emphysema, including the masseter muscle (Figure 2).

The patient's medical and dental history do not merit full description. Nevertheless, it should be noted that according to the patient's history, he had fallen with a toy in his mouth and after a while, a tumor-like swelling appeared in his mouth. Several doctors claimed it to be a malignant tumor, though the necessary evidential basis for their claim was lacking. Eventually, it was more precisely diagnosed as Buccal Fat Pad herniation, and the patient was transferred to the operation room. Since the mass turned out to be an incarcerated hernia and relocation was not feasible, excision was performed. Meanwhile, the mass was biopsied, and the

specimen was pathologically and histologically analyzed to confirm the composition of adipose tissue.

Discussion

Traumatic Buccal Fat Pad herniation is seen rarely and most often occurs in young children and infants [6]. The typical history demonstrates facial trauma. Perforation of buccinator muscle mainly at the junction of buccinator and masseter is the cause of herniation [7]. Treatment options vary according to the initial injury time. It includes excision or replacement of herniated mass and closure of the wound. To avoid aesthetic deformities, relocation of hernia is strongly recommended if it has just been identified with no sign of inflammation [8].

Buccal fat is a specialized adipose tissue that serves to facilitate masticatory movements and, specifically in infants, the suckling [9]. A minor rupture of buccal mucosa and buccinator muscle results in herniation of the fat into the oral cavity called "pseudolipoma". Herniated BFP is a round and biconvex encapsulated fat mass with its blood supplies coming from three sources: the maxillary, superficial temporal, and facial artery [10].

In case of Buccal Fat Pad herniation, various differential diagnoses must be taken into consideration such as inflammatory hyperplasia, traumatic neuroma, lipoma, hemangioma, salivary neoplasm, pyogenic granuloma, spindle cell proliferation, and necrotic tissue. Herniated BFP might take on different colors; first, it appears as

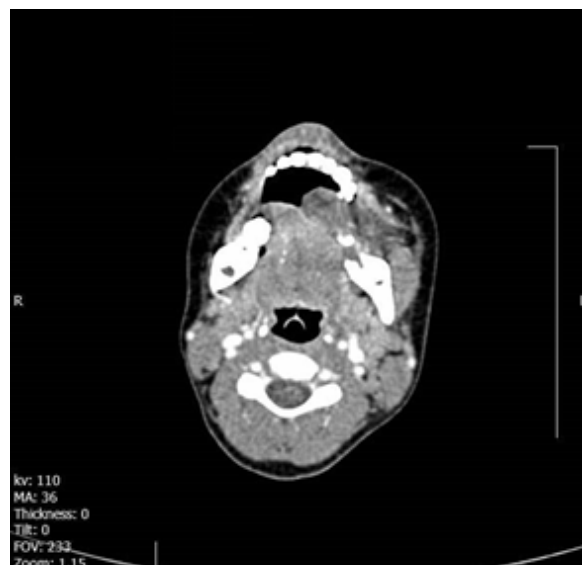
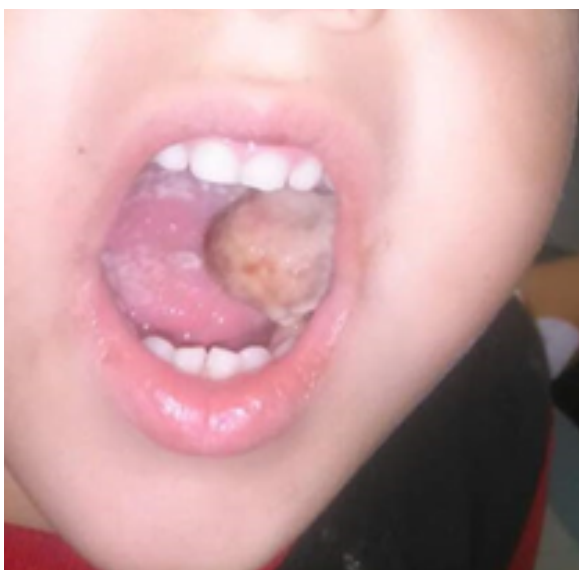

Figure 1. Clinical photograph showing soft tissue mass on left buccal mucosa herniated into the oral cavity

Figure 2. Axial computed tomographic image depicting herniation of the pedunculated homogeneous nonenhanced mass

a yellowish or reddish mass, and after the thrombosis and necrosis, it becomes purple or dark blue. Application of diagnostics such as computed tomographic scan and magnetic resonance imaging will not necessarily lead to the right decision. The key to successful diagnosis is taking a thorough history and clinical examination carried out by skillful physicians. In short, paying attention to a history of facial trauma is essential.

Ethical Considerations

Compliance with ethical guidelines

There was no ethical considerations to be considered in this research.

Funding

This research did not receive any specific grant from funding agencies in the public, commercial, or not-for-profit sectors.

Conflict of interest

The authors declared no conflict of interest.

Acknowledgements

We acknowledge the otolaryngology residents and staff efforts of Amir A'lam Hospital.

References

- [1] Wolford DG, Stapleford RG, Forte RA, Heath M. Traumatic herniation of the Buccal Fat Pad: Report of case. *The Journal of the American Dental Association*. 1981; 103(4):593-4. [DOI:10.14219/jada.archive.1981.0283] [PMID]
- [2] Zhang HM, Yan YP, Qi KM, Wang JQ, Liu ZF. Anatomical structure of the Buccal Fat Pad and its clinical adaptations. *Plastic and Reconstructive Surgery*. 2002; 109(7):2509-18. [DOI:10.1097/00006534-200206000-00052]
- [3] Egyedi P. Utilization of the Buccal Fat Pad for closure of oro-antral and/or oro-nasal communications. *Journal of Maxillofacial Surgery*. 1977; 5:241-4. [DOI:10.1016/S0301-0503(77)80117-3]
- [4] Messenger KL, Cloyd W. Traumatic herniation of the Buccal Fat Pad: Report of a case. *Oral Surgery, Oral Medicine, Oral Pathology*. 1977; 43(1):41-3. [DOI:10.1016/0030-4220(77)90348-6]
- [5] Rohrich RJ, Pessa JE. The fat compartments of the face: Anatomy and clinical implications for cosmetic surgery. *Plastic and Reconstructive Surgery*. 2007; 119(7):2219-27. [DOI:10.1097/01.prs.0000265403.66886.54] [PMID]
- [6] Horie N, Shimoyama PT, Ide PTKDF. Traumatic herniation of the Buccal Fat Pad. *Pediatric Dentistry*. 2001; 23(3):249-52. [PMID]
- [7] Iehara T, Tomoyasu C, Nakajima H, Osamura T, Hosoi H. Traumatic herniation of the Buccal Fat Pad. *Pediatrics International*. 2016; 58(7):613-5. [DOI:10.1111/ped.12852] [PMID]
- [8] Samman N, Cheung L, Tideman H. The Buccal Fat Pad in oral reconstruction. *International Journal of Oral and Maxillofacial Surgery*. 1993; 22(1):2-6. [DOI:10.1016/S0901-5027(05)80346-7]
- [9] Stuzin JM, Wagstrom L, Kawamoto HK, Baker TJ, Wolfe SA. The anatomy and clinical applications of the Buccal Fat Pad. *Plastic and Reconstructive Surgery*. 1990; 85(1):29-37. [DOI:10.1097/00006534-199001000-00006] [PMID]
- [10] Browne WG. Herniation of Buccal Fat Pad. *Oral Surgery, Oral Medicine, Oral Pathology and Oral Radiology*. 1970; 29(2):181-3. [DOI:10.1016/0030-4220(70)90078-2]