



Case Report

Journal Homepage: <http://crp.tums.ac.ir>

Primary Echinococcal Synovitis

Mahnaz Pejman Sani¹ , Mahbube Ebrahimpur¹ , Mahnaz Torki², Neda Alijani^{1,2*}

1. Department of Internal Medicine, Shariati Hospital, Tehran University of Medical Sciences, Tehran, Iran.

2. Department of Infectious Diseases, School of Medicine, Tehran University of Medical Sciences, Tehran, Iran.

**Citation** Pejman Sani M, Ebrahimpur M, Torki M, Alijani N. Primary Echinococcal Synovitis. Case Reports in Clinical Practice. 2019; 4(1):17-19.**Running Title:** Primary Echinococcal Synovitis**Article info:****Received:** 24 December 2018**Revised:** 29 January 2019**Accepted:** 10 March 2019**Keywords:**Hydatid cyst; Synovitis;
Echinococcosis**ABSTRACT**

Hydatid cyst is a parasitic infection caused by the larvae of *Echinococcus granulosus*. We report a rare case of primary echinococcal synovitis in a 37-year-old woman who was referred to our clinic with pain and swelling of the right knee.

Introduction

H ydatid cyst is a common zoonosis disease caused by *Echinococcus granulosus*. It is a serious public health problem in endemic countries such as Iran. This disease produces cystic masses in the organs of the body. The most commonly involved organs are liver and lung (78%). Joint involvement is rare and often occurs secondary to adjacent

bone involvement. We report the rare case of a patient with primary echinococcal synovitis.

Case Presentation

A 37-year-old woman referred to our clinic with the history of right knee pain for 3 years and recent swelling in the last year. He was from Nahavand City and had no significant medical history. On physical examination, she was afebrile; her right knee was swollen, hot, and

* Corresponding Author:

Neda Alijani, MD.**Address:** Department of Internal Medicine, Shariati Hospital, Tehran University of Medical Sciences, Tehran, Iran.**E-mail:** n-alijani@sina.tums.ac.ir

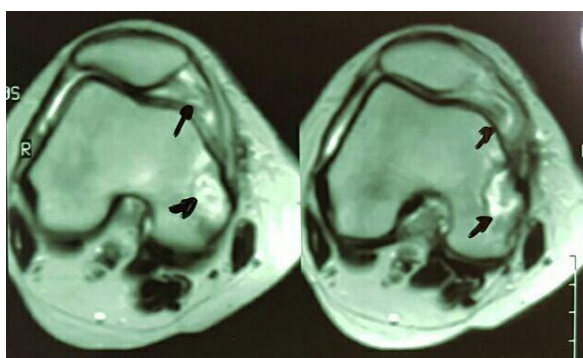


Figure 1. MRI image: a few small round shape lesions in the right popliteal region are mostly due to synovia hydatidosis

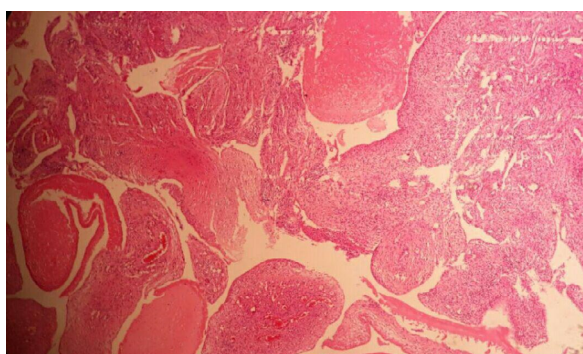


Figure 2. Immunohistochemical studies: proliferating synovial tissue with chronic inflammation and fibrous material compatible with hydatid cyst (H&E staining, 40×)

tender with limited movements. Laboratory findings were as follows; WBC=4000 (normal range of 4500-10000), Hb=11.9 g/dL (gram/deciliter) (normal range of 12-15 g/dL), PLT=156000 (normal range of 150000-450000). Her chest radiography and abdominal sonography results were normal. Magnetic Resonance Imaging (MRI) without gadolinium showed few small round shape lesions in the right popliteal region and lateral recess of the suprapatellar pouch, mostly suggestive of synovia hydatidosis (Figure 1).

Serological tests for echinococcus was positive. The patient underwent the operation and histopathology showed proliferating synovial tissue with chronic inflammation and fibrous material compatible with hydatid cyst (Figure 2). We treated the patient with albendazole and in the follow up her symptoms subsided.

Discussion

Hydatidosis is an endemic disease in Iran. The prevalence of this disease is about 1% of those who underwent an operation in Iran [1]. Bone and joint involve-

ment have been seen in about 1-2% of patients with echinococcosis [2]. Joint involvement often occurs secondary to adjacent bone involvement, but it can be primary and isolated [3].

Over the last 20 years, 44 cases of skeletal hydatid cysts have been reported in Iran. The most common places were in maxillary sinus, mandible, knee, and long bones [4]. In endemic areas, hydatid cyst is one of the differential diagnosis of the cystic lesions based on risk factors [5]. In 50% of the patients, serological tests are negative [6]. Because of the increased risk of infection spread and anaphylactic shock, aspiration of cyst is not recommended [7]. Magnetic resonance imaging and CT scan can be used to diagnose and locate the site of the lesion. Diagnosis is usually delayed until the time of surgery because cysts may remain in the bone or joint for 10-20 years and can be manifested with pain and swelling [7]. Finally, histopathology proves the diagnosis based on the presence of germinal membrane and scolices. Surgical excision is the choice of treatment for the hydatid cyst [7]. The risk of dissemination can be reduced when albendazole is added to treatment [3].

Ethical Considerations

Compliance with ethical guidelines

There were no ethical considerations to be considered in this research

Funding

This research did not receive any specific grant from funding agencies in the public, commercial, or not-for-profit sectors.

Conflict of interest

The authors declared no conflict of interest.

References

- [1] Battyany I, Levai A, Nagy KK. Subcutaneous hydatid cyst in the popliteal fossa at the site of a previous wasp sting. *Diagnostic and Interventional Radiology*. 2011; 17(2):163-5. [DOI:10.4261/1305-3825.DIR.2933-09.1] [PMID]
- [2] Chevalier X, Rhamouni A, Bretagne S, Martigny J, Larget-Piet B. Hydatid cyst of the subcutaneous tissue without other involvement: MR imaging features. *American Journal of Roentgenology*. 1994; 163(3):645-6. [DOI:10.2214/ajr.163.3.8079861] [PMID]

- [3] Belzunegui J, Maiz O, Lopez L, Plazaola I, Gonzalez C, Figueroa M. Hydatid disease of bone with adjacent joint involvement. A radiological follow-up of 12 years. *British Journal of Rheumatology*. 1997; 36(1):133-5. [DOI:10.1093/rheumatology/36.1.133] [PMID]
- [4] Geramizadeh B. Unusual locations of the hydatid cyst: A review from Iran. *Iranian Journal of Medical Sciences*. 2013; 38(1):2-14. [PMID] [PMCID]
- [5] Guiral J, Rodrigo A, Tello E. Subcutaneous echinococcosis of the knee. *The Lancet*. 2004; 363(9402):38. [DOI:10.1016/S0140-6736(03)15168-9]
- [6] Hossein G, Mehdi M, Mahsa G, Kavous F, Marzieh M, AmirHossein J. Hydatid cyst of the knee: A case report. *Iranian Journal of Radiology*. 2011; 2011(3):170-2. [DOI:10.5812/kmp.iranjradiol.17351065.3162]
- [7] Poyanli A, Akan K, Poyanli O, Sencer S, Sayrak H. Primary hydatid disease of the femur: Unsuspected and incidental MRI findings with long-term curative results on medical treatment alone. *Skeletal Radiology*. 2001; 30(11):656-8. [DOI:10.1007/s002560100393] [PMID]