



## Case Report

Journal Homepage: <http://crp.tums.ac.ir>

# Caroli Syndrome in a Child: A Case Report

Pantea Tajik<sup>1</sup> , Amir Hossein Goudarzian<sup>2\*</sup>

1. Department of Pediatric Gastroenterology, School of Medicine Semnan University of Medical Sciences, Semnan, Iran.
2. Student Research Committee, Mazandaran University of Medical Sciences, Sari, Iran.

**Citation:** Tajik P, Goudarzian AH. Caroli Syndrome in a Child: A Case Report. Case Reports in Clinical Practice .2019; 4(3):89-93.**Running Title:** Caroli Syndrome in a Child**Article info:****Received:** 24 June 2019**Revised:** 08 August 2019**Accepted:** 19 September 2019**Keywords:**Caroli syndrome; Child;  
Case report**ABSTRACT**

**Introduction:** Caroli syndrome is a congenital disorder characterized by multiple segmental or saccular dilatations of the intrahepatic bile ducts associated with congenital hepatic fibrosis.

**Case Presentation:** A 3-year-old boy with abdominal distention was referred to gastroenterology ward of Amiralmomenin hospital (Semnan, Iran) in summer 2018. In his abdominal sonography, multiple cysts were detected in the liver with hepatomegaly, and the portal vein pressure was 10 mm. Also, in liver biopsy, dilated portal bile ducts (trichrome stain) with inspissated bile and congenital hepatic fibrosis were reported. He was discharged after conservative therapy and followed up.

**Conclusion:** Definitive treatment, i.e surgery, should be offered to prevent future complications.

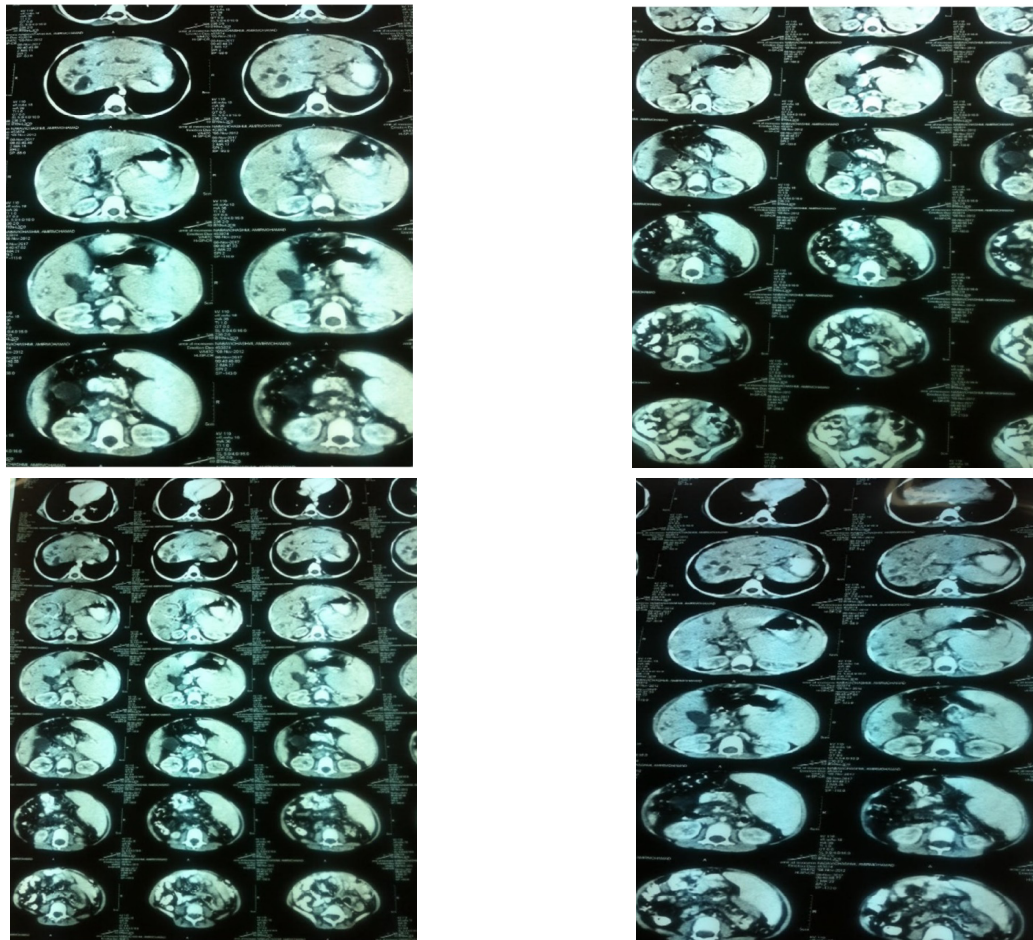
**Introduction**

**C**aroli syndrome is a congenital disorder characterized by multiple segmental or saccular dilatations of the intrahepatic bile ducts associated with congenital hepatic fibrosis. The term congenital fibrosis refers to unique congenital liver histology characterized by bland portal fibrosis, hyperplasia of interlobular bile ducts within the portal

areas with variable shapes and sizes of bile ducts, and preservation of the normal lobular architecture [1-3]. There are two patterns of Caroli syndrome: The second form is more diffuse, and when associated with portal hypertension and congenital hepatic fibrosis, is often referred to as Caroli syndrome [4, 5].

The clinical features of Caroli disease are a combination of Caroli syndrome (bile stasis, recurrent bouts of cholangitis, hepatolithiasis, gallbladder stones, and in-

**\* Corresponding Author:****Amir Hossein Goudarzian, MSc.****Address:** Student Research Committee, Mazandaran University of Medical Sciences, Sari, Iran.**E-mail:** [amir\\_sari@yahoo.com](mailto:amir_sari@yahoo.com)



**Figure 1.** Abdominal CT scan with liver cysts and dilation of intrahepatic biliary tract



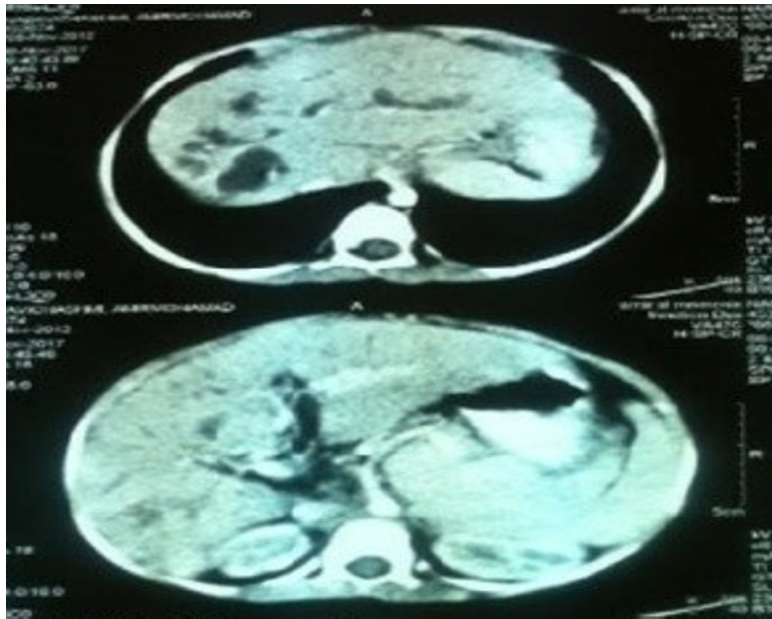
creased risk of cholangiocarcinoma) and those of congenital hepatic fibrosis (including portal hypertension and variceal bleeding) [5]. The symptoms may develop early or late in life. Consequences of congenital hepatic fibrosis like portal hypertension appear later in the disease process, indicating that Caroli syndrome has a progressive course [1]. The complications of portal hypertension include ascites and esophageal varices which may present with hematemesis and melena. Patients may present with intermittent abdominal pain and pruritus associated with hyperbilirubinemia [2]. According to some studies, Caroli syndrome may be associated with recessive polycystic kidney disease [6].

Laboratory analysis may include alanine aminotransferase, alkaline phosphatase, and bilirubin elevations, thrombocytopenia, and leukopenia if portal hypertension and hypersplenism are present [2]. The treatment of complications associated with Caroli syndrome involves the use of medical, endoscopic, and surgical modalities. Indications for resection were the failure of conservative therapy, suspected malignancy, or symp-

oms associated with cardiac heart failure, and chronic hepatic fibrosis [3]. Surgical modalities include left lateral sectionectomy, left and right hepatectomy in monobar disease and cholecystectomy, intrahepatic bile duct exploration with multiple stone removal, liver biopsy, and end-to-side Roux-en-Y hepaticojejunostomy with stent drainage in bilobar condition [3]. Medical management involves the use of antibiotics for acute cholangitis. Ursodeoxycholic acid is used in chronic cholestasis to decrease bile stasis and increase bile flow and in some cases is associated with dissolution of bile duct stones [7]. In the present study, we present a three-year-old boy with abdominal distention (due to hepatosplenomegaly) who was referred to our hospital.

### Case Presentation

Our case was a three-year-old boy with normal growth according to the CDC (clinical growth charts) (weight, height, and the head circumference were 12kg, 91 cm and 52cm, respectively). His weight-for-length percentiles and head circumference-for-age



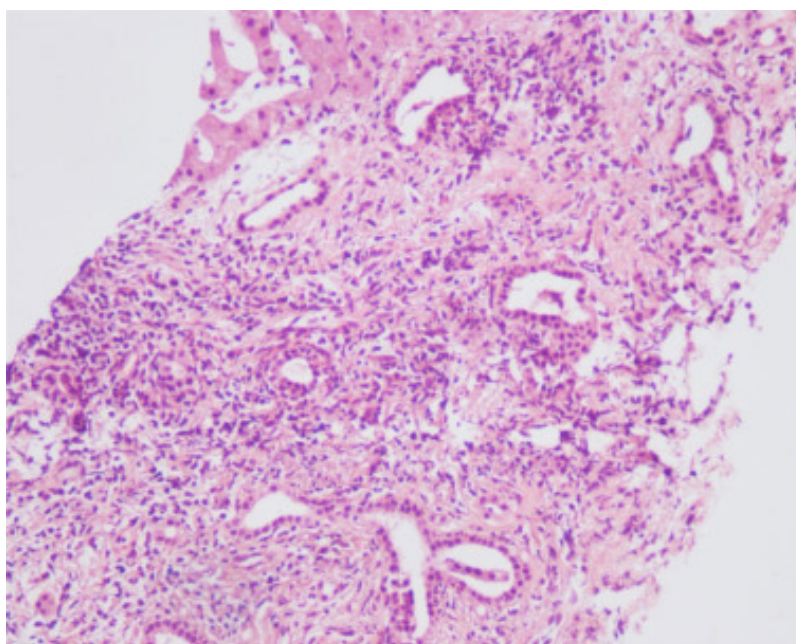
**Figure 2.** Liver CT scan with intrahepatic dilation of the bile duct in our patient



percentiles, length-for-age percentiles and weight-for-age percentiles were normal too. He was referred with abdominal distention to the hospital, so after taking his medical history, we found hepatosplenomegaly in his physical examination. The liver span was 14cm and left lobe was huge and firm, and the spleen was one cm under the rib.

Laboratory data were normal (white blood cell count: 6500cmm, hemoglobin: 13g/dl, platelets: 260000MI,

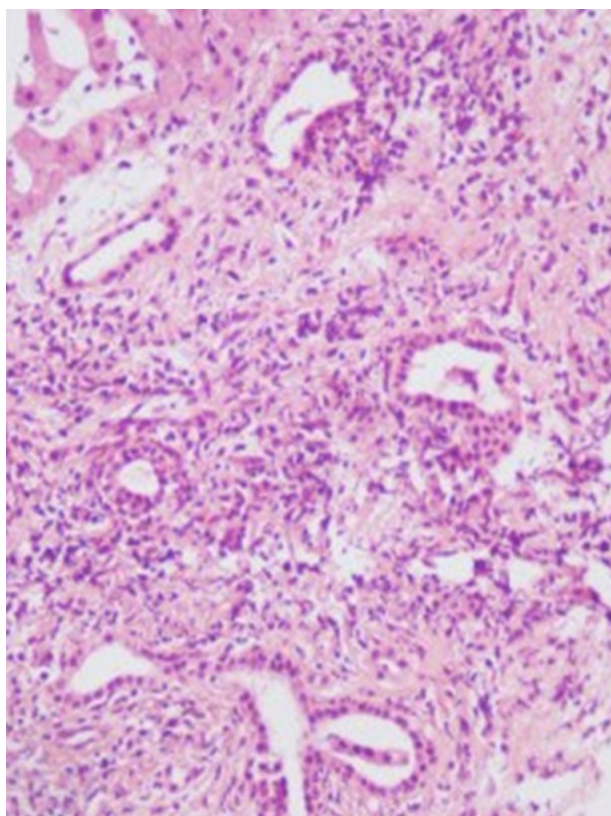
aspartate aminotransferase: 25IU/L, alanine aminotransferase: 30IU/L, anaplastic lymphoma kinase: 550IU/L). Also, prothrombin time, partial thromboplastin time, urine analysis, urine culture, and international normalized ratio were normal. Toxoplasmosis, other agents, rubella, cytomegalovirus, and herpes simplex virus (TORCH) study, viral marker hepatitis, thyroid function tests, B/C, and metabolic study were normal. Also, his bilirubin (total=1mg/dL, direct=0.3mg/dL),



**Figure 3.** Dilation of the intrahepatic biliary tract (liver biopsy)







**Figure 4.** Dilation of the intrahepatic bile duct in our patient



blood urea nitrogen (18), and creatinine (0.5mg/dL) were within the normal range.

In his abdominal sonography, multiple cysts were detected in the liver with hepatomegaly, and the portal ven was 10 mm. The small portal venous branches were surrounded wholly or partially by dilated bile ducts, so the abdominal spiral CT-scan with contrast was done. Sonogram pictures of kidneys were normal. In abdominal CT-scan, multiple cysts were seen in the liver with dilation intrahepatic biliary tract. Multiple hypodense rounded areas which are inseparable from the dilated intrahepatic bile ducts. A very important sign is the central dot sign. The central dot corresponds to the portal vein that is surrounded by dilated bile ducts. (Figure 1).

After abdominal sonography and CT-scan, the liver biopsy was done under the sonography guide. In the liver biopsy, dilated portal bile ducts (trichrome stain), with inspissated bile and congenital hepatic fibrosis was reported. In upper endoscopy, no varice was seen. Other organs were normal. So the boy was diagnosed with Caroli syndrome and was discharged after conservative therapy and followed up (Figures 2, 3 and 4).

## Discussion

Caroli syndrome can present at any age. It is typically found in Asia and diagnosed in persons under the age of 22. Cases have also been found in infants and adults. As medical imaging technology improves, diagnostic age decreases [8]. Caroli syndrome ranges from simple ectasia of the larger intrahepatic bile ducts (in this less common form the name Caroli syndrome is used) to a syndromic form (Caroli syndrome) that is more common and includes congenital hepatic fibrosis [3]. Its manifestations are those of its complications, mostly bacterial cholangitis, and include abdominal pain, biliary colic, fever, chills, and jaundice. Hepatomegaly, cirrhosis, and portal hypertension (with splenomegaly) are also frequently reported. Besides bacterial cholangitis, complications include liver abscess, biliary infection, and in late stages, cholangiocarcinoma. Images taken by CT scan, X-ray, or MRI show enlarged intrahepatic (in the liver) bile ducts due to ectasia [2, 9]. Using an ultrasound, tubular dilation of the bile ducts can be seen. On CT-scan, Caroli syndrome can be suspected by noting the many fluid-filled, tubular structures extending to the liver [1]. A high-contrast CT must be used to distinguish between stones and widened ducts. Bowel gas and digestive habits make it difficult to obtain a clear sonogram, so a CT

scan is a good substitute. When the intrahepatic bile duct wall has protrusions, it is seen as central dots or a linear streak [10]. The differential diagnosis should include primary sclerosing cholangitis, isolated polycystic liver disease, and hepatic cystic hamartoma, as well as hepatic and choledochal cysts [8].

Cases of prenatal diagnosis based on ultrasonographic findings have also been reported. Most cases of syndromic cases are sporadic. Syndromic cases share with congenital hepatic fibrosis and recessive polycystic kidney disease an autosomal recessive transmission [3, 10]. Management depends on the clinical presentation, localization, and stage of the disease. Ursodeoxycholic acid may be used to prevent stone formation. Antibiotics are used for cholangitis. Radiological, endoscopic, and surgical intervention may be required for patients with biliary obstruction, abscess formation, and liver or bile duct stones [2]. Patients with severe disease may be candidates for liver transplantation. Quality of life may be significantly affected by recurrent cholangitis. Prognosis depends on the clinical course and the risk of cholangiocarcinoma [4].

## Conclusion

Caroli's syndrome, also known as communicating cavernous ectasia of the intrahepatic ducts, is a rare congenital disorder characterized by non-obstructive multiple cystic dilatation of the intrahepatic bile ducts. In about 50% of the patients, there may be dilatation of the extrahepatic bile ducts as well. Management- For the isolated form of Caroli's disease limited to a lobe, hepatectomy is the curative option. In the diffuse form treatment options include conservative or endoscopic therapy, internal biliary bypass procedures and liver transplantation in carefully selected cases.

## Ethical Considerations

### Compliance with ethical guidelines

All study procedures were performed following the 1964 Declaration of Helsinki and its later amendments.

### Funding

This research did not receive any specific grant from funding agencies in the public, commercial, or not-for-profit sectors.

## Conflict of interest

All authors declare no conflict of interest.

## References

- [1] Kadakia N, Lobritto SJ, Ovchinsky N, Remotti HE, Yamashiro DJ, Emond JC, et al. A challenging case of hepatoblastoma concomitant with autosomal recessive polycystic kidney disease and caroli syndrome-review of the literature. *Frontiers in Pediatrics* 2017; 5:114. [DOI:10.3389/fped.2017.00114] [PMID] [PMCID]
- [2] Yang XY, Zhu LP, Liu XQ, Zhang CY, Yao Y, Wu Y. [Genetic diagnosis of Caroli syndrome with autosomal recessive polycystic kidney disease: A case report and literature review (Chinese)]. *Beijing da xue xue bao Yi xue ban=Journal of Peking University (Health Sciences)*. 2018; 50(2):335-9. [PMID]
- [3] Lendoire J, Barros Schelotto P, Alvarez Rodríguez J, Duek F, Quarin C, Garay V, et al. Bile duct cyst type V (Caroli's disease): Surgical strategy and results. *HPB Journal*. 2007; 9(4):281-4. [DOI:10.1080/13651820701329258] [PMID] [PMCID]
- [4] Fahrner R, Dennler SGC, Dondorf F, Ardelt M, Rauchfuss F, Settmacher U. Liver resection and transplantation in Caroli disease and syndrome. *Journal of Visceral Surgery*. 2018; 156(2):91-5. [DOI:10.1016/j.jvisc.2018.06.001] [PMID]
- [5] Perricone G, Vanzulli A. Education and imaging. *Hepatology: "Central dot sign" of Caroli syndrome*. 2015; 30(2):234. [DOI:10.1111/jgh.12828] [PMID]
- [6] Kim JT, Hur YJ, Park JM, Kim MJ, Park YN, Lee JS. Caroli's syndrome with autosomal recessive polycystic kidney disease in a two month old infant. *Yonsei Medical Journal*. 2006; 47(1):131-4. [DOI:10.3349/ymj.2006.47.1.131] [PMID] [PMCID]
- [7] Zidan A, Bauschke A, Scheuerlein H, Settmacher U, Rauchfuss F. Re-resection of remnant Caroli syndrome six years after the first resection (case report). *International Journal of Surgery Open*. 2016; 3:8-10. [DOI:10.1016/j.ijso.2016.04.004]
- [8] Gu DH, Park MS, Jung CH, Yoo YJ, Cho JY, Lee YH, et al. Caroli's disease misdiagnosed as intraductal papillary neoplasm of the bile duct. *Clinical and Molecular Hepatology*. 2015; 21(2):175-9. [DOI:10.3350/cmh.2015.21.2.175] [PMID] [PMCID]
- [9] Ananthakrishnan AN, Saeian K. Caroli's disease: Identification and treatment strategy. *Current Gastroenterology Reports*. 2007; 9(2):151-5. [DOI:10.1007/s11894-007-0010-7] [PMID]
- [10] Srivastava G, Raju U, Sherwani P, Kumar M, Gupta D. Caroli's disease: An unusually early presentation. *International Journal of Medical Paediatrics and Oncology*. 2016; 2:173-6.