



## Case Report

Journal Homepage: <http://crp.tums.ac.ir>

## Tracheobronchopathia Osteochondroplastica: A Case Report

Salar Khazani Fard<sup>1\*</sup>, Fathemeh Aghaeimeybodi<sup>2</sup>

1. Resident of Internal Medicine, Department of Internal Medicine, Faculty of Medicine, Shahid Sadoughi University of Medical Sciences, Yazd, Iran.
2. Assistant Professor, Department of Internal Medicine, Faculty of Medicine, Shahid Sadoughi University of Medical Sciences, Yazd, Iran.

Use your device to scan and read the article online

**Citation:** Khazani Fard S, Aghaeimeybodi F. Tracheobronchopathia Osteochondroplastica: A Case Report. Case Reports in Clinical Practice. 2020; 5(1):1-4.**Running Title:** Tracheobronchopathia Osteochondroplastica**Article info:****Received:** 10 January 2020**Revised:** 19 February 2020**Accepted:** 05 March 2020**Keywords:**Tracheobronchopathia  
Osteochondroplastica; Dyspnea;  
Cough; Hoarseness**ABSTRACT****Introduction:** Tracheobronchopathia Osteochondroplastica (TPO) is a rare disease that is characterized by bony canals located on the cartilage ring. We here report one case of tracheobronchopathia osteochondroplastica.**Case Report:** A 64-year-old female patient was admitted to the hospital with a productive cough, sputum, and fever for ten days. Her chest CT scan showed mild thickening and irregularity associated with calcification in the trachea wall and main bronchus. The patient had rheumatoid arthritis, and after consultation with a rheumatologist, she received pneumonia treatment and then underwent bronchoscopy.**Conclusion:** TPO is a rare, benign disease with slow progression. Physicians should be aware of TPO and should consider it in patients with chronic cough and respiratory infections.**Introduction**

**T**racheobronchopathia Osteochondroplastica (TPO) is a non-malignant idiopathic disease that affects large airways. TPO is characterized by bony diffuse or focal canals located on the cartilage ring. Nodules in the anterior and lateral walls sometimes penetrate the main bronchus, even rarer to the larynx [1]. In some cases, the densely calcified glucose nodule breaches the

tracheal lumen [2]. However, most TPO patients were asymptomatic throughout life. The relapses of chronic pneumonia with exacerbation of airway obstruction may appear with symptoms such as dyspnea, hoarseness, persistent and productive cough, and hemoptysis [3, 4]. Wiki first described TPO in 1867 [5]. About 400 cases have been reported all around the world. In this article, one case of TPO is reported.

\*Corresponding Author:

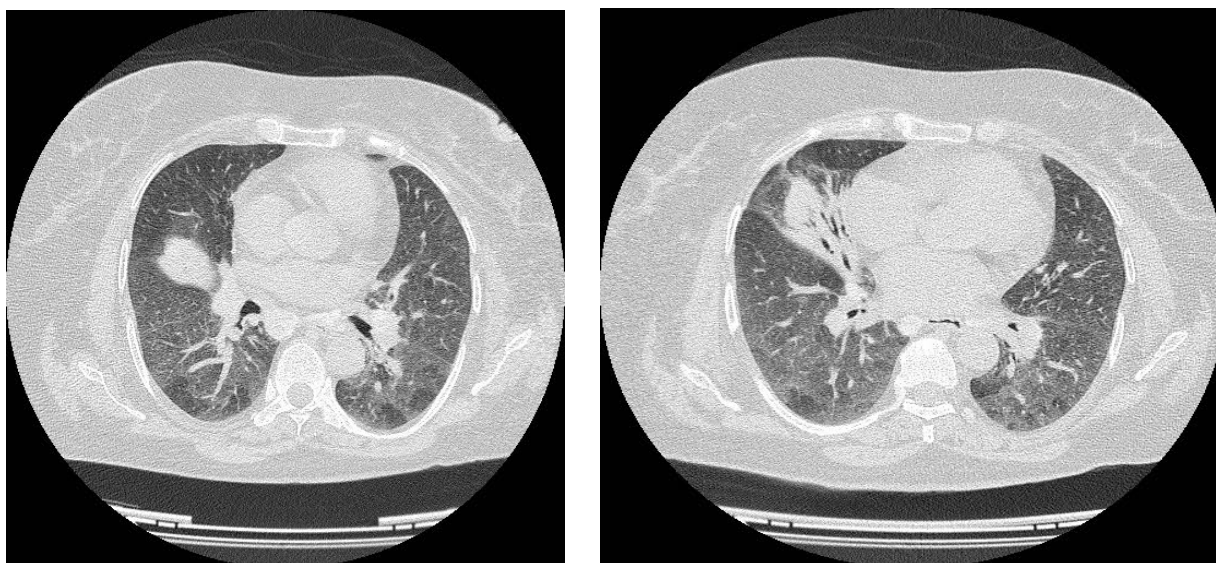
**Salar Khazani Fard, MD.****Address:** Resident of Internal Medicine, Department of Internal Medicine, Faculty of Medicine, Shahid Sadoughi University of Medical Sciences, Yazd, Iran.**E-mail:** saliyazdmed@gmail.com

## Case Report

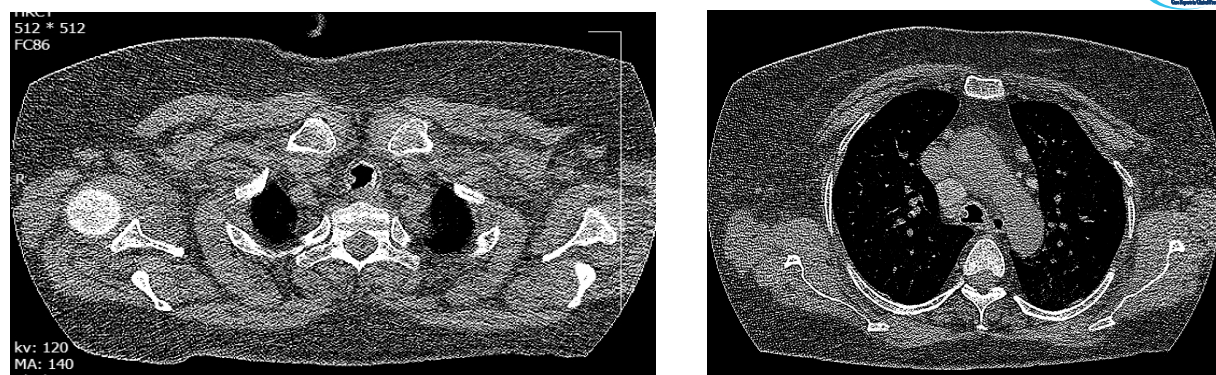
A 64-year-old female was admitted to the hospital with a productive cough, sputum, and fever for ten days. The patient had a history of heart failure and angiography, although she baked bread and wove carpets in the past. There was no such history as hemoptysis, past medical history, paroxysmal nocturnal dyspnea, or other pulmonary problems. The remainder of the history was unremarkable. On physical examination, crackle was heard in the right lung. A chest CT scan showed mild thickening and irregularity associated with calcification in the trachea wall and the main bronchus (Figure 1). The cause of pneumonia was the relative stenosis of right middle lobe lumen bronchus with one of the nodules, and bilateral peribronchovascular and interlobular septal thickening have been seen (Figure 2). The culture

of bronchoalveolar lavage in the patient was *Klebsiella* susceptible to levofloxacin.

Bronchoscopy showed nodularity in the trachea, and in the Right Middle Lobe (RML), laser photoablation was done (Figure 3). In the bronchial biopsy, moderate inflammatory cells were seen with infiltration of lamina propria composed of plasmacytes and eosinophils, and the surface epithelium reveals benign squamous metaplasia (Figure 4). Also, the patient had rheumatoid arthritis, so we consulted with a rheumatologist. The patient received pneumonia treatment and underwent bronchoscopy.



**Figure 1.** Chest CT scan (mediastinal view): Mild thickening and irregularity association with calcification in trachea wall and main bronchus



**Figure 2.** Chest CT scan: Stenosis of Right Middle Lobe (RML) lumen bronchus with one of the nodules and bilateral peribronchovascular and interlobular septal thickening and air bronchogram in RML.

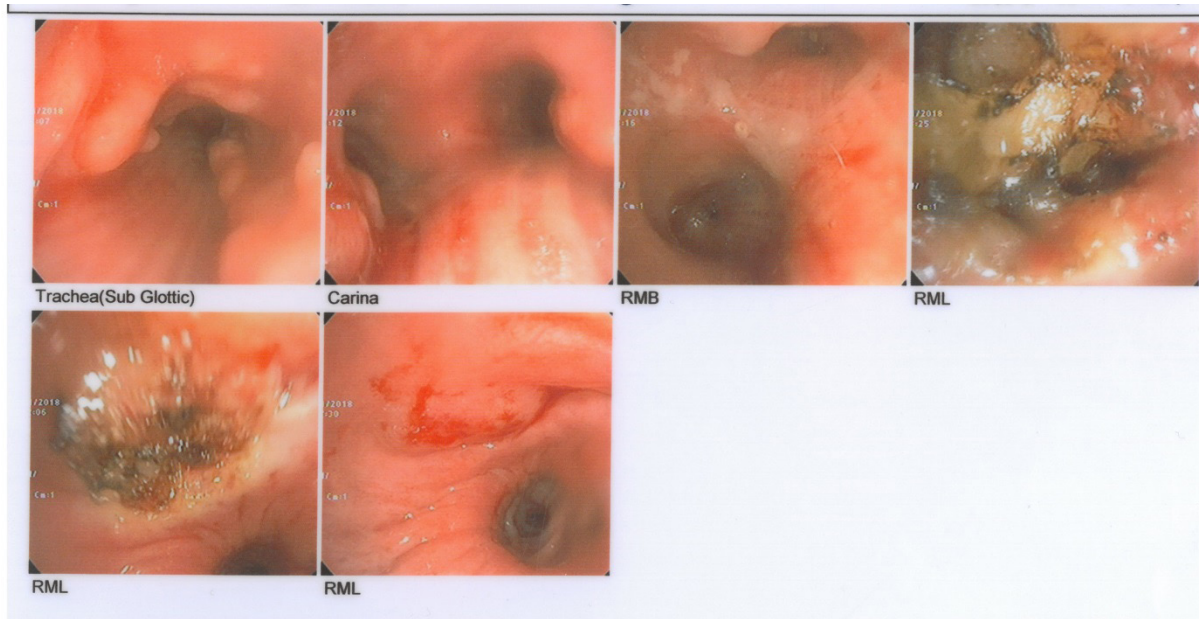


Figure 3. Bronchoscopy images of the patient



## Discussion

TPO is an unusual disorder of the cartilaginous tracheal wall, and its incidence is unknown. TPO is significantly more serious than we previously considered. The risk of TPO in men is three times higher than women [6] and is usually diagnosed in the sixth or seventh decade of life, except in one case that was detected in a 9-year-old child [7]. In a study that examined bronchoscopy in 8760 patients aged 6 years and older, 10 cases of TPO were diagnosed, and their average age was 51 years, and most of them were male [6]. Chronic infection, congenital anomaly, chemical or mechanical irritation, de-

generative or metabolic abnormalities, and genetic predisposition are all factors that can lead to developing TPO [8]. However, the exact cause of TPO is unknown.

As we know, the TPO is limited to the trachea and main bronchi but does not include the lungs and other organs. Changes in mucosal surfaces and secretions lead to the recurrence of inflammation and infection. The main complaints are chronic cough and hemoptysis, even dyspnea, and wheezing is occasional [9].

TPO detection is mainly based on the CT scan, bronchoscopy, and histopathologic examination. Computed

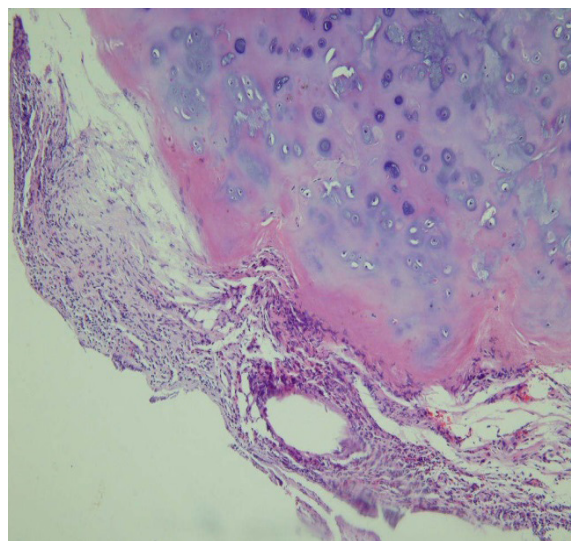


Figure 4. Pathology of bronchial biopsy



tomography of the chest shows irregular thickening and calcified abnormalities that reach the lumen of tracheo-bronchial. Nodules commonly emerge from the anterior and lateral sides of the inner tracheal wall. Although these lesions may extend from anywhere into the larynx and the peripheral bronchus, they are usually seen in the distal two-thirds of the chest and proximal bronchi. Because these nodes are formed from the cartilage, the chamber's membrane wall is typically disconnected. This separation is essential for distinguishing other diseases, such as diabetes, tracheobronchial amyloidosis, and Wegener granulomatosis disease [10].

Bronchoscopy is the most common diagnostic tool for this disease. The nodes are hard and show with gritty sensation while the scope is passing through the lumen [11]. The tissue, usually exhibits osseocartilaginous changes with normal epithelium, while cartilage and bone tissue intervening bone marrow [12]. Amyloidosis, endobronchial sarcoidosis, tuberculosis, papillomatous, bronchial, and tracheal tumors should be considered as a differential diagnosis for TPO [13].

Treatment is rarely needed, except in patients with severe airway obstruction and debilitating symptoms. The purpose of conservative treatment is maintaining air humidity, controlling infection, and avoiding air disinfection agents [8, 14]. The optimal treatment is still controversial.

## Ethical Considerations

### Compliance with ethical guidelines

All ethical principles were considered in this article.

### Funding

This research did not receive any specific grant from funding agencies in the public, commercial, or not-for-profit sectors.

### Conflict of interest

The authors declared no conflict of interest.

## References

[1] Abu-Hijleh M, Lee D, Braman SS. Tracheobronchopathia osteochondroplastica: A rare large airway disorder. *Lung*. 2008; 186:353-9. [PMID]

[2] Chien YC, Wang HC, Chang YC, Chen YF. Uncommon chronic cough caused by tracheobronchopathia osteochondroplastica. *Thorax*. 2012; 67(11):1021-2. [DOI:10.1136/thoraxjnl-2011-200861] [PMID]

[3] Bergeron D, Cormier Y, Desmeules M. Tracheobronchopathia osteochondroplastica. *American Review of Respiratory Disease*. 1976; 114(4):803-6. <https://www.atsjournals.org/doi/abs/10.1164/arrd.1976.114.4.803>

[4] Zack JR, Rozenshtein A. Tracheobronchopathia osteochondroplastica: Report of three cases. *Journal of Computer Assisted Tomography*. 2002; 26(1):33-6. [DOI:10.1097/00004728-200201000-00006] [PMID]

[5] Wilks S. Ossific deposit on the larynx, trachea and bronchi. *Transactions Pathological Society of London*. 1857; 8:88. <https://ci.nii.ac.jp/naid/10013600694/>

[6] Jabbaridarjani HR, Radpey B, Kharabian Sh, Masjedi MR. Tracheobronchopathia osteochondroplastica: Presentation of ten cases and review of the literature. *Lung*. 2008; 186:293. [DOI:10.1007/s00408-008-9088-4] [PMID]

[7] Simsek PO, Ozelik U, Demirkazik F, Unal OF, Orhan D, Aslan AT, et al. Tracheobronchopathia osteochondroplastica in a 9-year-old girl. *Pediatric Pulmonology*. 2006; 41(1):95-7. [DOI:10.1002/ppul.20311] [PMID]

[8] Prakash UBS. Tracheobronchopathia osteochondroplastica. *Seminars in Respiratory and Critical Care Medicine*. 2002; 23(2):167-76. [DOI:10.1055/s-2002-25305] [PMID]

[9] Raess PW, Cowan SW, Haas AR, Zhang PJ, Litzky LA, Miller Jr WT, et al., Tracheobronchopathia osteochondroplastica presenting as a single dominant tracheal mass. *Annals of Diagnostic Pathology*. 2011; 15(6):431-5. [DOI:10.1016/j.anndiagpath.2011.04.009] [PMID]

[10] Matsuba T, Andoh K, Hirota N, Hara N. CT diagnosis of tracheobronchopathia osteochondroplastica. *Respiration*. 2001; 68:200. [DOI:10.1159/000050492] [PMID]

[11] Thakur A, Yang T, Chen T, Rana N, Zhu B, Wei X, et al. Atypical presentation of tracheobronchopathia osteochondroplastica: Is chronic inflammation a perpetrator? *Medical Principles and Practice*. 2013; 22(5):503-5. [DOI:10.1159/000346662] [PMID] [PMCID]

[12] Al-Busaidi N, Dhuliya D, Habibullah Z. Tracheobronchopathia osteochondroplastica: Case report and literature review. *Sultan Qaboos University Medical Journal*. 2012; 12(1):109-12. [DOI:10.12816/0003096] [PMID] [PMCID]

[13] Jindal Sh, Nath A, Neyaz Z, Jaiswal S. Tracheobronchopathia osteochondroplastica - a rare or an overlooked entity? *Journal of Radiology Case Reports*. 2013; 7(3):16-25. [DOI:10.3941/jrcr.v7i3.1305] [PMID] [PMCID]

[14] Tatar D, Senol G, Demir A, Polat G. Tracheobronchopathia osteochondroplastica: Four cases. *Chinese Medical Journal*. 2012; 125(16):2942-4. [PMID]