



## Case Report

Journal Homepage: <http://crp.tums.ac.ir>

# Congenital Deformity of the Knee Joint: A Boy With Congenital Patella Alta



Ramin Haj Zargarbashi<sup>1</sup>, Saeed Shakiba<sup>2</sup>, Farbod Yousefi<sup>2</sup>, Mohammad Hossein Nabian<sup>1</sup>, Behnam Panjavi<sup>\*</sup>

1. Department of Orthopedics and Trauma Surgery, Children's Medical Center Hospital, Tehran University of Medical Sciences, Tehran, Iran.
2. Department of Orthopedics and Trauma Surgery, School of Medicine, Tehran University of Medical Sciences, Tehran, Iran.



**Citation:** Haj Zargarbashi R, Shakiba S, Yousefi F, Nabian MH, Panjavi B. Congenital Deformity of the Knee Joint: A Boy With Congenital Patella Alta. Case Reports in Clinical Practice. 2020; 5(1):5-10.

**Running Title:** Congenital Deformity of the Knee Joint



## Article info:

**Received:** 05 January 2020

**Revised:** 11 February 2020

**Accepted:** 25 March 2020

## Keywords:

Congenital patella alta; Open reduction; Operative treatment

## ABSTRACT

**Introduction:** Patella alta is an extremely rare condition, refers to an abnormally high position of the patella. Surgical treatment of habitual dislocation of the patella aims at a step-by-step correction of the abnormality.

**Case Presentation:** A 4-year-old boy presented with a rare superior dislocation of the patella. Clinical examination and radiographs confirmed the dislocation of the patella. The patella was reduced with proper reduction technique under sedation, resulting in the improvement of active range of motion.

**Conclusion:** Congenital patella alta is a rare deformity in children. Treatment and diagnosis in the early stages are of our priority in the treatment. Our non-surgical treatment is our preferred treatment in this patient. The surgical treatment approach is performed in patients that have no response to non-surgical treatments.

## Introduction

Congenital patella alta is a rare condition, with few cases being reported in the literature [1-4]. Although the history, physical examination, and radiographic findings have

been reported to be characteristic [4], the correct diagnosis can be quite elusive in unusual cases.

## Case Presentation

A 4-year-old boy presented with congenital flexion contracture of the left knee because of a mass at the

\* Corresponding Author:

**Behnam Panjavi, PhD.**

**Address:** Department of Orthopedics and Trauma Surgery, Children's Medical Center Hospital, Tehran University of Medical Sciences, Tehran, Iran.

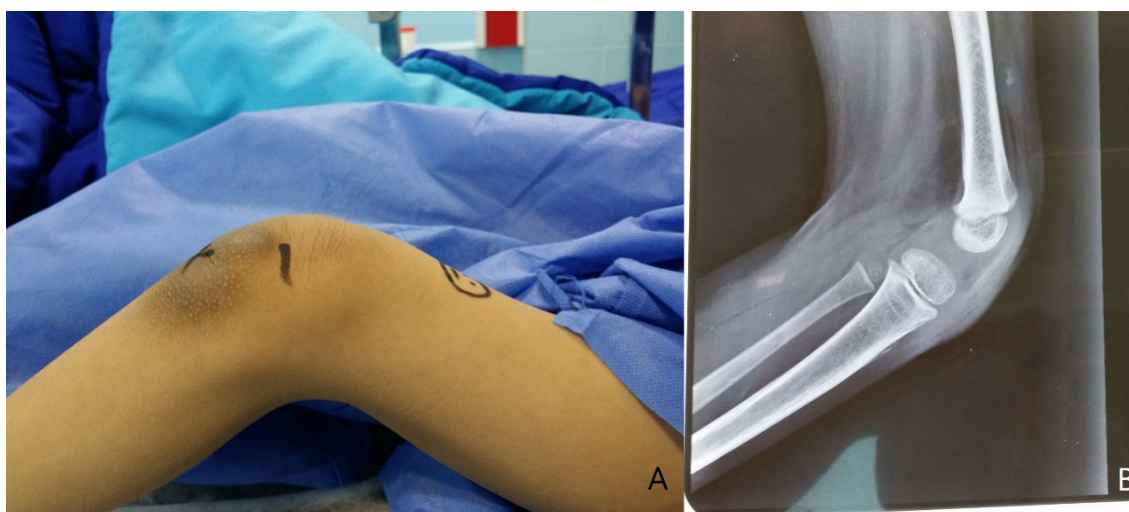
**E-mail:** [dr.behnam.panjavi.md@gmail.com](mailto:dr.behnam.panjavi.md@gmail.com)

anterior aspect of the thigh. He was initially diagnosed with a tumoral lesion. The patient was unable to walk because of severe knee flexion contracture (Figure 1A).

A mass with a bony consistency was palpable at the anterior aspect of the middle thigh, with no pain or tenderness. We could not manage to visualize the patella on the anteroposterior and lateral knee x-ray studies. However, further radiographic studies of the femur revealed a high-riding hypoplastic patella at the level where it was initially misdiagnosed as a mass lesion. The patella was irreducible. The patient had been gone through a series of long-term physiotherapies with little benefit. His musculoskeletal physical examination was normal except for the non-assessable force of quadriceps and quadriceps contracture. His cardiopulmonary, gastrointestinal, and genitourinary examination were all normal. The patient was intellectually sound normal on a neurological consult.

The Insall-Salvati ratio (patellar tendon length/ patellar length) is a method of determining the position of the patella by radiography and a widely used index, which is relatively independent of the knee flexion. It was 2.7 in our patient (normal range: 0.8-1.2) [5] (Figure 1B). This deformity, besides the functional impairment, had no response to non-pharmacological treatment, so we decided to perform surgery for treating deformity.

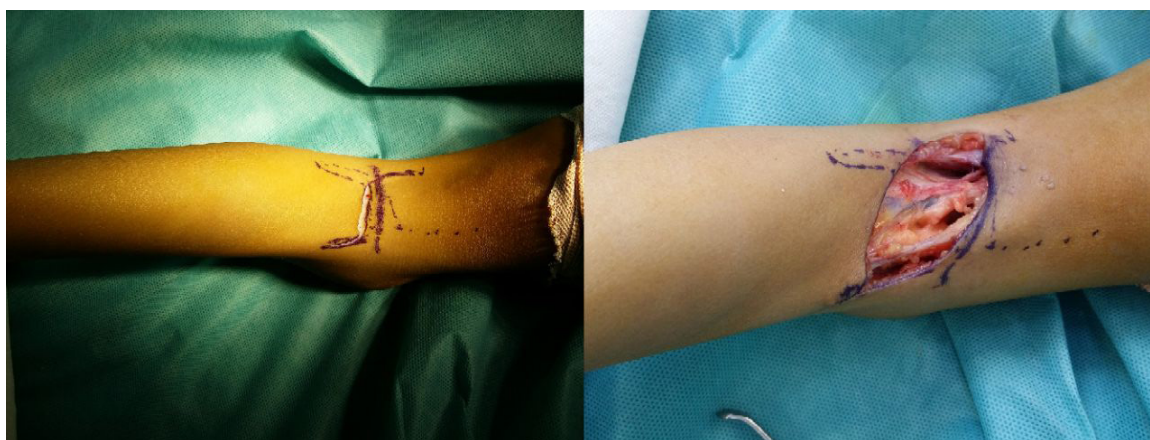After general endotracheal anesthesia, the patient was placed in a prone position on the operation table. A tourniquet was applied to the left thigh. After the patient was prepped and draped, a lazy S-shaped incision was made between two heads of gastrocnemius muscles. Skin and the superficial fascia were opened to expose the posterior aspect of the knee joint and corresponding neurovascular components (Figure 2).



**Figure 1.** A 4-year-old boy with congenital flexion contracture

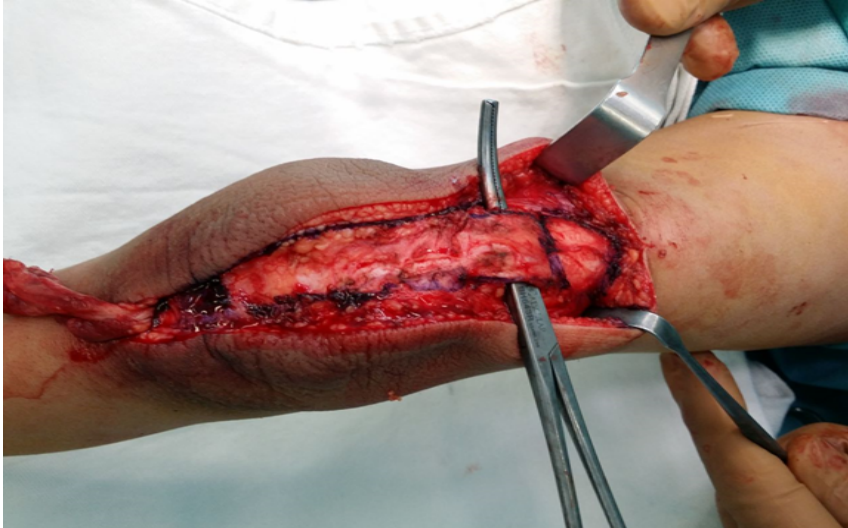


A. Severe flexion contracture of the left knee; B. Abnormal patella height based on the Insall-Salvati ratio seen in lateral knee x-ray studies



**Figure 2.** Lazy S-shape incision to expose the posterior aspect of left knee joint





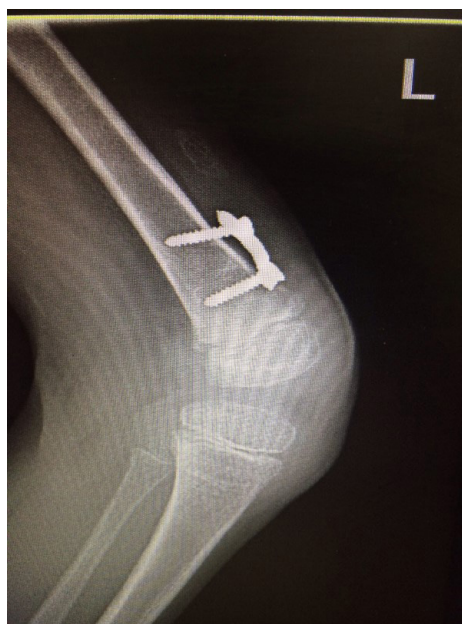**Figure 3.** Patella tendon exposed, and the length marked between the inferior poles of the patella to the tibial tuberosity



Neurovascular components were first explored and secured; then, the hamstring tendons were lengthened with aponeurectomy medially and laterally except semitendinosus, which was saved for further transfer. Afterward, the posterior capsule was released under direct vision, which made flexion contracture better (up to 30-40 degrees). The patella was not reducible because of the high riding patella and mal-insertion of patellar tendon into the superior part of the knee capsule instead of the tibial tubercle (Figure 3).

Then the patient was turned over to the supine position. A direct anterior approach was used to reach to the patella and distal femoral physis. The tendinous part of semitendinosus was released by tendon stripper, then

harvested and transferred anteriorly toward the tibial tuberosity. It was secured at the tibial tuberosity by anchor suture and finally attached to the inferior pole of the patella via the patellar tendon, which was detached from the superior capsular part. We were not able to reduce the patella to its normal anatomic position. By the competent quadriceps muscle and patellar tendon, attached now to tibial tubercle via semitendinosus tendon, the patient's extensor function improved considerably. It made the flexion degree residual reduced to 20-30 degrees. Afterward, we performed anterior hemiepiphysiodesis using eight plates in the distal femoral physis. This procedure was intended to correct the residual flexion deformity. In the end, the posterior 3\*3 skin defect was grafted with a full-thickness thigh skin



**Figure 4.** Left knee postoperative radiography





**Figure 5.** After the knee surgery, the patient's ability to walk and flex the left knee, with 30-degree fixed flexion in extension



graft. Before leaving the operation room, we examined the knee joint for stability and found it to be stable. The knee was then immobilized in a long leg cast for six weeks. [Figure 4](#) shows postoperative radiography from the left knee in flexion.

After removal of the cast, the patient could walk with a 30-degree fixed knee ([Figure 5](#)). Then, a course of physiotherapy was started and continued during the next eight months until improvement in the extensor mechanism plateaued. During this period, knee flexion contracture reduced to 5-10 degrees because of distal femur hemiepiphyodesis, but his active extension lag was 20 degrees because of the weakness of the extensor mechanism.

## Discussion

Congenital Patella alta is a condition characterized by unusually small patella that develops out of and above the knee joint. This disease is an extremely rare condition with an unknown incidence that affects mobility and leg strength [6]. This entity may be manifested with different clinical presentations: Pain in the patella (the major symptom of patella alta), fixed knee flexion deformity due to muscle weakness, accentuated valgus in the affected lower limb, and gait imbalance that is a common manifestation among children with neuromuscular disorders [7]. The most common presentation is a fixed knee flexion contracture that is mostly refractory to physical therapy, bracing, or pharmaceutical manage-

ment [8]. As such, surgical management may be indicated for those children.

The congenital patella alta can be diagnosed with the x-ray at the age of three years when the patella begins to ossify. The axial view of the patella makes it possible to assess the position, size, and shape of the patella. In children, the ossification of the patella starts at the age of 3-5 years [9]. In younger children whose patellar ossification has not occurred, ultrasound or MRI is an important instrument that makes it possible to have a view from knee components. CT scan and MRI supplies detailed information about the bone component of the knee and soft tissue, respectively [10].

Patella alta decreases the movement arm of the terminal knee extension, which further weakens an already damaged extensor mechanism. This extra tension can cause repetitive microtrauma to the patellar and quadriceps tendons, causing elongation of these structures, fragmentation, and stress fractures of the patella and tibial tubercle [11]. Thus, it is essential to recognize and surgically treat this condition during childhood.

Surgical treatment of the underlying pathological process, usually patellar subluxation and dislocation, is helpful in patients in whom conservative treatment has failed. Simons et al. have introduced a surgical technique involving transposing the patellar tendon insertion distally without any medialization or recessing. This procedure allows for good bone contact and healing, secure fixation, and immediate postoperative motion.

They reported no recurrences of patellar dislocation postoperatively and few complications [12].

Other associated procedures cause improvement in not only the patella alta but also knee function in general. Correction of the flexion deformity of the knee with hamstring lengthening requires posterior capsulotomy or supracondylar osteotomy and recently anterior distal hemiepiphysiodesis [13]. This approach can be supplemented or supplemented by external frame distraction that is used more often in congenital or long-standing knee flexion contracture [14, 15].

Currently, the guided growth of the anterior distal femur has been suggested by some surgeons to achieve safe and gradual correction of the crouch pattern [16-18]. Beals compared various combinations of hamstring lengthening and or posterior capsulotomy to allow free passive knee extension, with or without quadriceps mechanism shortening, to enhance voluntary extension. He reported the best results among patients who had hamstring lengthening, posterior capsulotomy, and quadriceps mechanism shortening [19]. This fact is shown in our case as surgical treatment is better than non-surgical treatment in refractory patients.

Congenital patella alta is a rare deformity in children. If diagnosed at an early age, it could be treated with fewer complications. Clinical and radiographic findings are characteristic of this dislocation. Open reduction with rigid internal fixation and early rehabilitation give satisfactory results. Conservative management is not recommended in these cases.

## Ethical Considerations

### Compliance with ethical guidelines

All ethical principles were considered in this article.

### Funding

This research did not receive any specific grant from funding agencies in the public, commercial, or not-for-profit sectors.

### Conflict of interest

The authors declared any conflict of interest.

## References

- [1] Hanspal R. Superior dislocation of the patella. *Injury*. 1985; 16(7):487-8. [DOI:10.1016/0020-1383(85)90176-7]
- [2] Cusco X, Seijas R, Ares O, Cugat JR, Garcia-Balletbo M, Cugat R. Superior dislocation of the patella: A case report. *Journal of Orthopaedic Surgery and Research*. 2009; 4:29. [DOI:10.1186/1749-799X-4-29] [PMID] [PMCID]
- [3] Bassi RS, Kumar BA. Superior dislocation of the patella; a case report and review of the literature. *Emergency Medicine Journal*. 2003; 20(1):97-8. [DOI:10.1136/emj.20.1.97] [PMID] [PMCID]
- [4] Wood L, Stirrat AN. Superior dislocation of the patella: A case report and review of the literature. *The Knee*. 1998; 5(4):299-300. [DOI:10.1016/S0968-0160(98)00002-7]
- [5] Berg EE, Mason SL, Lucas MJ. Patellar height ratios: A comparison of four measurement methods. *The American Journal of Sports Medicine*. 1996; 24(2):218-21. [DOI:10.1177/036354659602400218] [PMID]
- [6] Hasler CC, Studer D. Patella instability in children and adolescents. *EFORT Open Reviews*. 2016; 1(5):160-6. [DOI:10.1302/2058-5241.1.000018] [PMID] [PMCID]
- [7] Cohen SL, Reilly EB. Congenital unilateral superior dislocation of the patella. *United States Armed Forces Medical Journal*. 1952; 3(4):655-6. [PMID]
- [8] van der Krogt MM, Bregman DJJ, Wisse M, Doorenbosch CAM, Harlaar J, Collins SH. How crouch gait can dynamically induce stiff-knee gait. *Annals of Biomedical Engineering*. 2010; 38(4):1593-606. [DOI:10.1007/s10439-010-9952-2] [PMID] [PMCID]
- [9] Kannus PA. Long patellar tendon: Radiographic sign of patellofemoral pain syndrome—a prospective study. *Radiology*. 1992; 185(3):859-63. [DOI:10.1148/radiology.185.3.1438776] [PMID]
- [10] Shabshin N, Schweitzer ME, Morrison WB, Parker L. MRI criteria for patella alta and baja. *Skeletal Radiology*. 2004; 33(8):445-50. [DOI:10.1007/s00256-004-0794-6] [PMID]
- [11] Ward SR, Terk MR, Powers CM. Influence of patella alta on knee extensor mechanics. *Journal of Biomechanics*. 2005; 38(12):2415-22. [DOI:10.1016/j.jbiomech.2004.10.010] [PMID]
- [12] Simmons E, Cameron JC. Patella alta and recurrent dislocation of the patella. *Clinical Orthopaedics and Related Research*. 1992; 274:265-9. [PMID]
- [13] Ma FYP, Selber P, Natrass GR, Harvey AR, Wolfe R, Graham HK. Lengthening and transfer of hamstrings for a flexion deformity of the knee in children with bilateral cerebral palsy: Technique and preliminary results. *The Journal of Bone and Joint Surgery British Volume*. 2006; 88-B(2):248-54. [DOI:10.1302/0301-620X.88B2.16797] [PMID]
- [14] Hosny GA, Fadel M. Managing flexion knee deformity using a circular frame. *Clinical Orthopaedics and Related Research*. 2008; 466(12):2995-3002. [DOI:10.1007/s11999-008-0530-y] [PMID] [PMCID]
- [15] Ullmann Y, Fodor L, Soudry M, Lerner A. The Ilizarov technique in joint contractures and dislocations. *Acta Orthopaedica Belgica*. 2007; 73(1):77-82. [PMID]
- [16] Klatt J, Stevens PM. Guided growth for fixed knee flexion deformity. *Journal of Pediatric Orthopaedics*. 2008; 28(6):626-31. [DOI:10.1097/BPO.0b013e318183d573] [PMID]

- [17] Palocaren T, Thabet AM, Rogers K, Holmes Jr L, Donohoe M, King MM, et al. Anterior distal femoral stapling for correcting knee flexion contracture in children with arthrogryposis-preliminary results. *Journal of Pediatric Orthopaedics*. 2010; 30(2):169-73. [[DOI:10.1097/BPO.0b013e3181d07593](https://doi.org/10.1097/BPO.0b013e3181d07593)] [PMID]
- [18] Stevens PM, Maguire M, Dales MD, Robins AJ. Physeal stapling for idiopathic genu valgum. *Journal of Pediatric Orthopaedics*. 1999; 19(5):645. [[DOI:10.1097/01241398-199909000-00018](https://doi.org/10.1097/01241398-199909000-00018)] [PMID]
- [19] Beals RK. Treatment of knee contracture in cerebral palsy by hamstring lengthening, posterior capsulotomy, and quadriceps mechanism shortening. *Developmental Medicine & Child Neurology*. 2001; 43(12):802-5. [[DOI:10.1111/j.1469-8749.2001.tb00166.x](https://doi.org/10.1111/j.1469-8749.2001.tb00166.x)] [PMID]