



Case Report

Journal Homepage: <http://crp.tums.ac.ir>

Osteoma Cutis of the Scalp in a Case of Multiple Basal Cell Carcinoma Induced by Radiotherapy



Maryam Nasimi¹ , Maryam Daneshpazhooh¹, Azita Nikoo², Arghavan Azizpour¹, Safoura Shakoei^{3*} 

1. Department of Dermatology, Razi Hospital, Tehran University of Medical Sciences, Tehran, Iran.

2. Department of Pathology, Razi Hospital, Tehran University of Medical Sciences, Tehran, Iran.

3. Department of Dermatology, Imam Khomeini Hospital Complex, Tehran University of Medical Sciences, Tehran, Iran.

Use your device to scan
and read the article online



Citation: Nasimi M, Daneshpazhooh M, Nikoo A, Azizpour A, Shakoei S. Osteoma Cutis of the Scalp in a Case of Multiple Basal Cell Carcinoma Induced by Radiotherapy. Case Reports in Clinical Practice. 2020; 5(1):11-14.

Running Title: Osteoma Cutis of the Scalp in a Case of Multiple BCC



Article info:

Received: 26 December 2019

Revised: 20 January 2020

Accepted: 01 February 2020

Keywords:

Osteoma cutis; Radiodermatitis;
Scalp; Bone formation

ABSTRACT

Introduction: Multiple osteoma cutis is a rare skin disorder characterized by tiny bone fragments deposition in the skin. It is a benign disease, which occurs as primary or secondary forms. Secondary osteoma cutis most commonly appears on the facial acne scars in middle-aged women. The exact etiology of this phenomenon is unknown, but it may be induced by osteoblastic metaplasia of mesenchymal elements.

Case Presentation: Herein, we report a 70-year-old man with a history of multiple basal cell carcinoma (BCC) of the scalp caused by radiotherapy, who referred to our tumor clinic with multiple skin-colored subcutaneous papules and nodules on his scalp from 2 years ago along with cutaneous side effect changes of radiodermatitis. In the histological examination of lesions with differential diagnosis of BCC, cysts, and adnexal tumors, the diagnosis of osteoma cutis was established without any evidence of BCC.

Conclusion: Osteoma cutis is a rare disorder most commonly affecting the face, but our patient had multiple lesions of the scalp. The inflammatory changes of radiodermatitis may be the principal cause of this change.

*Corresponding Author:

Safoura Shakoei, MD.

Address: Department of Dermatology, Imam Khomeini Hospital Complex, Tehran University of Medical Sciences, Tehran, Iran.

E-mail: dr.shakoei@gmail.com

Introduction

Multiple osteoma cutis is a rare disorder characterized by extraskeletal bone formation in the dermis or subcutis [1]. This condition, whether primary without any pre-existing disease or secondary to either inflammatory or neoplastic processes, leads to ossification [2, 3]. The fundamental conditions that can be associated with osteoma cutis are Albright hereditary osteodystrophy, fibrodysplasia ossificans progressiva (with a mutation in the ACVR1 gene), progressive osseous heteroplasia, isolated osteomas, widespread osteomas, multiple miliary osteoma cutis, and Plate-like Osteomas Cutis (PLOC) (with a mutation in the GNAS gene) [4].

The miliary osteoma cutis is characterized by the tiny bone fragments (up to 3 mm in diameter), which most commonly affect the facial skin of late-middle-aged women [2]. The osteoma usually remains localized, but the number of lesions may increase over time [2]. We present a case of osteoma cutis on the scalp with cutaneous signs of radiodermatitis.

Case Report

A 70-year-old man presented to our clinic with multiple skin-colored subcutaneous papules and nodules over his scalp, specifically the vertex area. His lesions were asymptomatic except slight pain after trauma to the lesions. His lesions appeared two years ago and had been increasing in size and number gradually. He had a history of several scalp Basal Cell Carcinoma (BCC) that had been treated with excisional surgery. The patient

also had a history of radiotherapy during childhood for the treatment of tinea capitis. Physical examination revealed signs of radiodermatitis with skin atrophy, hair loss, scars of previous tumor surgery along with numerous small, firm, skin-colored nodules on the vertex area (Figure 1). Physical examination was otherwise normal. Lesions look like small cystic lesions, and one of them was biopsied to rule out BCC. The histopathology revealed multiple well-formed bony spicules with prominent cement lines and calcification foci in the full thickness of the dermis, consisting of lamellar bone (Figure 2). The diagnosis of osteoma cutis was established according to the clinical and pathological findings.

The laboratory tests, including measurement of alkaline phosphatase, phosphate, calcium, and parathyroid hormone, did not reveal any abnormal results. Curettage therapy was performed for symptomatic larger lesions (Figure 3).

Discussion

Osteoma cutis is characterized by the occurrence of mature osseous nodules within the dermis or subcutis [4]. It is a rare disorder that primarily occurs in middle-aged women [3].

The lesions are usually asymptomatic skin-colored hard papules, up to 3 mm in diameter, with a bluish appearance that appear on the face as well as the trunk and extremities [4]; the involvement of the scalp has been reported infrequently [1, 4].

The reported cases of osteoma cutis of the scalp are plate-like form [5] or miliary osteoma cutis [1, 4]. Based on the literature review, our patient is a rare case of os-



Figure 1. Radiodermatitis of scalp with skin atrophy, hair loss, scars of previous tumor surgery along with numerous small, firm, skin-colored nodules on the vertex area

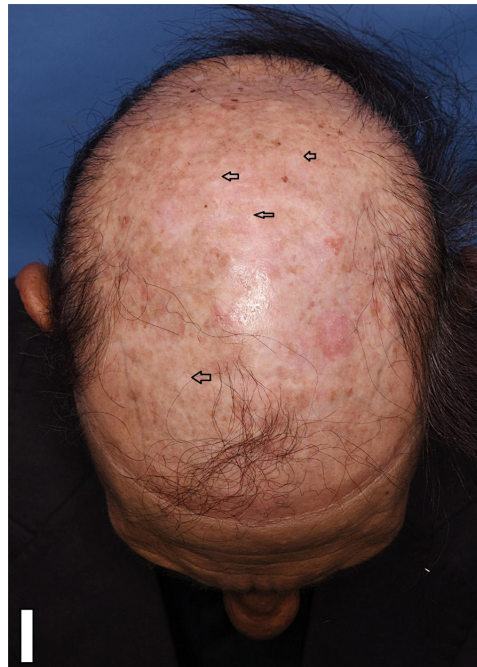

Figure 2. Multiple well-formed bony spicules with prominent cement lines and calcification foci in the dermis, consisting of lamellar bone (H & E, magnification: $\times 100$)

teoma cutis of the scalp. The lesions were larger than miliary and smaller than plate-like form.

The pathogenesis of cutaneous osteomas is still unknown [1]. In secondary osteomas, metaplasia is a responsible explanation for the formation of osteoma. The signaling factors may trigger the primary mesenchymal cells to differentiate towards the osteogenic lineage [2]. Secondary osteoma cutis is responsible for

85% of cases [4], and lesions most commonly occur on acne vulgaris scars [6]. Also, they may arise secondary to collagen vascular diseases (e.g. scleroderma or dermatomyositis) and skin tumors (e.g. pilomatricoma, BCC, desmoplastic melanoma, and melanocytic nevi), scar tissue, sites of trauma or injection, and venous stasis [3]. In our case, there was not any evidence of BCC in osteoma cutis lesions. Therefore secondary ossification of BCCs was

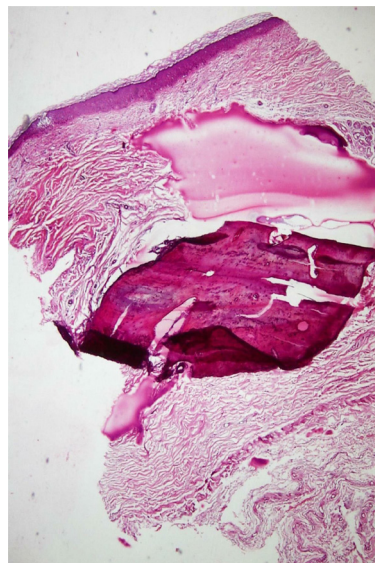


Figure 3. Curettage therapy was performed for symptomatic larger lesions



almost ruled out. It seems that the underlying radiodermatitis may be the main cause for these changes.

Invasive and noninvasive treatment modalities, including oral and topical retinoid, have been reported in previous studies [4, 7]. Topical retinoic acid is used to increase trans-epidermal elimination [8]. Surgical excision, dermabrasion [9], needle micro-incision, and curettage [6] are other treatment modalities. Erbium YAG laser [10] and CO₂ laser have also been used with excellent cosmetic results [7]. We considered curettage therapy for symptomatic and larger lesions.

Ethical Considerations

Compliance with ethical guidelines

All ethical principles were considered in this article. The written informed consent was taken from patient.

Funding

This research did not receive any specific grant from funding agencies in the public, commercial, or not-for-profit sectors.

Conflict of interest

The authors declared no conflict of interest.

References

- [1] Painsi C, Tarmann R, Würtz FG, Malle P, Wolf P, Hügel R, et al. Multiple miliary osteoma cutis of the scalp. *Journal der Deutschen Dermatologischen Gesellschaft*. 2015; 13(11):1185-7. [DOI:10.1111/ddg.12836] [PMID]
- [2] Myllylä RM, Haapasaari KM, Palatsi R, Germain-Lee EL, Hägg PM, Ignatius J, et al. Multiple miliary osteoma cutis is a distinct disease entity: Four case reports and review of the literature. *British Journal of Dermatology*. 2011; 164(3):544-52. [DOI:10.1111/j.1365-2133.2010.10121.x] [PMID]
- [3] Conlin PA, Jimenez-Quintero LP, Rapini RP. Osteomas of the skin revisited: A clinicopathologic review of 74 cases. *The American Journal of Dermatopathology*. 2002; 24(6):479-83. [DOI:10.1097/00000372-200212000-00004] [PMID]
- [4] Ma HJ, Jia CY, Yang Y, Song LJ, Hu R, Li TH. Primary multiple miliary osteoma cutis: An unusual Chinese case. *International Journal of Dermatology*. 2014; 53(1):73-5. [DOI:10.1111/j.1365-4632.2011.05429.x] [PMID]
- [5] Coutinho I, Teixeira V, Cardoso JC, Reis JP. Plate-like osteoma cutis: Nothing but skin and bone? *BMJ Case Reports*. 2014; 2014:bcr2013202901. [DOI:10.1136/bcr-2013-202901] [PMID] [PMCID]
- [6] Chabra IS, Obagi S. Evaluation and management of multiple miliary osteoma cutis: Case series of 11 patients and literature review. *Dermatologic Surgery*. 2014; 40(1):66-8. [DOI:10.1111/dsu.12389] [PMID]
- [7] Kim SY, Park SB, Lee Y, Seo YJ, Lee JH, Im M. Multiple miliary osteoma cutis: Treatment with CO₂ laser and hook. *Journal of Cosmetic and Laser Therapy*. 2011; 13(5):227-30. [DOI:10.3109/14764172.2011.613481] [PMID]
- [8] Cohen AD, Chetov T, Cagnano E, Naimer S, Vardy DA. Treatment of multiple miliary osteoma cutis of the face with local application of tretinoin (all-trans-retinoic acid): A case report and review of the literature. *Journal of Dermatological Treatment*. 2001; 12(3):171-3. [DOI:10.1080/09546630152607925] [PMID]
- [9] Thielen AM, Stucki L, Braun RP, Masouyé I, Germanier L, Harms M, et al. Multiple cutaneous osteomas of the face associated with chronic inflammatory acne. *The Journal of the European Academy of Dermatology and Venereology*. 2006; 20(3):321-6. [DOI:10.1111/j.1468-3083.2006.01425.x] [PMID]
- [10] Ochsendorf FR, Kaufmann R. Erbium: YAG laser-assisted treatment of miliary osteoma cutis. *British Journal of Dermatology*. 1998; 138(2):371-2. [DOI:10.1046/j.1365-2133.1998.02106.x] [PMID]