



Case Report

Journal Homepage: <http://crp.tums.ac.ir>

Herbal Treatments to Gain Weight as the Potential Cause of Portal Vein Thrombosis and Hepatic Damage: A Case Report



Mona Azarkish¹ , Mahsa Abbaszadeh^{2*} , Soha Namazi³ , Sahar Karimpour Reyhan² 

1. Cardiology resident, Tehran University of Medical Sciences, Tehran, Iran.

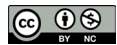2. Assistant professor, Department of General Internal Medicine, Imam Khomeini Hospital Complex, Tehran University of Medical Sciences, Tehran, Iran.

3. Assistant Professor, Department of Clinical Pharmacy, School of Pharmacy, Tehran University of Medical Sciences, Tehran, Iran.



Citation Azarkish M, Abbaszadeh M, Namazi S, Karimpour Reyhan S. Herbal Treatments to Gain Weight as the Potential Cause of Portal Vein Thrombosis and Hepatic Damage: A Case Report. *Case Reports in Clinical Practice*. 2019; 4(4):105-109.

Running Title A Herbal Agent to Gain Weight as the Potential Cause of Portal Vein Thrombosis and Hepatic Damage



Article info:

Received: 06 October 2019

Revised: 18 November 2019

Accepted: 28 November 2019

Keywords:

Portal Vein Thrombosis (PVT); Splenomegaly; Abdominal pain; Weight loss

ABSTRACT

This research aimed to assess the effect of a specific herbal agent to gain weight as the potential cause of Portal Vein Thrombosis (PVT) and hepatic damage. In this study, we reported a 24-year-old man who referred to the Tehran University of Medical Sciences (TUMS) hospital complaining of 4-day progressive abdominal pain. The patient's abdominal pain was generalized with a mild tenderness over the epigastric region. He complained of nausea, vomiting, and loss of appetite. However, he reported no hematemesis, melena, or dyspnea, with unremarkable past and family medical history. An abdominopelvic ultrasound and Computed Tomography (CT) scan were conducted for further investigation of the patient, which revealed extended filling defect in portal vein and its branches. In addition, the evidence of liver hypoperfusion was found because of geographic hypodense lesion seen in the major parts of the right lobe and the IV segment of the left lobe. The patient was further assessed for any acquired or inherited potential prothrombotic state associated with abdominal vein thrombosis, which were all ruled out. However, his round moon face, purplish striae, and the back acne increased the suspicion of drug side effects. Finally, a herbal agent (Fereshteh tablet) was found as the cause of the patient's disease. He consumed the tablet to gain weight from 3 months ago. His thrombosis was treated with subcutaneous enoxaparin, as well as oral intake of warfarin. He was recommended to check liver function regularly at outpatient hepatobiliary clinic after discharge.

* Corresponding Author:

Mahsa Abbaszadeh, PhD.

Address: Department of General Internal Medicine, Imam Khomeini Hospital Complex, Tehran University of Medical Sciences, Tehran, Iran.

E-mail: m-abbaszadeh@sina.tums.ac.ir

Introduction

Portal Vein Thrombosis (PVT) in patients with a previously healthy liver can be due to the inherited or acquired prothrombotic states, neoplasms, myeloproliferative syndromes, collagen vascular diseases, antiphospholipid syndrome, pregnancy, etc. However, no underlying disease is identified in more than 25% of the patients. According to the statistical reports, the lifetime risk of developing PVT is about 1% [1].

It is widely believed that herbal remedies are safer than modern medical treatments as they have no side effects. Therefore, herbal treatments are used even for health-related issues, which are not serious, such as weight gain, low appetite, and digestive problems. Many people consider these herbals as safer, easier, and faster prescriptions. Considering such belief, many companies have provided different herbal remedies and promoted people using these products. In addition, as traditional medical treatments, such as acupuncture and herbal medicines are commonly used in Iran, many companies use these commercial tips to highlight their advertisements. Although the majority of these products seem to be safe, their short- and long-term effects on overall health of the consumers are unclear.

Despite much research done on PVT, no study has been ever conducted on its relationship with herbal treatments to gain weight. Although using herbal remedies is growing significantly, studying their harmful effects is not (may be due to the lack of strict control over these treatments). Thus, investigating herbal products to gain weight is beneficial with regard to the following concerns:

1. To show the adverse effects of these products, so that people use them more carefully;
2. To motivate other researchers to assess the side effects of these herbals in other health-related issues;
3. To inform legal authorities reconsider the advertising permissions of these products.

In summary, based on previous studies, PVT mainly results from abdominal inflammation, liver cirrhosis, tumorous invasion, and thrombophilic conditions. This case report enriches our knowledge about the effect of herbal treatments to gain weight on PVT. In other words, it presents a new idea regarding the correlation between herbal treatments to gain weight and hepatic failure. To our knowledge, this is the first investigation on this issue.

Case Presentation

A 24-year-old male patient suffering from 4 days progressive abdominal pain referred to the hospital. The patient's abdominal pain was generalized and a mild tenderness over his epigastric region. He complained of nausea, vomiting, and loss of appetite. However, he reported no hematemesis, melena, or dyspnea, with unremarkable past and family medical history. His only history of surgery was rhinoplasty.

In the physical exam, purplish striae, moon face, the back acne and the generalized edema were seen. According to his report, he only used 100 herbal tablets to gain weight. The initial abdominopelvic ultrasound did not show a specific disease. Also, Nasogastric (NG), gastric emptying treatments and gastric medicines were also ineffective. The patient was then referred to another hospital with the discussed complaints. His second abdominopelvic ultrasound results showed the fatty liver grade 1. In addition, the port diameter was 14 mm. Therefore, the symptoms of PVT were seen in the bifurcation of the port. Furthermore, as the size of patient's spleen was 143 mm, the splenomegaly was also diagnosed.

The remaining essential factors of ultrasound were reported normal. As the patient still suffered from the abdominal pain, he was referred to the Tehran University of Medical Sciences' (TUMS) hospital for supplementary treatments. Initially, an abdominopelvic CT scan was conducted to complete the diagnosis. According to the obtained results, a filling defect was seen in the major parts of the main lumen of the portal vein extending to the proximal segment of the left branch, right branch and their posterior and anterior parts. In addition, the diagnosed filling defect in splenic vein, Superior Mesenteric Vein (SMV) and Inferior Mesenteric Vein (IMV) was interpreted as the complete PVT of aforementioned veins. Furthermore, no sign of arterial thrombosis was reported.

According to the CT scan results, a hypodense geographical lesion in the major parts of the right lobe of the liver and the IV segment was seen (Figure 1). These findings revealed a lower enhancement in both arterial and portal phases, compared with the normal tissue, potentially caused by hypoperfusion. Also, the splenomegaly and small quantities of ascitic fluid were found in the abdominal cavity.

Because PVT was confirmed as the cause of patient's acute abdominal pain, the next step was identifica-

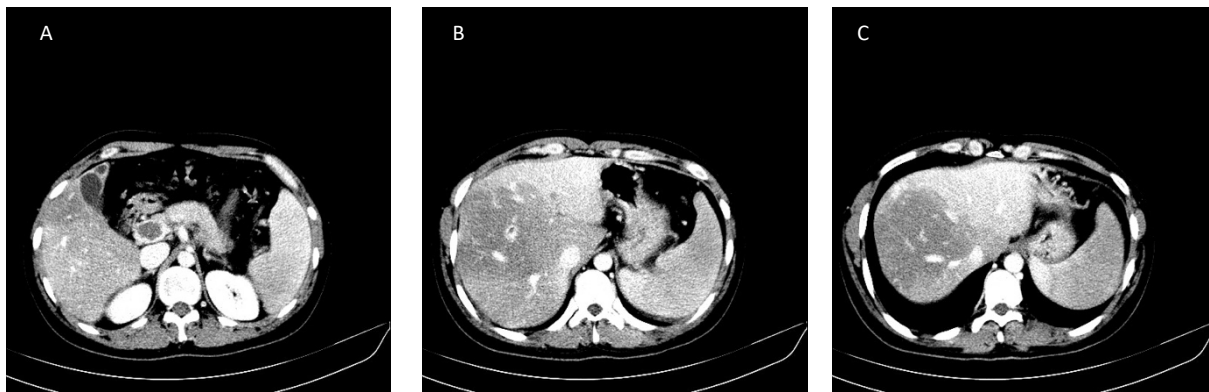


Figure 1. The CT scan results

A. Portal Vein Thrombosis; B and C. Liver damage



Table 1. The full list of conducted tests

No.	Test	Value	Unit	Results	
1	WBC	6800	X1000/mm ³	Normal	
2	Hemoglobin	14.8	Million/mm ³	Normal	
3	Platelet	304*10 ³	X1000/mm ³	Normal	
4	Na	137	meq/L	Normal	
5	K	3.8	meq/L	Normal	
6	Urea	19	mg/dL	Normal	
7	Cr	0.8	mg/dL	Normal	
8	AST	32	U/L	Normal	
9	ALT	19	U/L	Normal	
10	ALP	183	U/L	Normal	
11	Bilirubin	Total	0.8	mg/dL	Normal
		Direct	0.2	mg/dL	Normal
12	Ca	9.8	mg/dL	Normal	
13	P	4.6	mg/dL	Normal	
14	Mg	2.1	mg/dL	Normal	
15	Alb	4.3	g/dL	Normal	
16	PT	14.5	s	Normal	
17	PTT	30	s	Normal	
18	INR	1.2	s	Normal	
19	Amylase	46	U/L	Normal	
20	Lipase	25	IU/L	Normal	
21	CRP	78	mg/dL	Normal	
22	ESR	87	mm/h	Normal	
23	BS	104	mg/dL	Normal	
24	VBG	PH	7.41	-	Normal
		PCO2	36.3	mm Hg	Normal
		HCO3-	23.3	mm Hg	Normal
25	HIV Ab		Negative		
26	HBS Ag		Negative		
27	HCV Ab		Negative		



Table 2. Causes of Portal Vein Thrombosis (PVT) [5]

Others	Inflammatory Disease	Prothrombotic Causes	Neoplasms
Pregnancy	Diverticulitis	Inherited prothrombotic disorders	Hepatocellular carcinoma
Oral contraceptive	Pancreatitis	Factor V Leiden mutation	Hepatobiliary cancer
Idiopathic disease	Appendicitis	Factor II gene mutation	Pancreatic cancer
	Inflammatory bowel disease	JAK 2 gene mutation	Gastrointestinal cancer
	Connective tissue disease	Protein C deficiency	Malignant lymphoma
	Cytomegalovirus/HIV infection	Protein S deficiency	Other primary cancers
	Tuberculous lymphadenitis	Antithrombin III deficiency	
	Abdominal surgery and trauma	Acquired thrombophilic disorders	
	Omphalitis/neonatal umbilical sepsis	Primary myeloproliferative disorders	
		Paroxysmal nocturnal hemoglobinemia	
		Antiphospholipid syndrome	
		Hyperhomocysteinemia	
		Increased factor VIII levels	
		Thrombin Activatable Fibrinolysis Inhibitor (TAFI) gene	



tion of the underlying cause of thrombosis. All potential inherited or acquired prothrombotic states causing abdominal vein thrombosis were investigated. Table 1 presents the complete list of conducted tests.

Viral markers, coagulation factors, and probability of underlying neoplasm or cirrhosis were checked and all came back negative in the patient. The levels of anti ds-DNA, lupus anticoagulant Ab IgM and IgG, anti-cardiolipine Ab, IgM and IgG, β 2 glycoprotein Ab IgM and IgG, factor V liden, the level of protein C and S were all within normal range. The peripheral blood flow cytometry reported normal values for CD 55 and CD 59. Pathergy test for diagnosis of Behcet's syndrome was reported negative. In addition, echocardiography results were normal. Afterward, upper gastrointestinal endoscopy to diagnose the esophageal varices was conducted, which the results were found normal. Therefore, although the patient had PVT, no specific cause was found for it.

Finally, a herbal agent the patient consumed for weight gain since 3 months ago was suspected to be the cause. The pharmacotherapy consultancy showed that the used medicine could potentially include the corti-

costeroid compounds. Observation of the round moon face, purplish striae and the back acne increased the probability of side effects by used drug. Unfortunately, we could not analyze the herbal drug ingredients.

As a summary of treatment protocol, enoxaparin sodium amp 60 mg BID and warfarin tablet 5 mg daily were administrated for the patient. The treatment was followed-up and the International Normalized Ratio (INR) reached the normal status [2-3]. Therefore, he was discharged from the hospital. He was recommended to long-time regular outpatient follow-up of liver function in hepatobiliary clinic after discharge.

Discussion

Generally, PVT is known as the ordinary blood flow interruption in the portal vein caused by the formation of blood clot. (The causes of PVT are shown in Table 1). However, PVT has been reported after Radiofrequency Ablation for Hepatocellular Carcinoma (HCC), bariatric surgery and also the fine needle aspiration of pancreatic cancer [2-4].

As tabulated in Table 2, there are many potential causes of PVT. Consequently, all these potential causes were considered and investigated in our patient and they were all negative. Considering the consumed 100 herbal tablets to gain weight by patient and since medical investigations could not find a specific reason for PVT, this herbal treatment can be a new potential cause of PVT to be further investigated by other researchers.

Accordingly, investigating the effects of using herbal tablets to gain weight as the potential cause of PVT in a real case study was the main aim of this research. The following research questions were addressed in this research:

1. Can herbal treatment to gain weight cause diffuse thrombosis in most of the abdominal veins?
2. Can herbal treatment to gain weight cause hepatic failure?
3. How can PVT caused by herbal treatments to gain weight be treated?

The pharmacotherapy consultation showed that the used medicine can potentially include corticosteroid compounds only based on clinical symptoms (moon face, acne and striae). Unfortunately, we could not analyze the herbal drug ingredients due to some limitations, but our inquiry from the Food and Drug Administration revealed that it includes Tramadol and Cyproheptadine as the previous FERESHTEH TABLETS ingredients, based on previous drug analysis.

In conclusion, this case report investigated the potential effect of a particular herbal treatment to gain weight as the cause of PVT. Medical investigations showed a filling defect in major parts of the main lumen of the portal vein extending to the proximal of the left branch, right branch and its posterior and anterior parts. In addition, the diagnosed filling defect in splenic vein, SMV and IMV was considered as the complete PVT of the above-mentioned veins. As the main finding of this case report, since all potential causes of the PVT were checked by the TUMS hospital and none of them were found to be significant in the patient, the diagnosed PVT can be potentially related to the herbal remedy to gain weight consumed by the patient.

Regarding this issue, in less than one month, another case was referred to the same hospital due to deep vein thrombosis who reported receiving the same herbal treatment through the last 6 months. Accordingly, further specific investigations are recommended to assess using this herbal treatment and also its ingredients.

The required treatment of acute PVT in all cases is administration of anticoagulant drugs, which is not associated with the underlying cause. Accordingly, in the studied case that PVT was induced by the using the herbal therapy to gain weight it was treated with Enoxaparin and Warfarin.

Ethical Considerations

Compliance with ethical guidelines

All ethical principles were considered in this article.

Funding

This work is supported in part by the Imam Khomeini Hospital Complex Research Center.

Conflict of interest

The authors declared no conflict of interest.

References

- [1] Plessier A, Darwish-Murad S, Hernandez-Guerra M, Consigny Y, Fabris F, Trebicka J, et al. Acute portal vein thrombosis unrelated to cirrhosis: A prospective multicenter follow-up study. *Hepatology*. 2010; 51(1):210-8. [DOI:10.1002/hep.23259] [PMID]
- [2] Shimada T, Maruyama H, Kondo T, Sekimoto T, Takahashi M, Motoyama T, et al. Clinical features and natural history of portal vein thrombosis after radiofrequency ablation for hepatocellular carcinoma in Japan. *Hepatology International*. 2013; 7(4):1030-9. [DOI:10.1007/s12072-013-9470-z] [PMID]
- [3] Rottenstreich A, Elazary R, Kalish Y. Abdominal thrombotic complications following bariatric surgery. *Surgery for Obesity and Related Diseases*. 2017; 13(1):78-84. [DOI:10.1016/j.soard.2016.05.012] [PMID]
- [4] Matsumoto K, Yamao K, Ohashi K, Watanabe Y, Sawaki A, Nakamura T, et al. Acute portal vein thrombosis after EUS-guided FNA of pancreatic cancer: Case report. *Gastrointestinal Endoscopy*. 2003; 57(2):269-71. [DOI:10.1067/mge.2003.79] [PMID]
- [5] Mantaka A, Augoustaki A, Kouroumalis EA, Samonakis DN. Portal vein thrombosis in cirrhosis: Diagnosis, natural history, and therapeutic challenges. *Annals of Gastroenterology*. 2018; 31(3):315-29. [DOI:10.20524/aog.2018.0245] [PMID] [PMCID]
- [6] El Lakis MA, Pozzi A, Chamieh J, Safadi B. Portomesenteric vein thrombosis after laparoscopic sleeve gastrectomy and laparoscopic Roux-en-Y gastric bypass: A 36-case series. *Surgical Endoscopy*. 2017; 31(3):1005-11. [DOI:10.1007/s00464-016-5078-4] [PMID]
- [7] Sogaard KK, Astrup LB, Vilstrup H, Gronbaek H. Portal vein thrombosis; risk factors, clinical presentation and treatment. *BMC Gastroenterology*. 2007; 7:34. [DOI:10.1186/1471-230X-7-34] [PMID] [PMCID]