



# Schwannoma in an Uncommon Site, Upper Lip: A Case Report



Elham Nazar\* , Hiva Saffar

Department of Pathology, Shariati Hospital, Tehran University of Medical Sciences, Tehran, Iran.

Use your device to scan and read the article online



**Citation:** Nazar E, Saffar H. Schwannoma in an Uncommon Site, Upper Lip: A Case Report. Case Reports in Clinical Practice .2019; 4(3):78-80.

**Running Title:** Schwannoma in Upper Lip



## Article info:

**Received:** 19 July 2019

**Revised:** 04 August, 2019

**Accepted:** 15 September 2019

## Keywords:

Schwannoma; Head; Lip

## ABSTRACT

Schwannoma is one of the most common benign intracranial tumors which originates from the Schwann cells of neural sheaths in the upper part of vestibular branch of the eighth nerve, especially in patients with neurofibromatosis type 2. Schwannoma in the other parts of head and neck region is, however, relatively uncommon. The present report describes a rare case of schwannoma that was accidentally discovered in the upper lip in asymptomatic patient lasting for more than 10 years with recently size enlargement. Schwannoma could be seen in a variety of anatomic sites. Thus, this diagnosis should be considered in the differential diagnosis of soft tissue tumor in any location.

## Introduction

Schwannoma is one of the most common intracranial tumors which originates from the Schwann cells of neural sheaths in the upper part of the vestibular branch of the eighth nerve and can affect the cochlear branch, too. This tumor is generally unilateral except for patients with neurofibromatosis type two who develop

multiple and bilateral tumors [1, 2]. Schwannoma is a benign, solitary, and slowly progressive encapsulated tumor [3]. Over 90% of cases are presented as acoustic schwannoma, and they originate very rarely from primarily motor nerves [4].

Schwannoma in the head and neck region is rather uncommon [5]. Schwannoma is usually a true encapsulated painless single lesion with a smooth surface [6]. Histopathologically, five schwannoma variants have been

## \* Corresponding Author:

Elham Nazar, MD.

Address: Department of Pathology, Shariati Hospital, Tehran University of Medical Sciences, Tehran, Iran.

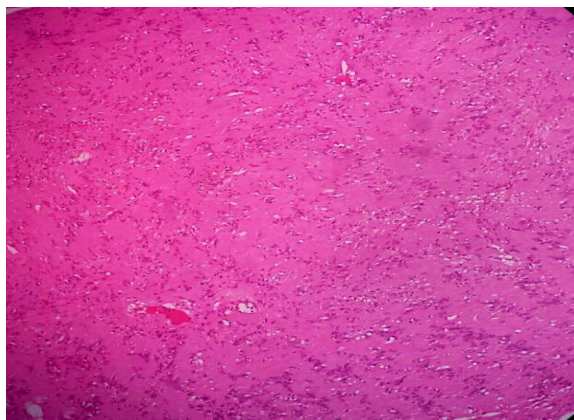
E-mail: [elhamnazar@yahoo.com](mailto:elhamnazar@yahoo.com)

explained: common, plexiform, cellular, epithelioid, and ancient [7]. Herein, we describe an upper lip soft tissue mass in a patient diagnosed as schwannoma.

### Case Presentation

A 30-year-old male patient was referred by a surgeon to Oral and Maxillofacial Surgery Department of Shariati Hospital, affiliated to Tehran University of Medical Sciences in January 2018. The chief complaint of the patient was asymptomatic mass in his upper lip since the last ten years with recent size enlargement. The patient's medical and family history was unremarkable. The extraoral examination was normal. Intraoral examination revealed upper lip enlargement. A firm and nontender mass, measuring approximately three cm in diameter was seen covered by normal mucosa. No neurological abnormality was noted. Routine biochemistry and blood cell count, as well as urine analysis, were requested that all of the results were within normal range.

After surgery, the specimen was sent for histopathologic examination. On macroscopic examination, an encapsulated well-defined ovaloid mass with the smooth external surface was seen in which the cut section showed homogenous white-gray surface. Microscopic examination revealed encapsulated soft tissue spindle cell lesion with cellular fibrillary areas (Antoni A) and paucicellular microcystic areas (Antoni B) (Figure 1). There were also paucinuclear areas surrounded by clusters of nuclei (verocay body) (Figure 2). Also mitotic activity was not readily apparent. Based on these findings, the diagnosis of schwannoma was made.



**Figure 1.** Microscopic examination revealed spindle cell lesion with cellular fibrillary areas (Antoni A) and paucicellular microcystic areas (Antoni B). There were also paucinuclear areas surrounded by clusters of nuclei (verocay body) (H&E ×10)

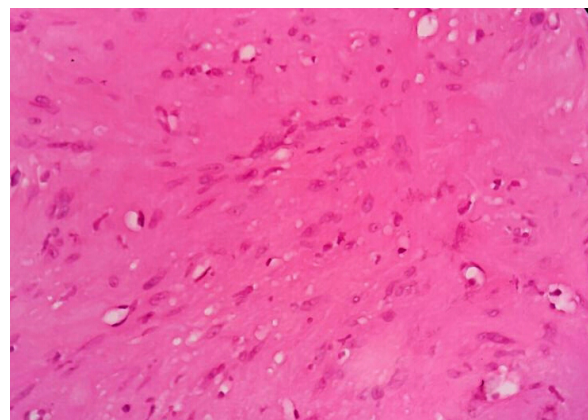
### Discussion

Upper lip schwannoma is a rare soft tissue mass, which is encapsulated and well-demarcated from the surrounding tissues [8]. Schwannomas are commonly found in the soft tissues of the head and neck region, but only 1-12% of them are located in the oral cavity. Most of them are located in the tongue or on the floor of the mouth, and very rarely in the hard palate [9]. Only a few schwannomas have been reported in other locations in the head and neck areas [10].

Histologically this tumor is composed of spindle cells forming highly cellular areas (Antoni A) and less cellular area (Antoni B). Verocay bodies, which are cellular eosinophilic zones, are regularly seen [11]. Neurofibromatosis type two is a tumor susceptible disorder presented by the development of multiple schwannomas and meningiomas, and many patients develop bilateral schwannoma of the superior vestibular branch of the eighth cranial nerve, but schwannoma in patients without neurofibromatosis type two is usually single [2].

Schwannoma is usually curable by complete enucleation [12]. In the head and neck soft tissue, schwannomas are rare with the majority of the tumors seen on the tongue followed by other locations, like the palate, buccal mucosa, lips, and gingiva. A systematic review by Salehnejad et al. presented 29 cases with schwannoma during 1950–2016 in intraoral location [8]. Another search in English literature from 1966 to 2002 revealed only 6 documented cases of schwannoma of the lip [12].

Although uncommon, schwannoma should be taken into consideration in the differential diagnosis of any upper lip mass for both pathologists and surgeons.



**Figure 2.** Microscopic examination revealed bland-looking wavy spindle cell with no atypia (H&E ×40)

## Ethical Considerations

### Compliance with ethical guidelines

All ethical principles were considered in this article.

### Funding

This research did not receive any specific grant from funding agencies in the public, commercial, or not-for-profit sectors.

### Conflict of interest

The authors declared no conflict of interest.

### Acknowledgements

The authors would like to express their appreciation to Department of pathology, Shariati Hospital, Tehran University of Medical Sciences, Tehran, Iran.

## References

- [1] Rouzbahani M. Vestibular schwannoma. *Audiology*. 2000; 8(1-2):36-9.
- [2] Evans DR. Neurofibromatosis type 2 (NF2): A clinical and molecular review. *Orphanet Journal of Rare Diseases*. 2009; 4(1):16. [DOI:10.1186/1750-1172-4-16] [PMID] [PMCID]
- [3] Aslan G, Cinar F, Cabuk FK. Schwannoma of the submandibular gland: A case report. *Journal of Medical Case Reports*. 2014; 8:231. [DOI:10.1186/1752-1947-8-231] [PMID] [PMCID]
- [4] Sahoo K, Shaha PR, Khetawat R, Ilyas MA, Khairnar GR. Solid-Cystic hypoglossal nerve schwannoma with fluid-fluid level: A rare case report. *Journal Of Clinical And Diagnostic Research*. 2016; 10(12):TD06-8. [DOI:10.7860/JCDR/2016/23337.9094] [PMID] [PMCID]
- [5] Yamazaki H, Kaneko A, Ota Y, Tsukinoki K. Schwannoma of the mental nerve: Usefulness of preoperative imaging: A case report. *Oral Surgery, Oral Medicine, Oral Pathology, Oral Radiology, and Endodontology*. 2004; 97(1):122-6. [DOI:10.1016/S1079-2104(03)00462-1] [PMID]
- [6] Moradzade Khiavi M, Taghavi Zenouz A, Mesgarzadeh AH, Sabetmeh O, Mahmoudi SM, Kouhsoltani M. Schwannoma in the midline of hard palate: A case report and review of literature. *Journal of Dental Research, Dental Clinics, Dental Prospects*. 2014; 8(2):114-7. [DOI:10.5681/joddd.2014.021] [PMID] [PMCID]
- [7] Chen CY, Wang WC, Chen CH, Chen YK, Lin LM. Ancient schwannoma of the mouth floor-A case report and review. *Oral Oncology Extra*. 2006; 42(8):281-5. [DOI:10.1016/j.ooe.2006.07.002]
- [8] Salehinejad J, Sahebhasagh Z, Saghafi S, Sahebhasagh Z, Amiri N. Intraoral ancient schwannoma: A systematic review of the case reports. *Dental Research Journal*. 2017; 14(2):87-96. [PMID] [PMCID]
- [9] Gainza-Cirauqui ML, Eguia-Del Valle A, Martinez-Conde R, Coca-Meneses JC, Aguirre-Urizar JM. Ancient schwannoma of the hard palate. an uncommon case report and review. *Journal of Clinical and Experimental Dentistry*. 2013; 5(1):e62-5. [DOI:10.4317/jced.50950] [PMID] [PMCID]
- [10] Bayindir T, Kalcioğlu MT, Kizilay A, Karadag N, Akarcay M. Ancient schwannoma of the parotid gland: A case report and review of the literature. *Journal of Cranio-Maxillo-Facial Surgery*. 2006; 34(1):38-42. [DOI:10.1016/j.jcms.2005.08.003] [PMID]
- [11] Subhashraj K, Balanand S, Pajaniammalle S. Ancient schwannoma arising from mental nerve. a case report and review. *Medicina oral, patologia oral y cirugia bucal*. 2009; 14(1):E12-4.
- [12] Yang SW, Lin CY. Schwannoma of the upper lip: Case report and literature review. *American Journal of Otolaryngology*. 2003; 24(5):351-4. [DOI:10.1016/S0196-0709(03)00065-6] [PMID]