



## Case Report

Journal Homepage: <http://crp.tums.ac.ir>

# Cutaneous Metastasis of Chondrosarcoma: A Case Report With Literature Review

Elham Nazar<sup>1</sup> , Alireza Ghanadan<sup>2</sup> 

1. Department of Pathology, Shariati Hospital, Tehran University of Medical Sciences, Tehran, Iran.

2. Department of Pathology, Imam Khomeini Complex Hospital, Tehran University of Medical Sciences, Tehran, Iran.



**Citation:** Nazar E, Ghanadan A. Cutaneous Metastasis of Chondrosarcoma: A Case Report With Literature Review. Case Reports in Clinical Practice .2019; 4(3):73-77.

**Running Title:** Metastatic Chondrosarcoma to Skin

**Article info:****Received:** 10 July 2019**Revised:** 23 July 2019**Accepted:** 21 August 2019**Keywords:**Chondrosarcoma; Metastasis;  
Skin; Survival**ABSTRACT**

The metastasis to respiratory system secondary to chondrosarcoma is a common finding; however, metastasis to other organs such as skin or bones is much less common. In the current report, we described a case with the history of chondrosarcoma of the mandible that recently referred with the metastatic lesions in her scalp skin. Our case is a female patient that its secondary metastasis occurred only 4 months after her initial tumor diagnosis. More interestingly, among all baseline laboratory parameters, only inflammatory biomarkers increased as the nonspecific diagnostic indices. In other words, the accurate diagnosis of metastasis to bone following chondrosarcoma may be delayed and even masked with early inflammatory reactions. On the whole, in all patients who suffer from chondrosarcoma, early metastasis to skin or bones should be considered, especially when inflammatory indices are high.

**Introduction**

Chondrosarcoma is one of the most frequent malignant tumors of the skeletal system accounting for about 20% of all types of sarcomas [1]. This tumor frequently appears in the early fourth decade of life with the male predominance. The pattern of the tumor progression, metastasis, is directly related to tumor grading so that metastasis of chondrosarcoma is infrequent in low-grade category

(grades I to II). While half of the patients with grade III and almost all those with a dedifferentiated form of cancer suffer from metastatic lesions [2].

In the patients with high-grade chondrosarcoma, the metastasis to respiratory system is a common finding, and less so in the regional lymph nodes and the liver [3].

However, metastasis to other tissues such as skin or bones is much less common. In the current report, we presented

**\* Corresponding Author:****Elham Nazar, MD.****Address:** Department of Pathology, Shariati Hospital, Tehran University of Medical Sciences, Tehran, Iran.**E-mail:** [elhamnazar@yahoo.com](mailto:elhamnazar@yahoo.com)

a case with the history of chondrosarcoma of the mandible that recently referred with the scalp metastatic lesions.

### Case Presentation

Our case is a 39-year-old woman with a history of mandibular chondrosarcoma four months before admission. In her pathological report on the time of tumor diagno-

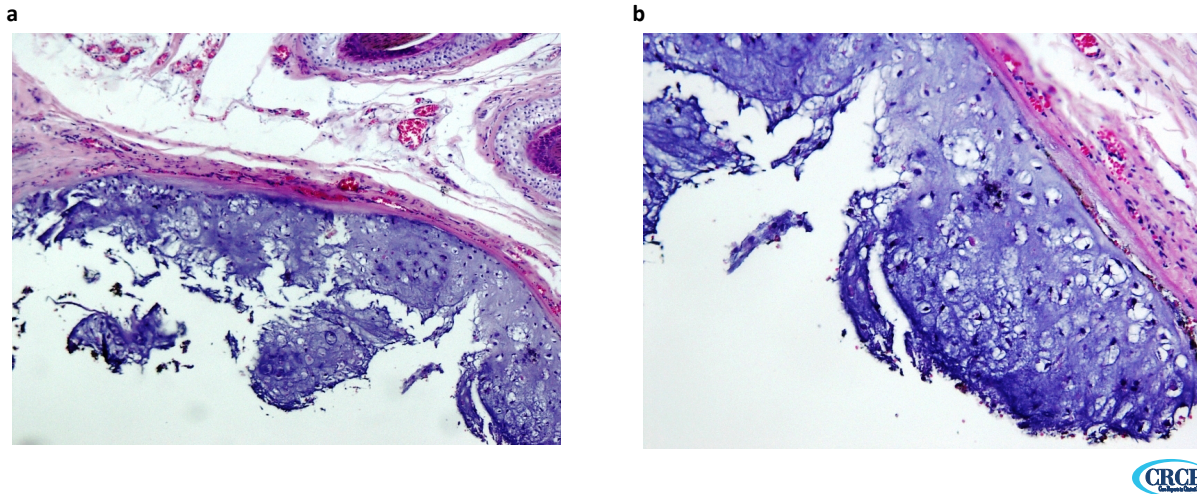
sis, mandibular lytic bone lesions were macroscopically appeared. In the microscopic examination, foci with marked cellularity, pleomorphism, and bizarre tumor giant cells with mitotic pattern were seen confirming conventional mandibular chondrosarcoma grade II. The patient was referred to our hospital four months after the first assessment with the bony pain, especially at the scalp point. In laboratory analysis on admission, in-

**Table 1.** Summary of metastatic chondrosarcoma reports to the skin from 1967 to 2014

Author (y) Reference	Age (y) / Gender	Primary Tumor	Metastatic Region(s)	Interval Period*	Survival Length**/ Outcome
Cruikshank (1945) [8]	66/M	Middle pharynx	Face, neck, trunk	26 mon	Unknown
Fromson (1967) [9]	30/M	Fibular head	Lung, right thumb, left ring finger	NS	3 mon
King (1978) [10]	31/F	Scapula	Vulva, right thumb, right middle toe, scalp, heel, gingiva	30 mon	2 mon/DOD
Kerin (1983) [11]	20/M	Site not specified	Left ring finger	NS	Unknown
Sherr (1986) [12]	47/F	Left ischium	Nose, supraorbital region, buttock, hemipelvectomy scar	103 mon	5 mon
Karabela-Bouropoulou (1986) [13]	41/F	Right thumb (proximal phalanx)	Abdomen, chest, frontal	68 m	2 mon/DOD
Amadio (1987) [14]	32/M; 59/M	Humerus; Femur	Left thumb; Left thumb	NS NS	5 mon/NS 26 mon/NS
Bashi (1989) [15]	17/M	Heart	Scalp	2 wk	12 mon/DOD
Leal-Khouri (1990) [16]	85/M	Left shoulder	Both lungs, nose	115 mon	8 mon/DOD
Lambert (1992) [17]	36/M	Right femur	Lung, bilateral ring finger	19 mon	5 mon/DOD
Malek (1994) [7]	66/F	Right tibia	Forearm	84 mon	2 wk/alive
Damron (1995) [18]	76/F	The fifth metacarpal bone	Forearm	6 mon	6 mon/alive
Aramburu-González (1999) [19]	64/M	Forearm soft tissue	Face	15 mon	28 mon/alive
Arce (2000) [20]	69/M	Right humerus	Right inguinal, infra mammary	Initial present with metastasis	21 d/DOD
Ozcanli (2006) [21]	47/M	Proximal part of humerus	Both hands	24 mon	18 mon/DOD
Shah (2007) [6]	60/M	Lung	Anterior abdominal wall, left para spinal region and left thigh	26 mon	66 mon/alive
Stanisz (2012) [22]	51/M	Left os ileum	Lung, left atrium, back, right upper leg	8 mon	<12 mon/DOD
Domínguez-Durán (2014) [23]	60/M	Larynx	Chin, nose	30 mon	35 mon/DOD
Our case (2017)	30/F	Mandible	Scalp	4 mon	24 mon/alive

\* Period between primary tumor and metastasis to the skin; \*\*Survival length with skin metastasis

DOD: Died of disease; NS: Not stated



**Figure 1.** Metastasis chondrosarcoma in dermis from our patient

A. Microscopic examination revealed well-defined nodules in deep dermis pushing pilosebaceous units (H&E  $\times 10$ ); B. Cartilaginous lobules are composed of atypical chondrocytes with large hyperchromatic nuclei located in the lacunae and bluish chondroid matrix (H&E  $\times 20$ )

creased ESR (50mm/h) and positive CRP (3+) were the only finding of the recent manifestation.

Other laboratory parameters were normal. Hence, the patient was candidate for pathological assessment of suspected metastatic lesions of the primary tumor. In gross pathology, frontal lesion, including a piece of irregular skin tissue measuring 0.8 $\times$ 0.3 $\times$ 0.3cm and scalp mass consisting of two pieces of pale-tan brownish tissue measuring 5 $\times$ 3 $\times$ 1cm were revealed. Histopathologic examination revealed well-circumscribed cartilaginous lobules in deep dermis composed of atypical chondrocytes with mild to moderate pleomorphism and irregular hyperchromatic nuclei located in the lacunae within a bluish chondroid matrix (Figure 1). Microscopically, metastatic lesions of chondrosarcoma to the skin in the frontal zone and anterior scalp margin were confirmed. Thus the patient was scheduled for surgical resection with clear margins in combination with chemotherapy and radiotherapy approaches.

## Discussion

Metastasis to the lungs due to chondrosarcoma is a common finding, but its metastasis to other organs such as skin or skeletal system rarely occurs. Distant metastasis also develops mostly secondary to primary chondrosarcoma than to secondary type. Moreover, the rate of distant metastasis is higher in those with local recurrence than in those without local recurrence [4]. In conventional chondrosarcoma, the risk of metastasis is directly dependent on the tumor grade so that grade I tumor does not metastasize, while about two-thirds of

grade III tumors do. In the dedifferentiated type of tumor, hematogenous metastasis occurs in most patients with a considerable low long-term survival [4].

In some types of tumor such as clear cell chondrosarcoma, distant metastasis can occur even in a low-grade tumor. Reviewing the literature shows rare reports of bone and cutaneous metastatic lesions secondary to chondrosarcoma [4]. In other words, although cutaneous lesions have been recently reported, bone metastasis is very rare. Similarly, Ragsdale et al. reported a 22-year-old male with osteosarcoma of the pelvis and metastasis to the lungs and chest wall who developed a clinically unsuspected solitary cutaneous metastasis in the scalp whose incisional biopsy disclosed a solid tan nodule of chondro-osseous sarcoma [5].

In another report by Shah et al. a 60-year-old man had chondrosarcoma of the lung with two local recurrences, including recurrent cutaneous metastases and skeletal metastasis [6]. Malek et al. reported a case of a solitary subcutaneous metastasis from chondrosarcoma that occurred 7 years after excision of the primary neoplasm [7]. Table 1 presents the published case reports on metastatic chondrosarcoma to skin up until now. Most patients are men (F/M: 6/20), and the primary tumors were mostly located in the peripheral bones.

The interval period between primary tumor and metastasis to skin varies from two weeks to 115 months, and the length of survival varies from two weeks to 66 months. Four of 20 cases were extra-skeletal chondrosarcoma (aris-

ing from heart, lung, larynx, and soft tissue) and one patient initially presents with metastasis to skin.

Contrary to previous reports and as a more rare case, our case is a young woman whose primary tumor confined to a central bone (mandible), and its secondary metastasis occurred only four months after initial tumor diagnosis. More interestingly, among all baseline laboratory parameters, only inflammatory biomarkers were high as the nonspecific diagnostic indices. In other words, the accurate diagnosis of metastasis following chondrosarcoma may be delayed and even masked with early inflammatory reactions. On the whole, in all patients who suffer from chondrosarcoma, early metastasis to skin or bones should be considered, especially when inflammatory indices are high.

## Ethical Considerations

### Compliance with ethical guidelines

All ethical principles were considered in this article.

### Funding

This research did not receive any specific grant from funding agencies in the public, commercial, or not-for-profit sectors.

### Conflict of interest

There was no ethical considerations to be considered in this research.

### Acknowledgements

The authors would like to express their appreciation to Department of Pathology, Shariati and Imam Khomeini Complex Hospital, Tehran University of Medical Sciences, Tehran, Iran.

## References

- [1] Nota SP, Braun Y, Schwab JH, van Dijk CN, Bramer JA. The identification of prognostic factors and survival statistics of conventional central chondrosarcoma. *Sarcoma*. 2015; 2015:623746. [DOI:10.1155/2015/623746] [PMID] [PMCID]
- [2] Kim HS, Bindiganavile SS, Han I. Oncologic outcome after local recurrence of chondrosarcoma: Analysis of prognostic factors. *Journal of Surgical Oncology*. 2015; 111(8):957-61. [DOI:10.1002/jso.23925] [PMID]
- [3] Leddy LR, Holmes RE. Chondrosarcoma of bone. *Cancer Treatment and Research*. 2014; 162:117-30. [DOI:10.1007/978-3-319-07323-1\_6] [PMID]
- [4] Czerniak B. *Dorfman and Czerniak's bone tumors*. St Louis: Mosby; 1998.
- [5] Ragsdale MI, Lehmer LM, Ragsdale BD, Chow WA, Carson RT. Cutaneous metastasis of osteosarcoma in the scalp. *The American Journal of Dermatopathology*. 2011; 33(6):e70-3. [DOI:10.1097/DAD.0b013e318214a7ea] [PMID]
- [6] Shah ND, Diwanji SR. Primary chondrosarcoma of the lung with cutaneous and skeletal metastases. *Singapore Medical Journal*. 2007; 48(7):e196-9. [PMID]
- [7] Malek B, Thomas M, Nilles M, Schill WB. Solitary subcutaneous metastasis of a chondrosarcoma. *Hautarzt*. 1994; 45(10):722-4. [DOI:10.1007/s001050050158] [PMID]
- [8] Cruickshank AH. Chondrosarcoma of a phalanx with cutaneous metastasis. *Journal Pathology Bacteriology* 1945; 57(1):144-45. [DOI:10.1002/path.1700570118]
- [9] Fromson A. Metastatic chondrosarcoma of the hand. report of a case. *Clinical Orthopedic Relations Research* 1967; 53:155-160. [DOI:10.1097/00003086-196707000-00018] [PMID]
- [10] King DT, Gurevitch AW, Hirose FM. Multiple cutaneous metastases of a scapular chondrosarcoma. *Archives of Dermatology*. 1978; 114(4):584-6. [DOI:10.1001/archderm.1978.01640160062018] [PMID]
- [11] Kerin R. Metastatic tumors of the hand: A review of the literature. *The Journal of Bone and Joint Surgery American Volume*. 1983; 65(9):1331-5. [DOI:10.2106/00004623-198365090-00016] [PMID]
- [12] Sherr DL, Fountain KS, Kalb RE. Cutaneous metastases from chondrosarcoma. *Journal of Dermatologic Surgery and Oncology*. 1986; 12(2):146-9. [DOI:10.1111/j.1524-4725.1986.tb01445.x] [PMID]
- [13] Karabela-Bouropoulou V, Patra-Malli F, Agnantis N. Chondrosarcoma of the thumb: An unusual case with lung and cutaneous metastases and death of the patient 6 years after treatment. *Journal of Cancer Research and Clinical Oncology*. 1986; 112(1):71-4. [DOI:10.1007/BF00394943]
- [14] Amadio PC, Lombardi RM. Metastatic tumors of the hand. *Journal of Hand Surgery* 1987; 12(2):311-6. [DOI:10.1016/S0363-5023(87)80299-X] [PMID]
- [15] Bashi VV, Walter A, John S. Primary chondrosarcoma of heart. *Indian Journal of Chest Diseases & Allied Sciences*. 1989; 31(3):203-6. [PMID]
- [16] Leal-Khoury SM, Barnhill RL, Baden HP. An unusual cutaneous metastasis of a chondrosarcoma. *Journal of Cutaneous Pathology*. 1990; 17(5):274-7. [DOI:10.1111/j.1600-0560.1990.tb00102.x] [PMID]
- [17] Lambert D, Escallier F, Collet E, Dallac S, Maingon P, Mayer F, et al. Distal phalangeal metastasis of a chondrosarcoma presenting initially as bilateral onycholysis. *Journal of Clinical & Experimental Dermatology Research*. 1992; 17:463-5. [DOI:10.1111/j.1365-2230.1992.tb00263.x] [PMID]
- [18] Damron TA, Rock MG, Unni KK. Subcutaneous involvement after a metacarpal chondrosarcoma. case report and review of literature. *Clinical Orthopaedics and Related Research*. 1995; 316:189-94. [DOI:10.1097/00003086-199507000-00026] [PMID]

- [19] Aramburu-Gonzalez JA, Rodriguez-Justo M, Jimenez-Reyes J, Santonja C. A case of soft tissue mesenchymal chondrosarcoma metastatic to skin, clinically mimicking keratoacanthoma. *The American Journal of Dermatopathology*. 1999; 21(4):392-4. [DOI:10.1097/0000372-199908000-00016] [PMID]
- [20] Arce FP, Pinto J, Portero I, Echevarria S, Val-Bernal JF. Cutaneous metastases as initial manifestation of dedifferentiated chondrosarcoma of bone. an autopsy case with review of the literature. *Journal of Cutaneous Pathology*. 2000; 27(5):262-7. [DOI:10.1034/j.1600-0560.2000.027005262.x] [PMID]
- [21] Ozcanli H, Oruc F, Aydin AT. Bilateral multiple cutaneous hand metastases of chondrosarcoma. *Journal of the European Academy of Dermatology and Venereology*. 2006; 20(7):893-4. [DOI:10.1111/j.1468-3083.2006.01584.x] [PMID]
- [22] Stanisz H, Pföhler C, Anagnostakos K, Kohn D, Vogt T, Müller CS. Metastatic chondrosarcoma - current aspects of a rare event in dermatopathology. *Journal of Cutaneous Pathology*. 2012; 39(4):467-70. [DOI:10.1111/j.1600-0560.2011.01806.x] [PMID]
- [23] Domínguez-Durán E, Menoyo-Bueno A, González-Cantón J, Abrante-Jiménez A. Cutaneous metastases of laryngeal chondrosarcoma. *Acta Otorrinolaringol (English Edition)*. 2014; 65(6):373-4. [DOI:10.1016/j.otoeng.2014.10.008]