



# Granulomatous Mastitis and Sarcoidosis Differential Diagnosis: A Case Report



Sepehr Sahraiyani , Mahsa Abbaszadeh\* , Nasim Khajavi Rad, Sahar Karimpour Reyhan, Ali Afshari

Department of Internal Medicine, Imam Khomeini Hospital Complex, Tehran University of Medical Sciences, Tehran, Iran.

Use your device to scan and read the article online



**Citation:** Sahraiyani S, Abbaszadeh M, Khajavi Rad N, Karimpour Reyhan S, Afshari A. Granulomatous Mastitis and Sarcoidosis Differential Diagnosis: A Case Report. *Case Reports in Clinical Practice* .2019; 4(3):64-68.

**Running Title:** Granulomatous Mastitis and Sarcoidosis Differential Diagnosis



## Article info:

**Received:** 24 June 2019

**Revised:** 31 July 2019

**Accepted:** 17 August 2019

## Keywords:

Sarcoidosis; Granulomatous mastitis; Breast; Erythema nodosum

## ABSTRACT

Granulomatous mastitis is a pathological diagnosis with a variety of causes, and its treatment depends on the underlying cause. We report a case of granulomatous mastitis in a 25-year-old woman admitted with erythema nodosum and an unresponded acute inflammatory mastitis to treatment. It was challenging for us to make a definite diagnosis between sarcoidosis and idiopathic lobular granulomatous mastitis for her. In the end, our diagnosis was sarcoidosis because of dactylitis we found in her physical examination which responded dramatically to nonsteroidal anti-inflammatory drug treatment. We started therapy with corticosteroids and immunosuppressant drugs and offered her continuous follow-up.

## Introduction

**G**ranulomatous mastitis is a pathological diagnosis in which the breast biopsy shows inflammatory granulomatous reaction and formation [1]. It can be a primary disease (idiopathic lobular granulomatous mastitis) or secondary to other systemic granulomatous

diseases like sarcoidosis, tuberculosis, and vasculitis, to name but a few. In the clinical presentation, it can be easily confused with other conditions like breast cancer, non-granulomatous infection, and trauma. Treatment depends on underlying cause, so it is essential to make a definite diagnosis. Sometimes making a deferential diagnosis between sarcoidosis and idiopathic lobular granulomatous mastitis is challenging. However, the

## \* Corresponding Author:

**Mahsa Abbaszadeh, MD.**

**Address:** Department of Internal Medicine, Imam Khomeini Hospital Complex, Tehran University of Medical Sciences, Tehran, Iran.

**E-mail:** [m-abbaszadeh@sina.tums.ac.ir](mailto:m-abbaszadeh@sina.tums.ac.ir)

critical issue is that in any patient with prolonged and unresponded mastitis to treatment, we must consider granulomatous diseases.

### Case Presentation

Our case was a 25-year-old Iranian woman admitted to Imam Khomeini Hospital Complex because of bilateral painful erythematous skin lesions in lower extremities. The patient's chief complaint was bilateral palpable shiny erythematous, non-ulcerative, non-scaling lesions with tenderness on the front part of shins and feet appeared a week ago. The diameters of these lesions ranged from 2-7cm. The borders were not well-defined. She also had swelling and pain in her entire right index finger which started a few days ago. The pain and tenderness were from proximal interphalangeal joint to tip, and she could not flex or extend her finger.

Besides, she had mastitis in her left breast which started 40 days ago and failed to treatment with cloxacillin and metronidazole. At first, her tenderness and erythema were limited to superior-lateral quadrant of the left breast, but it then extended to areola and inferior-lateral quadrant. Swelling, hardness, and enlargement in the inferior-lateral quadrant and left breast nipple retraction were also noted. She lost 2kg in the last month with decreased appetite. There was no report of any recent flu-like symptoms, respiratory, urinary or gastrointestinal infection, cough, cardiovascular disease, sinusitis, trauma, and recent travel.

In the past medical history, she reported having hypothyroidism since three years ago, which was treated with levothyroxine (0.1mg/d), but she stopped treatment from four months ago on her own. There was no report of recent hospitalization or surgical procedures. Habitual history like smoking, alcohol, or drug abuse was negative. Her vaccination course was completed. Familial history was negative for any specific diseases. She had no allergies. On examination, the patient was alert and fully oriented. Her body temperature was 38°C (oral), blood pressure 110/70mm Hg, pulse rate 90 beats per minute, and respiratory rate 18 breaths per minute. She was pale but not icteric.

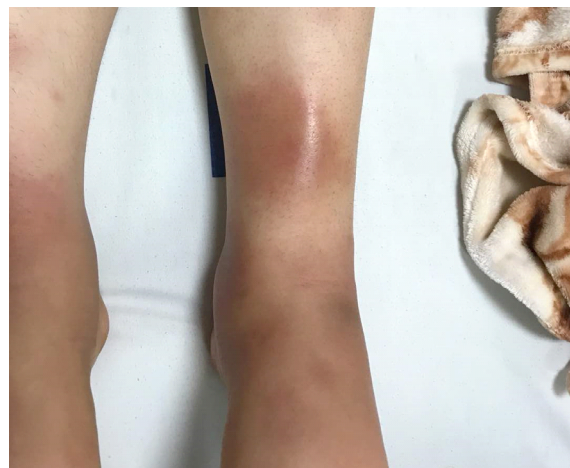Her oral hygiene was good. We found no lesion, mass, or lymphadenopathy. In the eye examination, there was no asymmetry, exophthalmia, conjunctivitis, or xerophthalmia. Her red reflex was normal with no uveitis or retinal abnormalities, cataract or increased intraorbital pressure. Lung, heart, and abdominal examination were completely normal. According to upper limb examina-

tion, her entire right index finger was sausage-like and had swelling, tenderness, and erythema with decreased range of motion in passive and active movements in joints. In lower limb examination, multiple palpable nodular lesions with dimensions of 2-7cm were found which had tenderness and erythema suggesting erythema nodosum.

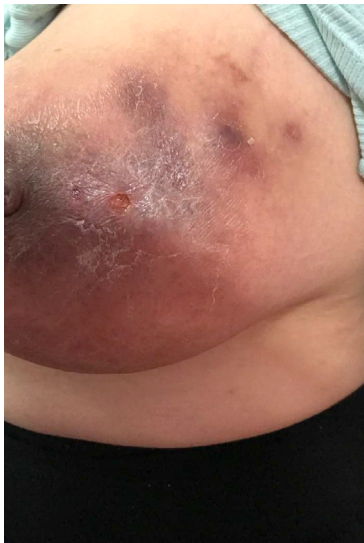In breast examination, left breast was asymmetric with dark reddish skin, swelling, and tenderness mainly observed in the inferior-lateral quadrant and periareolar zone. In palpation, tense, hard, and warm mass was found in inferior-lateral quadrant. Nipple retraction was noticeable. There was no pus or blood secretion.

In the first step, we took complete blood count to assess any possible comorbidity, beta-HCG for pregnancy, PPD test for tuberculosis, viral markers (Hbs Ag, anti-HCV, and HIV Ag/Ab) and ultrasonography to evaluate her unresponded acute mastitis which prolonged 40 days with treatment. PPD test, beta-HCG, and viral markers were all reported negative. The rheumatic factor was also negative. Left breast ultrasonography showed parenchymal distortion in superior-lateral quadrant.

Mammary glands and Cooper's ligament were normal. Skin thickness was normal, too. There was no solid or cystic mass, also no acoustic shadow change or calcification, in the normal axillary zone. Her blood test results were the following: white blood cells,  $8.3 \times 10^3/\mu\text{L}$  (neutrophils 73%; lymphocytes 19%); platelets,  $196 \times 10^3/\mu\text{L}$ ; red blood cells,  $3.22 \times 10^6/\mu\text{L}$ ; hemoglobin (HGB): 9.5g/dl; MCV: 88, erythrocyte sedimentation rate: 86; and C-reactive protein: 98



**Figure 1.** Multiple tender and palpable lesions on the lower limb



**Figure 2.** Left breast mastitis

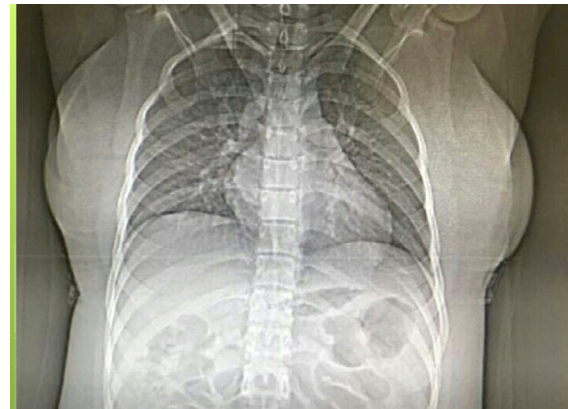
In the second step, because of low hemoglobin count, we requested Iron profile with the following results: Fe/iron: 20g/L, Ferritin: 162ng/mL, Total Iron-binding Capacity (TIBC): 181  $\mu$ g/dL, suggesting anemia due to chronic disease. To evaluate breast changes reported in breast ultrasonography and resistance acute mastitis and to rule out malignancy, we requested biopsy from the left breast with the following report: Breast tissue with a mixed inflammatory reaction, including scattered granuloma formation concentrated in lobules. Ziehl-Neelsen staining was negative. No tumor was seen.

In the third step, we requested chest x-ray and spiral CT-scan to see if there is any mediastinal or lung involvement. The results indicated no pericardial or pleural effusion, no lymphadenopathy or bone lesion. The increased breast density and skin thickness in the left breast with at least a 12mm axillary lymph node were also observed.

We also checked the calcium profile of the patient because of granuloma finding, and the results were as follows: calcium: 8.6mg/dl, phosphorous: 2.6mg/dl, albumin: 4.0g/dl. We also measured the angiotensin converting enzyme level, which was within normal range and IGRA test result was negative.

## Discussion

According to our findings based on history and physical exam, our top differential diagnoses were erythema nodosum and mastitis, tuberculosis, sarcoidosis, idiopathic lobular granulomatous mastitis, streptococcus



**Figure 3.** The patient's normal chest x-ray

mastitis, malignant breast tumor, vasculitis like Wegner disease, rheumatic arthritis, viral hepatitis, HIV infection, and lymphoma.

In the first step, the PPD test was negative, and the patient had no contact with infected known cases, and she had no risk factor. Also, her rheumatic factor was negative, besides she had no family history, joint pain, or morning stiffness. Viral markers were also negative. So, we rule out rheumatic arthritis and viral infection. Because of high tuberculosis prevalence in Iran, we requested IGRA test which was also negative. Her complete blood count indicated anemia and based on her Iron profile, her anemia was due to chronic disease. Because of left breast changes in ultrasonography report, we requested biopsy to rule out malignancy which reported granuloma without any malignancy changes.

So, our differential diagnosis went down to granulomatous diseases like sarcoidosis, idiopathic lobular granulomatous mastitis, and vasculitis like Wegner disease. We examined the patient with regard to sinusitis symptoms, postnasal drip, dry nose or nasal bleeding but she had none of these symptoms. Also, her head and neck examination were normal. So, our differential diagnosis was narrowed down to sarcoidosis and idiopathic lobular granulomatous mastitis.

Idiopathic Lobular Granulomatous Mastitis (ILGM) is a benign inflammatory disorder with unknown etiology. It is more common in parous young women. It can be presented by breast mass, abscess, inflammation, and mammary duct fistula. The diagnosis is based on pathology findings and ruling out other causes of granulomatous mastitis [2]. The diagnose and managing this disease is a challenge for clinicians and requires consultation with experts in several specialties [3]. Treatment includes surgery, medications like cor-

ticosteroids and immunosuppressant drugs with continuous follow-up [4, 5].

Sarcoidosis is a non-caseating granulomatous disease like ILGM which involves multiple organs and systems and is usually developed before the age of 50, with the peak incidence at the age range of 20-39. Its prevalence is higher among women [6, 7]. Sarcoidosis etiology is unknown, but the immune response to environmental stimuli like infections in people with genetic susceptibility is mentioned as its probable causes [8]. Signs and symptoms of sarcoidosis depend on the affected organ; approximately (5%) of cases are asymptomatic [9].

In symptomatic patients, lungs and skin involvement are more common. Breast involvement is sporadic (account for less than one percent of cases) and it can be confused with other conditions like tuberculosis, benign or malignant breast masses, and idiopathic lobular granulomatous mastitis [10]. Diagnosis is partly based on symptoms and excluding other possible causes. Para-clinical laboratory tests and biopsy can also be used to support the diagnosis [11, 12].

Sarcoidosis treatment depends on the severity of symptoms and organs involvement. Most patients only require symptomatic therapy with NSAID or just continuous follow-up without any medication. Corticosteroids and drugs like methotrexate, TNF- $\alpha$  inhibitors, and hydroxychloroquine can also be used for treatment [13]. Prognosis varies among patients and depends on the severity of symptoms and organ involvement.

So, both diseases can be presented by erythema nodosum and inflammatory mastitis. Both are granulomatous diseases whose diagnosis is based on history taking and ruling out other causes. Both diseases incidence peaks are similar and more common in women, and treatment for both conditions is similar. Maybe ILGM is the initial presentation of sarcoidosis, and other symptoms develop during follow up. Due to dactylitis which dramatically responded to NSAID and cannot be seen in ILGM, our diagnosis favored to sarcoidosis. So, we started treatment for sarcoidosis as our primary diagnosis with prednisolone 10mg PO BID, methotrexate 2.5 mg PO once per week, folic acid 1mg daily and 2-week follow up to adjust doses and assess her response to treatment. We continued the patient's follow up to see whether other symptoms of sarcoidosis would appear.

In any patient with prolonged mastitis and erythema nodosum, clinicians must consider granulomatous diseases. Sarcoidosis is a multisystem disease and can be

presented by any symptom with no standard paraclinical test for diagnosis. The probability of sarcoidosis involvement in breast tissue is less than (1%), so it is infrequent, and we must be looking for other symptoms, especially lung and skin involvement. However, there are few case reports in which sarcoidosis is presented only in the breast mass or lesion, so we must suspect sarcoidosis in any patient with prolonged mastitis.

## Ethical Considerations

### Compliance with ethical guidelines

All ethical principles were considered in this article.

### Funding

This work is supported, in part, by the Imam Khomeini Hospital Complex research center.

### Conflict of interest

The authors declared no conflict of interest.

## References

- [1] Vinayagam R, Cox J, Webb L. Granulomatous mastitis: A spectrum of disease. *Breast Care (Basel)*. 2009; 4(4):251-4. [DOI:10.1159/000229541] [PMID] [PMCID]
- [2] Zhou F, Yu LX, Ma ZB, Yu ZG. Granulomatous lobular mastitis. *Chronic Diseases and Translational Medicine*. 2016; 22(1):17-21 [DOI:10.1016/j.cdtm.2016.02.004] [PMID] [PMCID]
- [3] Garcia-Rodriguez JA, Pattullo A. Idiopathic granulomatous mastitis: A mimicking disease in a pregnant woman: A case report. *BMC Research Notes*. 2013; 6:95. [DOI:10.1186/1756-0500-6-95] [PMID] [PMCID]
- [4] Akbulut S, Yilmaz D, Bakir S. Methotrexate in the management of idiopathic granulomatous mastitis: Review of 108 published cases and report of four cases. *The Breast Journal*. 2011; 17(6):661-8. [DOI:10.1111/j.1524-4741.2011.01162.x] [PMID]
- [5] Dehertogh DA, Rossof AH, Harris AA, Economou SG. Prednisone management of granulomatous mastitis. *The New England Journal of Medicine*. 1980; 303(14):799-800. [DOI:10.1056/NEJM198010023031406] [PMID]
- [6] Rybicki BA, Major M, Popovich J Jr., Maliarik MJ, Iannuzzi MC. Racial differences in sarcoidosis incidence: A 5-year study in a health maintenance organization. *American Journal of Epidemiology*. 1997; 145(3):234-41. [DOI:10.1093/oxfordjournals.aje.a009096] [PMID]
- [7] Birnbaum AD, Rifkin LM. Sarcoidosis: Sex-dependent variations in presentation and management. *Journal of Ophthalmology*. 2014; 2014:236905. [DOI:10.1155/2014/236905] [PMID] [PMCID]

- [8] Baughman RP, Lower EE, du Bois RM. Sarcoidosis. *The Lancet*. 2003; 361(9363):1111-8. [DOI:10.1016/S0140-6736(03)12888-7] [PMID]
- [9] Kamangar N, Rohani P, Shorr AF, Peters SP, Talavera F, Rice TD, et al. (2014). Sarcoidosis treatment & management. Medscape Reference. Retrieved from: <https://emedicine.medscape.com/article/301914-clinical#showall>
- [10] Fiorucci F, Conti V, Lucantoni G, Patrizi A, Fiorucci C, Giannunzio G, et al. Sarcoidosis of the breast: A rare case report and a review. *European Review For Medical And Pharmacological Sciences*. 2006; 10(2):47-50. [PMID]
- [11] Govender P, Berman JS. The diagnosis of sarcoidosis. *Clinics in Chest Medicine*. 2015; 36(4):585-602. [DOI:10.1016/j.ccm.2015.08.003] [PMID]
- [12] Spagnolo P. Sarcoidosis: A critical review of history and milestones. *Clinical Reviews In Allergy & Immunology*. 2015; 49(1):1-5. [DOI:10.1007/s12016-015-8480-0] [PMID]
- [13] Baughman RP, Lower EE. Treatment of sarcoidosis. *Clinical Reviews In Allergy & Immunology*. 2015; 49(1):79-92. [DOI:10.1007/s12016-015-8492-9] [PMID]