



Case Report

Journal Homepage: <http://crp.tums.ac.ir>

A Three-Year-Old Boy With an Epinephrine Ampoule in the Stomach: A Case Report



Armen Malekiantaghi¹, Behzad Mohammadpour Ahranjani², Kambiz Eftekhari^{*}

1. Department of Pediatrics, Pediatric Gastroenterology and Hepatology Research Center, Bahrami Children's Hospital, Tehran University of Medical Sciences, Tehran, Iran.

2. Department of Pediatrics, Bahrami Children's Hospital, Tehran University of Medical Sciences, Tehran, Iran.



Citation Malekiantaghi A, Mohammadpour Ahranjani B, Eftekhari K. A Three-Year-Old Boy With an Epinephrine Ampoule in the Stomach: A Case Report. Case Reports in Clinical Practice. 2020; 5(2):43-46.

Running Title: Epinephrine Ampoule in the Stomach



Article info:

Received: 07 April 2020

Revised: 23 April 2020

Accepted: 07 June 2020

Keywords:

Epinephrine hydrochloride;
Endoscopy; Foreign body

ABSTRACT

Ingested Foreign Bodies (FB) frequently occur in pediatric patients. The most commonly ingested foreign bodies are coins, magnets, batteries, small toys, jewelry, buttons, and bones in decreasing order of frequency. A three-year-old boy referred to the emergency room with incidental ingestion of an ampoule of epinephrine. The radiography data demonstrated the location of the ingested ampoule in the stomach. The upper endoscopy was performed; however, the object had already passed through the pylorus. The following day, he passed the ampoule without complications. Our case was pretty unique because the most commonly ingested FBs in the pediatric population include coins followed by magnets, batteries, and so on. Asymptomatic patients having no dangerous FB could be observed until either presenting something abnormal or uneventfully passing the FB.

Introduction

Children with a history of Foreign Body (FB) ingestion frequently offer diagnostic and management challenges. Ingested and aspirated FBs frequently occur in pediatric patients [1]; most events are observed in children aged between 6 months and 3 years. Ap-

proximately 80%-90% of FBs in the gastrointestinal tract are passed spontaneously without complications, 10%-20% are removed endoscopically, and 1% require open surgery secondary to complications [2]. Although most objects pass easily through the intestines, entrapment could occur at the pylorus, the ligament of Treitz, and the ileocecal valve. Children with intestinal abnormalities, including congenital, functional, and postsurgical

* Corresponding Author:

Kambiz Eftekhari, MD.

Address: Department of Pediatrics, Pediatric Gastroenterology and Hepatology Research Center, Bahrami Children's Hospital, Tehran University of Medical Sciences, Tehran, Iran.

E-mail: dr_k_eftekhari@yahoo.com



Figure 1. The epinephrine ampoule ingested by the reported patient

changes, are at increased risk for failing to pass the FBs [3]. The most commonly ingested FBs are coins, magnets, batteries, small toys, jewelry, buttons, and bones in decreasing order of frequency [4]. Imaging plays an essential role in the workup and treatment of pediatric patients with suspected FB ingestion. The first imaging step in suspected FB ingestion is generally radiography. It should include the frontal and lateral radiographs of the chest, neck, and abdomen [5]. Computed Tomography (CT) is not generally the first-line imaging modality; however, it can be considered in the following cases: Symptomatic patients and whenever the ingested FB

has a large size, a length of >5 cm, or sharp edges [6]. The timing of endoscopy in children with ingested FBs depends on their age or body weight, clinical presentations, time passed since the last meal, time-lapse since ingestion, the type, size, and shape of the FB, as well as the present location in the Gastrointestinal (GI) tract [7].

Case Presentation

We present a three-year-old boy referring to our Emergency Room (ER) following the ingestion of a FB. He was a well-nourished boy who had incidentally ingested an ampoule of epinephrine (Figure 1) while his brother was being managed because of an asthma attack.

He presented no symptoms, and his vital signs were typical. Since the lapse time between ingestion and the time of the first visit was guessed around one hour, plain abdominal radiography was ordered after admitting the kid in the ER. The radiograph demonstrated the location of the ingested ampoule in the patient's abdomen. It seemed intact and without broken parts. (Figures 2, 3). The reported child was consulted by a cardiologist for the probable cardiac adverse effects of the release of the medication and stayed in the ER under close observation for 24 hours.

The patient underwent an upper endoscopy, but the object had already passed through the pylorus. The vital signs remained healthy and the patient presented no symptoms. The following day, he passed the ampoule without any complications.

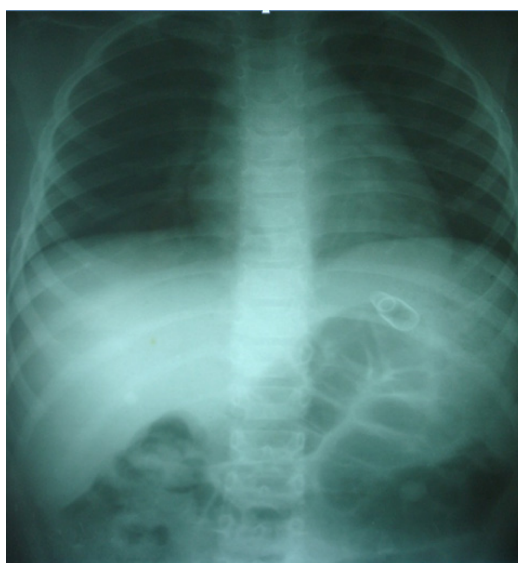

Figure 2. The ampoule in the patient's abdomen



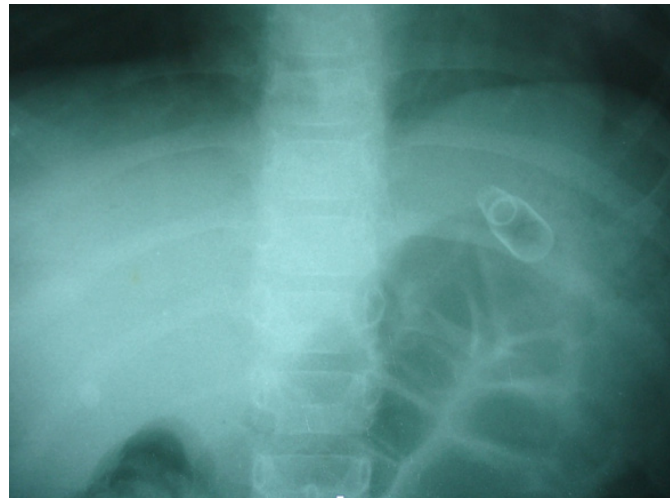


Figure 3. The ampoule in the patient's abdomen



Discussion

It remains unknown exactly how many BD ingestions occur per year in the pediatric population. This is because numerous FB ingestions go unnoticed by parents, and most of them pass uneventfully through the digestive tract. The child's normal developmental milestones of using the hand to take an object and grasp with a pinching motion are observed at 6 and 7 months of age, respectively. Some of the risk factors for FB ingestion include mental and developmental retardation, hyperactivity, a history of esophageal disease, and a history of recurrent ingestions. Our reported case was pretty unique because the most commonly ingested FBs in the pediatric population include coins, followed by magnets, batteries, and so on.

Conclusion

The ingestion of an ampoule in an ER has never or hardly ever been reported in the literature. Our presented case might be a unique report of this sort. The policy of "wait and watch" for this kid was based on the fact that, for GI foreign bodies, the type of object, its location, and the child's symptoms dictate treatment. Accordingly, most gastric objects pass without complication and could be observed requiring no intervention. Since our patient suggested no symptoms and signs within the 24 hours of close observation and, most important of all, did pass the object without complications, no treatment intervention was provided to him. The initial evaluation of a patient suspected of having a GI foreign body should include a complete physical examination and necessary plain films. Asymptomatic patients having no dangerous FB could be observed un-

til either they present something abnormal or uneventfully pass the FB.

Ethical Considerations

Compliance with ethical guidelines

We obtained the written conscious consent of the child's parents to publish the report of their son and assured them that the child's name and pictures would remain confidential.

Funding

No funding was provided for this study.

Authors' contributions

All authors were equally involved in developing this article.

Conflict of interest

The authors declared no conflicts of interest.

Acknowledgements

We thank the studied child's family for their cooperation and permission to publish this rare case.

References

- [1] Denney W, Ahmad N, Dillard B, Nowicki MJ. Children will eat the strangest things: A 10-year retrospective analysis of the for-

- foreign body and caustic ingestions from a single academic center. *Pediatric Emergency Care*. 2012; 28(8):731-4. [DOI:10.1097/PEC.0b013e31826248eb] [PMID]
- [2] Seo JK. Endoscopic management of gastrointestinal foreign bodies in children. *Indian Journal of Pediatrics*. 1999; 66(1 Suppl):S75-80. [PMID]
- [3] Louie MC, Bradin S. Foreign body ingestion and aspiration. *Pediatrics in Review*. 2009; 30(8):295-301. [DOI:10.1542/pir.30-8-295] [PMID]
- [4] Kay M, Wyllie R. Pediatric foreign bodies and their management. *Current Gastroenterology Reports*. 2005; 7(3):212-8. [DOI:10.1007/s11894-005-0037-6] [PMID]
- [5] Hesham A-Kader H. Foreign body ingestion: Children like to put objects in their mouth. *World Journal of Pediatrics*. 2010; 6(4):301-10. [DOI:10.1007/s12519-010-0231-y] [PMID]
- [6] Pinto A, Muzj C, Gagliardi N, Pinto F, Setola FR, Scaglione M, et al. Role of imaging in the assessment of impacted foreign bodies in the hypopharynx and cervical esophagus. *Seminars in Ultrasound, CT, and MR*. 2012; 33(5):463-70. [DOI:10.1053/j.sult.2012.06.009] [PMID]
- [7] Lim CW, Park MH, Do HJ, Yeom JS, Park JS, Park ES, et al. Factors associated with removal of impacted fishbone in children, suspected ingestions. *Pediatric Gastroenterology, Hepatology & Nutrition*. 2016; 19(3):168-74. [DOI:10.5223/pghn.2016.19.3.168] [PMID] [PMCID]