



## A Case of Secondary Hemochromatosis



Narjes Zarei Jalalabadi\*<sup>1</sup>, Morteza Daraei<sup>1</sup>, Samaneh Parsa<sup>1</sup>, Neda Faraji<sup>2</sup>

1. Department of Internal Medicine, Imam Khomeini Hospital Complex, Tehran University of Medical Sciences, Tehran, Iran.

2. Department of Internal Medicine, Baharlo Hospital, Tehran University of Medical Sciences, Tehran, Iran.

Use your device to scan  
and read the article online



**Citation:** Zarei Jalalabadi N, Daraei M, Parsa S, Faraji N. A Case of Secondary Hemochromatosis. Case Reports in Clinical Practice .2020; 5(4):128-130.

**Running Title:** Secondary Hemochromatosis



### Article info:

**Received:** 21 October 2020

**Revised:** 28 October 2020

**Accepted:** 25 November 2020

### Keywords:

Hemochromatosis; Iron overload; Thalassemia

### ABSTRACT

A 28-year-old woman with a history of transfusion-dependent thalassemia major who did not receive any iron-chelating agent presented with symptoms of iron overload with marked diffuse increased liver density. Eventually, the diagnosis of secondary hemochromatosis was done based on the aforementioned history, laboratory, and imaging findings.

### Case presentation

**A** 28-year-old woman with a history of transfusion-dependent thalassemia major who did not receive any iron-chelating agent and recently experienced an episode of diabetic ketoacidosis presented with abdominal pain, distension, and weakness. Physical examination revealed ascites, elevated jugular venous pressure, lower extremity edema, and dark skin.

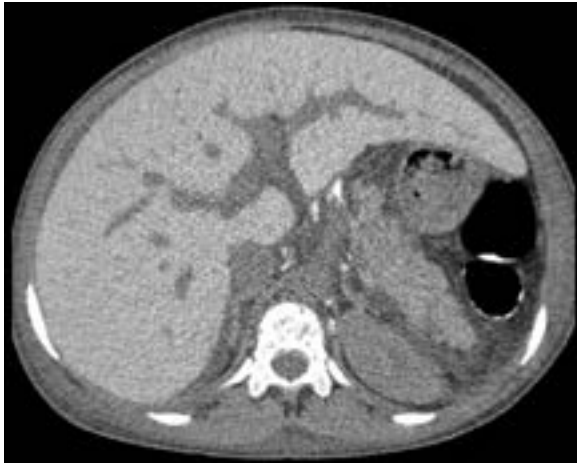Laboratory data showed normal serum glucose, pseudo-lymphocytosis (due to increased nucleated red blood cells), normocytic anemia, serum ferritin level of 22,000 ng/mL, biochemical evidence of cirrhosis, and positive serologic test for hepatitis C virus (hypoalbuminemia, high serum-ascites albumin gradient with low protein ascetic fluid, coagulation test disturbances, aspartate aminotransferase [133 U/L], and alanine aminotransferase [91 U/L]). The renal and thyroid function tests were normal.

\* Corresponding Author:

Narjes Zarei Jalalabadi; MD.

Address: Department of Internal Medicine, Imam Khomeini Hospital Complex, Tehran University of Medical Sciences, Tehran, Iran.

E-mail: [narges\\_z1367@yahoo.com](mailto:narges_z1367@yahoo.com)

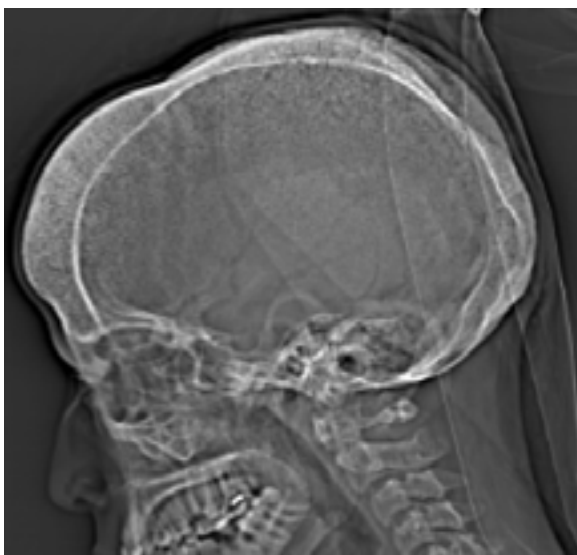


**Figure 1.** Axial Non-enhanced Computed Tomography

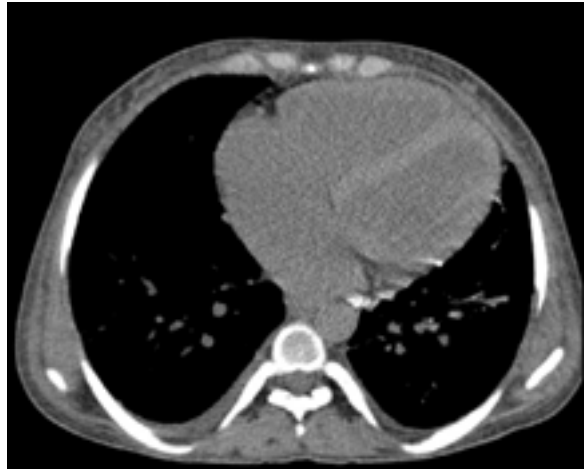Shows hepatomegaly with marked diffuse increased density, the spleen is absent.

Abdominal ultrasonography was compatible with hepatomegaly and cirrhosis. Echocardiography revealed restrictive cardiomyopathy.

Non-enhanced Computed Tomography (NECT) scan showed cardiomegaly and hepatomegaly with marked diffuse increased liver density (Figures 1 and 2). The prominence of the interventricular septum in NECT is in favor of the patient's anemia [1] (Figure 2). Note also the hair-on-end appearance of the skull (Figure 3).



**Figure 3.** Computed tomography lateral scout view shows thickened calvarium and hair-on-end appearance (due to thickened trabeculae)



**Figure 2.** Cardiomegaly, note interventricular septum is visualized on unenhanced CT

Compatible with anemia (although not specific nor sensitive finding).

The diagnosis of secondary hemochromatosis was done based on the aforementioned history, laboratory, and imaging findings. The abdominal CT scan in hemochromatosis shows diffuse hyperattenuating liver [2]. Although this imaging finding is almost specific for iron overload, rare conditions such as chronic amiodarone consumption, glycogenosis, and Dubbin-Johnson syndrome could also elevate liver density [3].

## Ethical Considerations

### Compliance with ethical guidelines

All ethical principles were considered in this article

### Funding

This research did not receive any grant from funding agencies in the public, commercial, or non-profit sectors.

### Conflict of interest

The authors declared no conflict of interest.

## References

- [1] Foster M, Nolan RL, Lam M. Prediction of anemia on unenhanced computed tomography of the thorax. *Journal-Canadian Association of Radiologists*. 2003; 54(1):26-30. <https://www.semanticscholar.org/paper/Prediction-of-anemia-on-unenhanced-computed-of-the-Foster-Nolan/611a0ac71028ec1a4be44f0bd0674eb3dc82eac>

- [2] Kawamoto S, Soyler PA, Fishman EK, Bluemke DA. Nonneoplastic liver disease: Evaluation with CT and MR imaging. *Radiographics*. 1998; 18(4):827-48. [DOI:10.1148/radiographics.18.4.9672968] [PMID]
- [3] Guyader D, Gandon Y, Deugnier Y, Jouanolle H, Loreal O, Simon M, et al. Evaluation of computed tomography in the assessment of liver iron overload: A study of 46 cases of idiopathic hemochromatosis. *Gastroenterology*. 1989; 97(3):737-43. [DOI:10.1016/0016-5085(89)90646-X]