



## Case Report

Journal Homepage: <http://crp.tums.ac.ir>

# Adenocarcinoma of the Gallbladder in a 73-Year-Old Man: A Rare Case Report



Elham Kazemi Jahromi , Hakimeh Sajjadi\*

Department of Pathology, Shahid Mohammadi Hospital, Hormozgan University of Medical Sciences, Bandar Abbas, Iran.

Use your device to scan and read the article online



**Citation:** Kazemi Jahromi E, Sajjadi H. Adenocarcinoma of the Gallbladder in a 73-Year-Old Man: A Rare Case Report. *Case Reports in Clinical Practice*. 2021; 6(2):42-46.

**Running Title:** Adenocarcinoma in Gallbladder.

## ABSTRACT

Primary gallbladder cancer is a rare malignancy and it is difficult to be diagnosed because there are no specific signs and symptoms at the initial stage. The most important risk factors include female gender, the age of more than 65 years, and having large gallstones. The authors present a rare and unusual case of adenocarcinoma of the gallbladder because the reported case is a male patient from Asia and had acalculous cholecystitis.

### Article info:

**Received:** 24 Feb 2021

**Revised:** 19 Mar 2021

**Accepted:** 27 Mar 2021

### Keywords:

Gallbladder; Carcinoma; Cholecystectomy

## Introduction

Primary Gallbladder Cancer (PGC) is a rare malignancy, which is difficult to be diagnosed because of no specific signs and symptoms at the initial stage. Gallbladder cancer has a variable demographic and geographic distribution. In the United States, it is the sixth most common malignancy [1]. The prevalence of gallbladder cancer in South America is 12.3/100000 for males and 27.3/100000

for females. Its prevalence in Poland is 14/100000, in Israel 5/100000, and in Japan 7/100000 [2-4].

Risk factors of gallbladder carcinoma include female gender, aging, postmenopausal status, smoking, increased body mass index, chronic *Salmonella typhi* infection and gallstones (chronic irritation and inflammation of the gallbladder lead to mucosal dysplasia and subsequent carcinoma), gallbladder polyp (greater than 1 cm in size), porcelain gallbladder, ulcerative colitis, and congenital anatomic anomalies [5-10]. The purpose of

\* Corresponding Author:

Hakimeh Sajjadi, MD.

Address: Department of Pathology, Shahid Mohammadi Hospital, Hormozgan University of Medical Sciences, Bandar Abbas, Iran.

E-mail: [sajjadipathologyh@gmail.com](mailto:sajjadipathologyh@gmail.com)

this case study was to describe a rare case of gallbladder carcinoma during open cholecystectomy.

### Case Presentation

A 73-year-old Iranian man with a history of asthma from 6 years ago was presented with abdominal pain in the right upper quadrant and decreased appetite from 2 weeks ago. On physical examination, he was tender and ascites were observed. On admission, his White Blood Cell (WBC) count was 7500 /uL (90% neutrophils) and the alkaline phosphatase was high at 391U/L, Prothrombin Time (PT) time was high at 14 seconds, alanine transaminase was 18.9 U/L, aspartate transaminase was 22.9 U/L, direct bilirubin was 0.28 mg/dl, and amylase was 40 U/L. An ultrasound of his gallbladder showed a 25×10 mm irregular mass in the fundus with fluid around the gallbladder. Magnetic Resonance Cholangiopancreatography (MRCP) showed a filling defect with an irregular margin in the fundus. The patient was subjected to surgery for an open cholecystectomy. There were no masses or abnormal lymph nodes palpated in the liver. The specimen was sent to the pathology department. The final pathology report was T2N1 (stage 3) gallbladder adenocarcinoma. The patient was followed up by his surgeon and an oncologist for definitive resection and chemotherapy.

### Pathologic report

On gross examination of the gallbladder, the mass was 14.5 cm in length and 4 cm in the greatest diameter. The serosal surface was smooth in gray color. On opening, the mucosa was green and velvety and there was an ill-

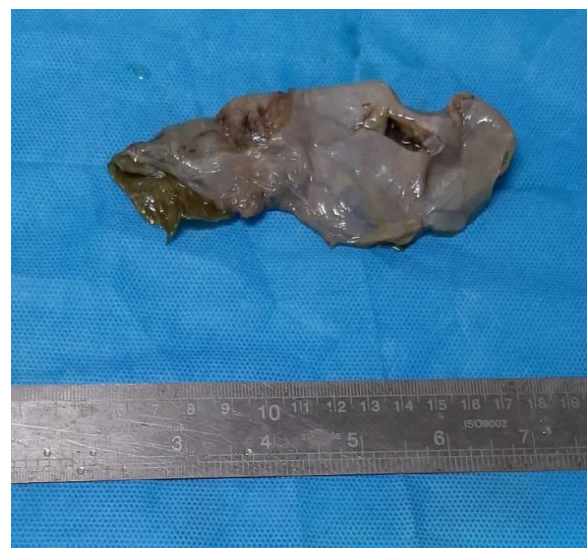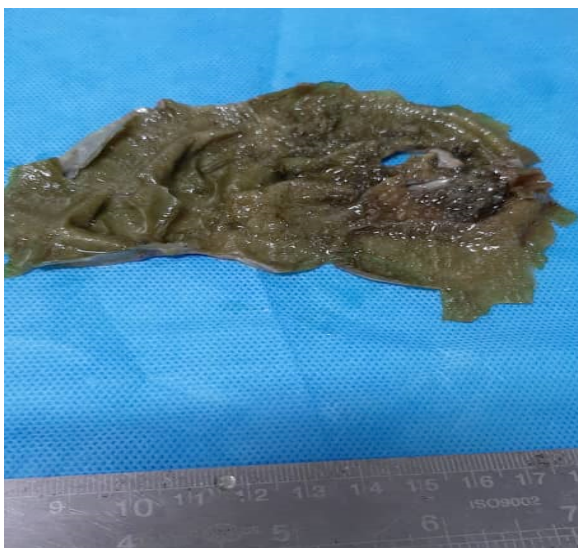defined green-brown mass (2.5×2.5×1 cm) with papillary projection in the fundus. Wall thickness ranged from 0.4 to 1 cm and gallstone was not observed (Figure 1).

On microscopic examination, the neoplastic cells had a papillary growth pattern on the surface and extend into the peri muscular connective tissue. These papillae were lined by columnar cells and the nuclei were large, hyperchromatic, with irregular nuclear membrane, pleomorphism, high mitosis, and loss of polarity. The nucleoli were prominent. The invasive glands were well-formed. Small, open, and round lumina that were lined by low cuboidal cells with the desmoplastic reaction in the stroma were found. Two lymph nodes were detected around the cystic duct that one lymph node was involved by the tumor. Perineural and vascular invasion was not seen (Figure 2).

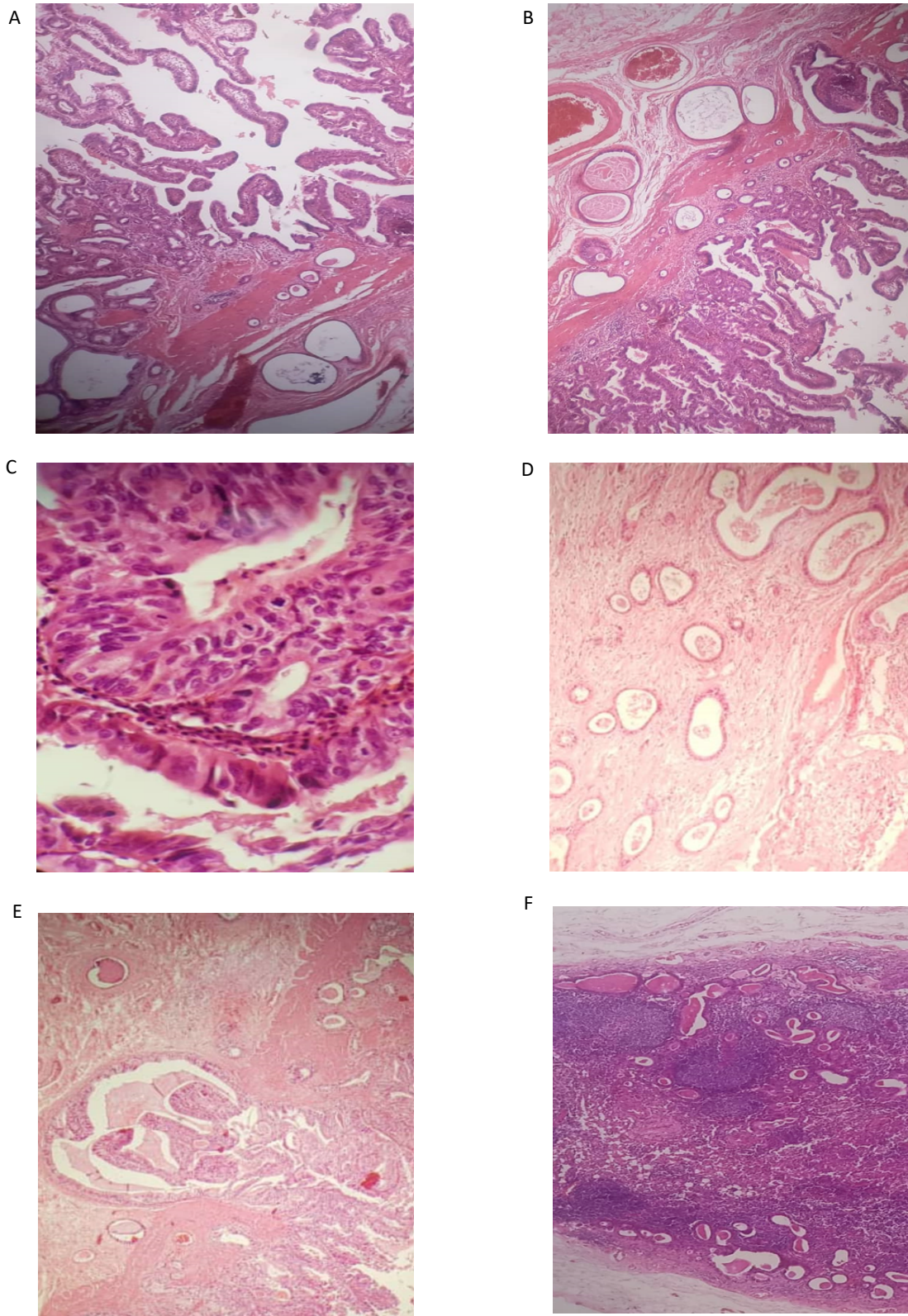
### Conclusion

The most common type of gallbladder malignancies is Primary Gallbladder Carcinoma (PGC) (epithelial origin). Sarcomas, lymphomas, and carcinoid tumors are unusual malignancies. Adenocarcinomas are the most common type of PGC (approximately 90%), depending on the degree of gland formation divided into three types: well, moderately, and poorly differentiated.

There are several histologic variants of adenocarcinoma, including papillary, intestinal, mucinous, signet-ring cell, and clear cell. Other histologic subtypes of PGC are adenosquamous carcinoma, squamous cell carcinoma, small cell carcinoma, and undifferentiated carcinoma.



**Figure 1.** Gross anatomy of the gallbladder. Ill-defined green-brown papillary mass in the fundus



**Figure 2.** Hematoxylin and eosin stain of adenocarcinoma of the gallbladder

A: Papillary growth pattern; B: No vascular invasion; C: Mitosis in cancer cells; D: Well-formed and small gland with open lumina lined by low cuboidal cells with a desmoplastic reaction in the stroma; E: Extending to the muscular layer; F: Metastatic lymph node around the cystic duct.

**Table 1.** Definition of Tumor Node Metastasis (TNM) in the current American Joint Committee on Cancer (AJCC) gallbladder carcinoma staging

Stages	Definitions
TX	Primary tumor cannot be assessed
T0	No evidence of primary tumor
Tis	Carcinoma in situ
Primary tumor (T)	T1 Tumor invades lamina propria (T1a) or muscle layer (T1b)
	T2 Tumor invades peri muscular connective tissue; no extension beyond serosa or into the liver
	T3 Tumor perforates the serosa (visceral peritoneum) or directly invades one adjacent organ or both (extension 2 cm or less into the liver)
	T4 Tumor extends more than 2 cm into the liver, or into two or more adjacent organs (stomach, duodenum, colon, pancreas, omentum, extrahepatic bile ducts, any involvement of liver)
	NX Regional lymph nodes cannot be assessed
Regional lymph nodes (N)	N0 No regional lymph node metastasis
	N1 Metastasis in the cystic duct, peri choledochal, or hilar lymph nodes (i.e., in the hepatoduodenal ligament)
	N2 Metastasis in peripancreatic (head only), peri duodenal, periportal, celiac, or superior mesenteric lymph nodes
	MX Distant metastasis cannot be assessed
Distant metastasis (M)	M0 No distant metastasis
	M1 Distant metastasis


**Table 2.** Stage grouping in the current AJCC gallbladder carcinoma staging

Stages	Grouping
0	Tis N0 M0
1	T1 N0 M0
2	T2 N0 M0
3	T1 N1 M0
	T2 N1 M0
	T3 N0 M0
4a	T3 N1 M0
	T4 N0 M0
4b	T4 N1 M0
	Any T N2 M0
	Any T Any N M1



About 1% of cholecystectomies for cholelithiasis have an incidental gallbladder carcinoma because clinical symptoms are nonspecific in early-stage and mimic gallbladder inflammation due to gallstones. In the advanced stage, symptoms are chronic abdominal pain, loss of appetite, nausea, vomiting, weight loss, and jaundice. The five-year survival rate depends on Tumor Node Metastasis (TNM) staging. Stage 1, 50%, stage 2, 29%, stage 3, 7%, stage 4a, 3%, and stage 4b, 2%. Treatment based on the TMN stage, Tis or T1a can be done using simple cholecystectomy. T1b and higher need extended cholecystectomy with negative margins (liver and cystic duct) (Tables 1 and 2) [11, 12].

In the review of the literature, the most important risk factors for gallbladder carcinoma include female gender, the age of more than 65 years, and large gallstones. However, our patient was male with acalculous cholecystitis, and cancer was found incidentally on radiologic imaging; hence, our result demonstrated that imaging, including ultrasound and CT scan, are useful and suitable diagnostic methods to detect early stage of cancer. Accordingly, it leads to a decrease in mortality and morbidity rate.

## Ethical Considerations

### Compliance with ethical guidelines

This study was approved by the Ethics Committee of the Hormozgan University of medical science (Code: IR.HUMS.REC.1399.183).

### Funding

This research did not receive any grant from funding agencies in the public, commercial, or non-profit sectors.

### Conflict of interest

The authors declared no conflict of interest.

## References

- [1] Greenlee RT, Murray T, Bolden S, Wingo PA. Cancer statistics, 2000. *CA: A Cancer Journal for Clinicians*. 2000; 50(1):7-33. [DOI:10.3322/canjclin.50.1.7] [PMID]
- [2] Randi G, Franceschi S, La Vecchia C. Gallbladder cancer worldwide: Geographical distribution and risk factors. *International Journal of Cancer*. 2006; 118(7):1591-602. [DOI:10.1002/ijc.21683] [PMID]
- [3] Randi G, Malvezzi M, Levi F, Ferlay J, Negri E, Franceschi S, et al. Epidemiology of biliary tract cancers: An update. *Annals of Oncology*. 2009; 20(1):146-59. [DOI:10.1093/annonc/mdn533] [PMID]
- [4] Strom BL, Soloway RD, Rios-Dalenz JL, Rodriguez-Martinez HA, West SL, Kinman JL, et al. Risk factors for gallbladder cancer. An international collaborative case-control study. *Cancer*. 1995; 76(10):1747-56. [DOI:10.1002/1097-0142(19951115)76:10<1747::aid-cncr2820761011>3.0.co;2-1]
- [5] Shaffer EA. Gallbladder cancer: The basics. *Gastroenterology & Hepatology*. 2008; 4(10):737-41. [PMID] [PMCID]
- [6] Khan ZR, Neugut AI, Ahsan H, Chabot JA. Risk factors for biliary tract cancers. *The American Journal of Gastroenterology*. 1999; 94(1):149-52. [DOI:10.1111/j.1572-0241.1999.00786.x] [PMID]
- [7] Caygill CP, Hill MJ, Braddick M, Sharp JC. Cancer mortality in chronic typhoid and paratyphoid carriers. *Lancet*. 1994; 343(8889):83-4. [DOI:10.1016/S0140-6736(94)90816-8] [PMID]
- [8] Albores-Saavedra J, Alcántra-Vazquez A, Cruz-Ortiz H, Herrera-Goepfert R. The precursor lesions of invasive gallbladder carcinoma. Hyperplasia, atypical hyperplasia and carcinoma in situ. *Cancer*. 1980; 45(5):919-27. [DOI:10.1002/1097-0142(19800301)45:5<919::aid-cncr2820450514>3.0.co;2-4] [PMID]
- [9] Berk RN, Armbuster TG, Saltzstein SL. Carcinoma in the porcelain gallbladder. *Radiology*. 1973; 106(1):29-31. [DOI:10.1148/106.1.29] [PMID]
- [10] Bloustein PA. Association of carcinoma with congenital cystic conditions of the liver and bile ducts. *The American Journal of Gastroenterology*. 1977; 67(1):40-6. [PMID]
- [11] Singletary SE, Greene FL, Sobin LH. Classification of isolated tumor cells: Clarification of the 6<sup>th</sup> edition of the American Joint Committee on Cancer staging manual. *Cancer*. 2003; 98(12):2740-1. [DOI:10.1002/cncr.11865] [PMID]
- [12] Edge SB, Compton CC. American joint committee on cancer: The 7th edition of the AJCC cancer staging manual and the future of TNM. *Annals of Surgical Oncology*. 2010; 17(6):1471-4. [DOI:10.1245/s10434-010-0985-4] [PMID]