



## Case Report

Journal Homepage: <http://crp.tums.ac.ir>

# Recurrent Schwannoma With Extensive Xanthomatous Changes: A Case Report

Hedieh Moradi Tabriz , Elham Nazar , Arezoo Eftekhari Javadi, Niousha Bakhshi*Department of Pathology, Sina Hospital, Tehran University of Medical Sciences, Tehran, Iran.*

Use your device to scan and read the article online



**Citation:** Moradi Tabriz H, Nazar H, Eftekhari Javadi A, Bakhshi N. Recurrent Schwannoma With Extensive Xanthomatous Changes: A Case Report. *Case Reports in Clinical Practice*. 2021; 6(3):99-104.

**Running Title:** Recurrent Schwannoma With Extensive Xanthomatous Changes

## ABSTRACT

Schwannoma is one of the most common benign intracranial tumors, which originates from the Schwann cells of neural structures in the upper part of the vestibular branch of the eighth cranial nerve. This report describes a 64-year-old woman with headache and vertigo who had a past surgical history of acoustic schwannoma about 10 years ago. The patient underwent excisional surgery. Histological examinations revealed schwannoma with extensive xanthomatous changes. Immunohistochemistry staining confirmed the diagnosis. Based on the diagnosis, the patient received no more treatment. After 6 months of close follow-up examinations, no recurrence and complication were observed. Schwannoma could be seen with a vast variety of histologic changes. Recurrence of Schwannoma is uncommon in patients without neurofibromatosis, but it should be considered in a proper clinical context.

### Article info:

**Received:** 30 May 2021

**Revised:** 13 Jun 2021

**Accepted:** 21 Jun 2021

### Keywords:

Schwannoma; Recurrence; Neurofibromatosis

## Introduction

Schwannomas (neuromas, neurilemmomas) are benign tumors originating from Schwann cells or nerve fiber sheath cells. They are solitary, encapsulated tumors generally close to or enclosed by a nerve [1]. Schwannomas are found mostly in cranial and peripheral nerves [2]. Schwannoma is one of the most common benign intracranial tumors, which originates from the Schwann cells of neural

sheaths in the upper part of the vestibular branch of the eighth cranial nerve, principally in patients with Neurofibromatosis type 2 (NF2) [3].

Vestibular schwannomas are one of the most prevalent cerebellopontine angle tumors (8% of all intracranial tumors and 85% of all tumors in this site). The traditional clinical presentation is tinnitus or progressive hearing loss [4]. Morphologic variants of benign schwannoma consist of ancient schwannoma, cellular schwannoma,

### \* Corresponding Author:

**Elham Nazar, MD.**

**Address:** Department of Pathology, Sina Hospital, Tehran University of Medical Sciences, Tehran, Iran.

**E-mail:** [enazar@sina.tums.ac.ir](mailto:enazar@sina.tums.ac.ir)



plexiform schwannoma, melanotic schwannoma, epithelioid schwannoma, hybrid schwannoma/perineurium, hybrid schwannoma/neurofibroma, and, arguably, glandular schwannoma [5]. Also, schwannoma with cystic degeneration, including cystic formation, calcification, hemorrhage, hyalinization, and xanthomatous infiltration is a rarely informed entity [6].

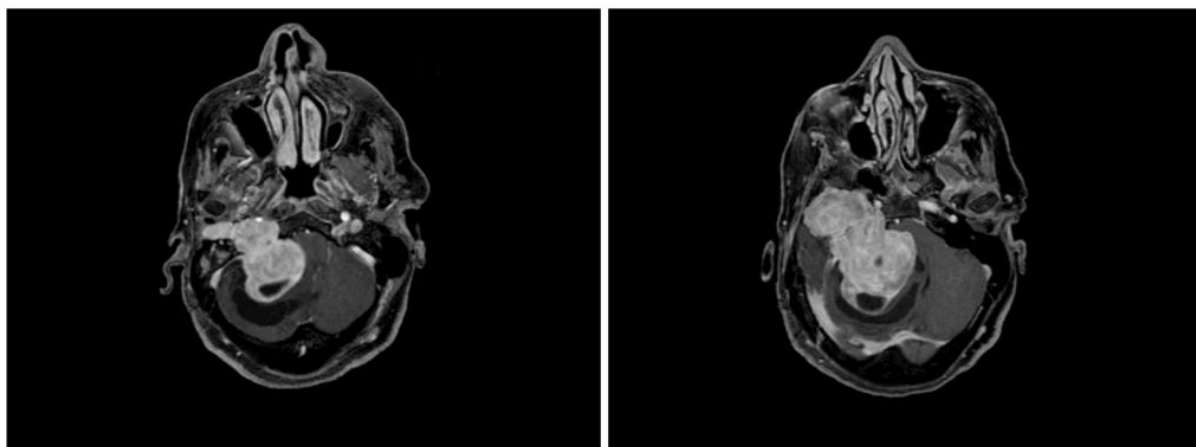
Malignant transformation of benign nerve sheath tumors is rare and described cases are few. They are mostly seen in the setting of neurofibromatosis type 2 [7]. Hybrid morphology is essential to distinguish because of its association with neurofibromatosis [8]. Malignancy is proposed by the extreme pleomorphism of the tumor, the existence of tripolar mitotic figures, flow cytometric demonstration of aneuploidy, and a significant percentage of S-phase tetraploid nuclei (9%) [9].

The ultrastructural pattern of the acoustic schwannoma is considered in surgically excised tumors, in which typical neoplastic cell is elongated, spindle-shaped, and covered with basement membrane and numerous expanded cellular processes. Cells representing abundant microfilaments are also seen [10]. On imaging, schwannomas are enhancing, round masses, most commonly arising from the vestibular cranial nerve near the porus acusticus, and accompanied by the expansion of the internal auditory canal [11]. Tumors follow a usually benign clinical course; however, the recurrence and malignant transformation are rare [12]. Recurrence of acoustic schwannoma is extremely rare outside the clinicopathological context of neurofibromatosis [13].

## Case Presentation

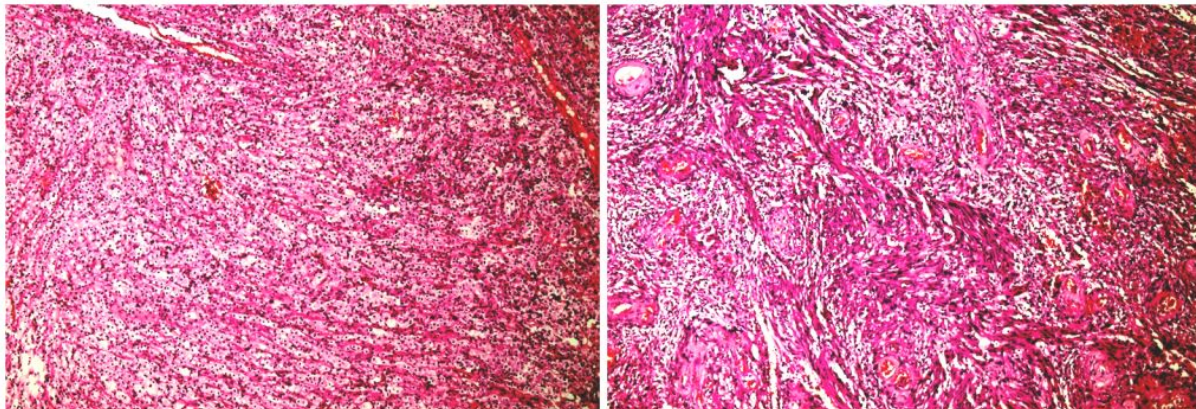
A 64-year-old female with headache and vertigo was referred to the department of neurosurgery of Sina hospital affiliated with the Tehran University of Medical Sciences. The first outpatient examination findings were unremarkable. Our patient's past medical history showed acoustic schwannoma surgery about 10 years ago without any complication and since then, she had no symptoms and after a close follow-up, she had not any signs of recurrence until 4 months before admission to our hospital. The patient's family history was unremarkable. Also, no neurological sign was found. The patient underwent brain Magnetic Resonance Imaging (MRI) with and without contrast, which showed a lobulated densely enhancing mass of about 52×45 mm in diameter in a posterior and middle cranial fossa on the right side with extension to the internal and external auditory canals (Figure 1).

Evidence of post-operative changes was seen, including a resection cavity containing fluid and air with mild peripheral hemorrhage and mild meningeal enhancement in the bed of surgery. However, persistent nonspecific radiologic enhancement within the postoperative field is usual, making the diagnosis of tumor recurrence challenging [14]. The patient was treated with excisional surgery. She well tolerated the procedure without any complications. The specimen for pathology examination consists of multiple pieces of brown-yellowish tissue totally measuring 5.5×5×1 cm without any apparent capsule. Histological examinations revealed hypercellular neoplastic tissue composed of spindle-shaped cells with mild nuclear pleomorphism, including some foci resembling verocay bodies admixed with extensive inflamma-



**Figure 1.** Brain Magnetic Resonance Imaging (MRI) with contrast

Shows a lobulated densely enhancing mass of about 52x45mm in diameter in a posterior and middle cranial fossa on the right side with extension to the internal and external auditory canals.



**Figure 2.** Microscopic examination

Left: Extensive infiltrating foamy histiocytes and Right: Spindle-shaped tumoral cells with mild nuclear pleomorphism. Large thick-walled vessels were seen (H&E x100).

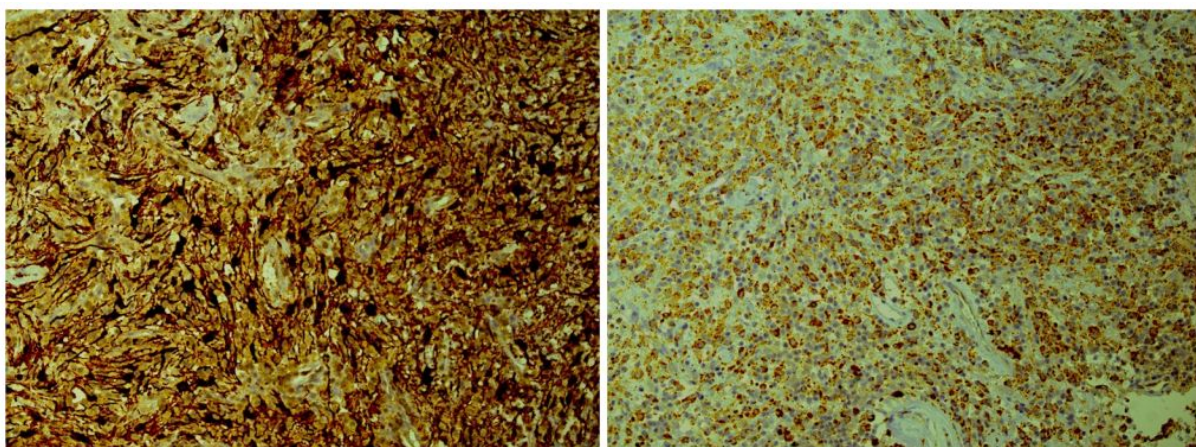
tory cells and foamy histiocytes (Figure 2). Also, large thick-walled vessels were seen. No atypia, necrosis, or mitosis was seen. Because the neoplastic tissue infiltrated by many foamy histiocytes, diagnosis was problematic. Immunohistochemistry (IHC) study showed strongly positive S100 protein in tumor cells.

Epithelial Membrane Antigen (EMA), cytokeratin, and Glial Fibrillary Acidic Protein (GFAP) were negative in tumor cells. CD68 was positive in infiltrating foamy histiocytes (Figure 3). Ki67 (proliferative index) was less than 1% in tumor cells. According to histomorphologic and IHC study, which was compatible with schwannoma with extensive xanthomatous changes, the diagnosis was confirmed. Based on the diagnosis, the patient received no additional treatment. After 6 months of close follow-up examinations, no recurrence was observed and the patient is still asymptomatic.

## Discussion

Schwannoma is a benign neural neoplasm of Schwann cell origin [15]. Development of schwannoma within the epineurium causes encapsulation, which permits successful resection [16]. Schwannomas are benign nerve sheath tumors believed to originate from Schwann cells of peripheral, motor, sympathetic, or cranial nerves of the head and neck areas and upper and lower extremities [17]. Although they may arise at any age, the peak prevalence is in the third and sixth decades. Also, there is no gender tendency [18]. The diagnosis of schwannoma can only be made using histopathology.

Characteristically, the tumor demonstrates two different patterns of spindle cell arrangement: the solid and cellular Antoni A and the less cellular Antoni B pattern with myxoid regions [19]. Verocay bodies, which are cellular eosinophilic zones, are commonly seen [20].



**Figure 3.** Infiltrating foamy histiocytes

Left: S100 staining was positive in tumoral cells; Right: CD68 staining was positive.



Schwannomas have been described to display degenerative changes, containing cyst formation, calcification, hemorrhage, hyalinization, and xanthomatous infiltration [21]. “Ancient” schwannoma was firstly introduced by Ackerman and Taylor as a degenerative change happening in a long-standing schwannoma, characterized by nuclear hyperchromasia, mild nuclear pleomorphism, stromal edema, fibrosis, and xanthomatous changes leading to a misdiagnosis of malignancy and is a problematic challenge [22].

On imaging, two-thirds of schwannomas show the radiographic appearance of complex-cystic lesions [23]. Neurofibromatosis-2 (NF-2) is an autosomal dominant hereditary disease accompanied by schwannomas of the acoustic and other cranial nerves and meningiomas. Bilateral acoustic schwannoma is the hallmark of the disease [24]. Mutations in the gene coding a tumor suppressor, Merlin, is the reason for the progression of multiple tumors of the nervous system, including schwannomas, meningiomas, and ependymomas happening either spontaneously or as an inherited disease, neurofibromatosis type 2 [25]. It is critical to discriminate the hereditary, bilateral vestibular schwannomas of NF2 from nonheritable, unilateral vestibular schwannoma because the implications for management are diverse [26].

A variety of symptoms have been seen in acoustic schwannomas, which are generally influenced by the size, consistency, and extensions of the tumor [27]. Schwannoma must be distinguished from a neurofibroma, which is another benign tumor of the peripheral nerves with unlike clinical and pathological features. Microscopically, the occurrence of encapsulation, two types of Antoni areas, and diffusely strong immunostaining for S-100 protein and negative Neurofilament (NF) discriminate schwannomas from neurofibromas [28]. Although neurofibroma is less common, it must be retained in mind as a differential diagnosis [29]. Distinguishing this tumor is challenging, principally in younger patients, given its benign nature, radiological similarity to other tumors, such as pilocytic astrocytoma, and favorable response to resection [30].

A brain tumor with histological structures suggestive of schwannoma with underlying meningioangiomas was subjected to electron microscopic and immunohistochemical analysis, which established the neoplasm as a meningioma [31]. The highly precise radiologic evaluation using contrast-enhanced MRI and CT scanning exhibited enhancement at a peridegenerative extent and occasionally at a capsule. These results are different from those of the typical schwannoma, and neurofibroma patterns [32]. The purposes of surgery are total tumor exclusion, with preservation of life and prevention of neurologic injury [33].

The rate of vestibular schwannoma recurrence after total removal is remarkably low in skillful hands. Unobserved microscopic deposits missed on critical points, such as the facial nerve, the preserved cochlea nerve, or the fundus of the internal auditory canal could be potential reasons for the recurrence [34].

Local recurrence was associated with better prediction in patients with neurofibromatosis [35]. According to Ortolan et al. and Kagaya et al., the pain was suppressed by the elimination of the lesion, and did not relapse. However, Abernathy et al. described that in four out of nine patients, for whom limited resection of the tumor was done, it relapsed locally and symptoms repeated, and the operation was re-performed. The re-operation was effective and the schwannoma did not reappear again [36]. Thus, the patients should be followed up for 15 years with gadolinium-enhanced MRI [34].

## Conclusion

It is significant to distinguish these tumors from neurofibromas and other tumors as they follow benign clinical progress, with complete surgical excision being curative. The trouble with their diagnosis and management relates to the nonspecific presentation, different histologic changes, and radiographic appearance. Recurrence of schwannoma is uncommon in patients without NF, but it should be considered in a proper clinical context.

## Ethical Considerations

### Compliance with ethical guidelines

There were no ethical considerations to be considered in this research.

### Funding

This research did not receive any grant from funding agencies in the public, commercial, or non-profit sectors.

### Conflict of interest

The authors declared no conflict of interest.

## References

- [1] Naghibzadeh M, Faraji Rad M, Kamandi SK. Hypoglossal schwannoma: A case report and review of literature. *Iranian Journal of Otorhinolaryngology*. 2011; 23(1):45-50. [DOI:10.18502/crcp.v4i3.1713]

- [2] Goh BK, Tan YM, Chung YF, Chow PK, Ooi LL, Wong WK. Retroperitoneal schwannoma. *The American Journal of Surgery*. 2006; 192(1):14-8. [DOI:10.1016/j.amjsurg.2005.12.010] [PMID]
- [3] Nazar E, Saffar H. Schwannoma in an uncommon site, upper lip: A case report. *Case Reports in Clinical Practice*. 2019; 4(3):78-80. [DOI:10.18502/crcp.v4i3.1713]
- [4] Kim SH, Youm JY, Song SH, Kim Y, Song KS. Vestibular schwannoma with repeated intratumoral hemorrhage. *Clinical Neurology and Neurosurgery*. 1998; 100(1):68-74. [DOI:10.1016/S0303-8467(98)00002-X] [PMID]
- [5] Liegl B, Bennett MW, Fletcher CD. Microcystic/reticular schwannoma: A distinct variant with predilection for visceral locations. *The American Journal of Surgical Pathology*. 2008; 32(7):1080-7. [DOI:10.1097/PAS.0b013e318160cfa] [PMID]
- [6] Subramanian N, Rambhatia S, Mahesh L, Menon SV, Krishnakumar S, Biswas J, et al. Cystic schwannoma of the orbit-a case series. *Orbit*. 2005; 24(2):125-9. [DOI:10.1080/01676830590922020] [PMID]
- [7] Wilkinson J, Reid H, Armstrong G. Malignant transformation of a recurrent vestibular schwannoma. *Journal of Clinical Pathology*. 2004; 57(1):109-10. [DOI:10.1136/jcp.57.1.109] [PMID] [PMCID]
- [8] Taubenslag KJ, Nickols HH, Chelnis JG, Mawn LA. Hybrid Neurofibroma/Schwannoma of the supraorbital nerve: Clinicopathologic correlation of a rare tumor. *Ophthalmic Plastic and Reconstructive Surgery*. 2017; 33(3S Suppl 1):S104-6. [DOI:10.1097/IOP.0000000000000597] [PMID]
- [9] Mrak RE, Flanigan S, Collins CL. Malignant acoustic schwannoma. *Archives of Pathology & Laboratory Medicine*. 1994; 118(5):557-61. [PMID]
- [10] Manolidis L, Baloyannis SJ. Pathology of acoustic nerve schwannoma in vivo and in vitro. *Acta Oto-Laryngologica*. 1985; 99(3-4):280-4. [DOI:10.3109/00016488509108909] [PMID]
- [11] Smirniotopoulos JG, Yue NC, Rushing EJ. Cerebellopontine angle masses: Radiologic-pathologic correlation. *RadioGraphics*. 1993; 13(5):1131-47. [DOI:10.1148/radiographics.13.5.8210595] [PMID]
- [12] Jo VY, Fletcher CDM. SMARCB1/INI1 loss in epithelioid schwannoma: A clinicopathologic and immunohistochemical study of 65 cases. *The American Journal of Surgical Pathology*. 2017; 41(8):1013-22. [DOI:10.1097/PAS.0000000000000849] [PMID]
- [13] McLean CA, Laidlaw JD, Brownbill DS, Gonzales MF. Recurrence of acoustic neuroma as a malignant spindle-cell neoplasm. Case report. *Journal of Neurosurgery*. 1990; 73(6):946-50. [DOI:10.3171/jns.1990.73.6.0946] [PMID]
- [14] Carlson ML, Van Abel KM, Driscoll CL, Neff BA, Beatty CW, Lane JI, et al. Magnetic resonance imaging surveillance following vestibular schwannoma resection. *The Laryngoscope*. 2012; 122(2):378-88. [DOI:10.1002/lary.22411] [PMID]
- [15] Moshref M, Tomarian L, Behnia H, Mashhadi Abbas A, Zafar Asoodeh M. Schwannoma, review of the literature and report of a case. 2001; 19(3):318-22. <https://www.sid.ir/en/Journal/ViewPaper.aspx?ID=32454>
- [16] Beaman FD, Kransdorf MJ, Menke DM. Schwannoma: Radiologic-pathologic correlation. *RadioGraphics*. 2004; 24(5):1477-81. [DOI:10.1148/rg.245045001] [PMID]
- [17] Mohiuddin Y, Gilliland MG. Adrenal schwannoma: A rare type of adrenal incidentaloma. *Archives of Pathology and Laboratory Medicine*. 2013; 137(7):1009-14. [DOI:10.5858/arpa.2012-0291-RS] [PMID]
- [18] Pfeifle R, Baur DA, Paulino A, Helman J. Schwannoma of the tongue: Report of 2 cases. *Journal of Oral and Maxillofacial Surgery*. 2001; 59(7):802-4. [DOI:10.1053/joms.2001.24298] [PMID]
- [19] Kashyap S, Pushker N, Meel R, Sen S, Bajaj MS, Khuriam N, et al. Orbital schwannoma with cystic degeneration. *Clinical & Experimental Ophthalmology*. 2009; 37(3):293-8. [DOI:10.1111/j.1442-9071.2009.02029.x] [PMID]
- [20] Subhashraj K, Balanand S, Pajaniammalle S. Ancient schwannoma arising from mental nerve. A case report and review. *Medicina Oral, Patología Oral y Cirugía Bucal*. 2009; 14(1):E12-4. [PMID]
- [21] Tan G, Vitellas K, Morrison C, Frankel WL. Cystic schwannoma of the pancreas. *Annals of Diagnostic Pathology*. 2003; 7(5):285-91. [DOI:10.1016/S1092-9134(03)00082-0]
- [22] Narasimha A, Kumar MH, Kalyani R, Madan M. Retroperitoneal cystic schwannoma: A case report with review of literature. *Journal of Cytology*. 2010; 27(4):136-9. [DOI:10.4103/0970-9371.73299] [PMID] [PMCID]
- [23] Andonian S, Karakiewicz PI, Herr HW. Presacral cystic schwannoma in a man. *Urology*. 2003; 62(3):551. [DOI:10.1016/S0090-4295(03)00481-3] [PMID]
- [24] Gelal F, Rezanko T, Uyaroglu MA, Tunakan M, Bezircioglu H. Islets of meningioma in an acoustic schwannoma in a patient with neurofibromatosis-2: Pathology and magnetic resonance imaging findings. *Acta Radiologica*. 2005; 46(5):519-22. [DOI:10.1080/02841850510021382] [PMID]
- [25] Ammoun S, Provenzano L, Zhou L, Barczyk M, Evans K, Hilton DA, et al. Axl/Gas6/NFκB signalling in schwannoma pathological proliferation, adhesion and survival. *Oncogene*. 2014; 33(3):336-46. [DOI:10.1038/ncr.2012.587] [PMID]
- [26] Eldridge R, Parry D. Vestibular schwannoma (acoustic neuroma). Consensus development conference. *Neurosurgery*. 1992; 30(6):962-4. [PMID]
- [27] Muzumdar DP, Goel A. Pathological laughter as a presenting symptom of acoustic schwannoma: Report of two cases. *Journal of Clinical Neuroscience*. 2003; 10(3):384-6. [DOI:10.1016/S0967-5868(03)00027-4]
- [28] Chuang WY, Yeh CJ, Jung SM, Hsueh S. Plexiform schwannoma of the clitoris. *APMIS: Acta Pathologica, Microbiologica, et Immunologica Scandinavica*. 2007; 115(7):889-90. [DOI:10.1111/j.1600-0463.2007.apm\_734.x] [PMID]
- [29] Moradi TH, Razmpa E, Abd Elahi R. Head and neck nerve sheath tumors: A 10-year evaluation in Iran. *Iranian Journal of Pathology*. 2009; 4(3):118-22. <https://www.sid.ir/en/Journal/ViewPaper.aspx?ID=144570>
- [30] Casadei GP, Komori T, Scheithauer BW, Miller GM, Parisi JE, Kelly PJ. Intracranial parenchymal schwannoma: A clinicopathological and neuroimaging study of nine cases. *Journal of Neurosurgery*. 1993; 79(2):217-22. [DOI:10.3171/jns.1993.79.2.0217] [PMID]
- [31] Louw D, Sutherland G, Halliday W, Kaufmann J. Meningiomas mimicking cerebral schwannoma. *Journal of Neurosurgery*. 1990; 73(5):715-9. [DOI:10.3171/jns.1990.73.5.0715] [PMID]
- [32] Isobe K, Shimizu T, Akahane T, Kato H. Imaging of ancient schwannoma. *American Journal of Roentgenology*. 2004; 183(2):331-6. [DOI:10.2214/ajr.183.2.1830331] [PMID]
- [33] Freeman SRM, Ramsden RT, Saeed SR, Alzoubi FQ, Simo R, Rutherford SA, et al. Revision surgery for residual or recurrent ves-

- tibular schwannoma. *Otology & Neurotology*. 2007; 28(8):1076-82. [DOI:10.1097/MAO.0b013e318159e76a] [PMID]
- [34] Ahmad RA, Sivalingam S, Topsakal V, Russo A, Taibah A, Sanna M. Rate of recurrent vestibular schwannoma after total removal via different surgical approaches. *Annals of Otology, Rhinology & Laryngology*. 2012; 121(3):156-61. [DOI:10.1177/000348941212100303] [PMID]
- [35] Sordillo PP, Helson L, Hajdu SI, Magill GB, Kosloff C, Golbey RB, et al. Malignant schwannoma-clinical characteristics, survival, and response to therapy. *Cancer*. 1981; 47(10):2503-9. [DOI:10.1002/1097-0142(19810515)47:103.0.CO;2-3] [PMID]
- [36] Song JY, Kim SY, Park EG, Kim CJ, Kim DG, Lee HK, et al. Schwannoma in the retroperitoneum. *The Journal of Obstetrics and Gynaecology Research*. 2007; 33(3):371-5. [DOI:10.1111/j.1447-0756.2007.00539.x] [PMID]