

Pediatric Idiopathic Intracranial Hypertension Post-Measles Vaccine: A Case Report



Ahmed Arafa Helaly* , Ahmed Ezzat, Mohammed Gamal Abdellatif

Department of Neurology, Faculty of Medicine, Sohag University, Sohag, Egypt.

Use your device to scan and read the article online



Citation Helaly AA, Ezzat A, Gamal Abdellatif M. Pediatric Idiopathic Intracranial Hypertension Post-Measles Vaccine: A Case Report. Case Reports in Clinical Practice .2021; 6(3):120-123.

Running Title Post Measles Vaccine Intracranial Hypertension

Article info:

Received: 05 Jun 2021

Revised: 22 Jun 2021

Accepted: 30 Jun 2021

Keywords:

Idiopathic intracranial hypertension; Lumbar puncture; Acetazolamide

ABSTRACT

Idiopathic intracranial hypertension is characterized by an increase in intracranial pressure with no significant structural cause. The diagnostic criteria include general signs and symptoms of generalized increased intracranial pressure or papilledema, increased Cerebrospinal Fluid (CSF) pressure (>250 mm H₂O), and normal brain imaging. It usually occurs in adults but rarely can be seen in children. We report a 7-year-old child with a manifestation of increased intracranial tension after the measles vaccine, associated with bilateral sixth nerve palsy and bilateral facial palsy with lower motor neuron features. Normal magnetic resonance imaging and CSF results were normal, except for an increase in CSF pressure. The symptoms began to be resolved after lumbar puncture with the complete resolution of symptoms after one and half months. We add also acetazolamide at the proper dose to reduce intracranial pressure from the first day of diagnosis.

Introduction

Idiopathic Intracranial Hypertension (IIH) is characterized by elevated intracranial pressure with no evidence of causes increasing intracranial pressure, such as infection, tumor, vascular cause, or hydrocephalus [1]. The incidence of pediatric IIH is around 0.5 per 100,000 children per year [2]. Regarding the incidence of pediatric IIH, there is an increase in its incidence among adolescents (12-15 years) compared with young children (2-12 years)

[3]. Obesity is considered as a risk factor for IIH in all age groups, 43% of patients aged 3-11 years were obese [4].

The diagnostic criteria for IIH in adults include general signs and symptoms of generalized increased intracranial pressure or papilledema, increased Cerebrospinal Fluid (CSF) pressure (>250 mm H₂O), no evidence of hydrocephalus, mass, structural, or vascular lesion on Magnetic Resonance Imaging (MRI) or contrast-enhanced computerized tomography, and no other identified cause of intracranial hypertension [5].

* Corresponding Author:

Ahmed A. Helaly, MD.

Address: Department of Neurology, Faculty of Medicine, Sohag University, Sohag, Egypt.

E-mail: ahmed.ahelaly@gmail.com



Figure 1. Left lower motor neuron facial palsy



The child was unable to completely close his left eye with diminution of the Left nasolabial fold.

The clinical features are different between different children with IIH, including headache, nausea, vomiting, blurred vision, diplopia due to nerve palsies, transient visual lights with preserved conscious level [6], and papilledema, which in children is resolved after 3-6 months of medical treatment [7].

Case Presentation

A 7-year-old male patient presented with acute-onset occipital headache with a dull aching character. It was not associated with photophobia or phonophobia, but he had recurrent vomiting. One day later, the child began to complain of diplopia with a deviation of the mouth to the right side and inability to fully close the left eye. Five days prior to the onset, the child received

the measles vaccine according to the mass campaign of the Ministry of Health in Egypt.

By examination, the child was irritable due to severe headaches and his vital signs were stable. Cranial nerve examination showed left facial muscles weakness with lower motor neuron features (Figure 1) in addition to bilateral abducens nerve palsy. Other neurological examination results included normal tone and reflexes with no irritative meningeal signs. Colored funduscopy showed bilateral papilledema (Figure 2). Investigations showed normal Complete Blood Count (CBC), liver, renal function tests, and serum electrolytes. Brain MRI with contrast and Magnetic Resonance Venography (MRV) were normal.

CSF aspiration was considered after brain MRI. CSF pressure was more than 40 cm H₂O. Clear aspect of CSF is an item of CSF analysis to exclude CNS infection as a cause of increase intracranial tension. Glucose level was 16 mg/dl and protein level was 10 mg/dl with 2 White Blood Cells (WBCs). Measles IgM was positive and IgG was negative due to recent vaccination. IgM and IgG in the CSF of measles were not evaluated. Diagnosis of IIH was made based on clinical and laboratory findings. Then, 15 cc of CSF was aspirated from the child who showed dramatic improvement of severe headache. After three days, the same amount was aspirated. Acetazolamide (25 mg/kg per day) and oral potassium intake was started from the first day.

One week later, the child showed partial improvement in left facial palsy and bilateral sixth nerve palsy. One and half months later and on medical treatment, both sixth and facial nerves palsy were completely resolved with no headache. Follow-up of fundus examination after two months showed resolution of papilledema.

Discussion

IIH can occur at any age, but it is very rare to occur in children [8]. In this case, the child presented by bilateral sixth nerve palsy in addition to left facial palsy with

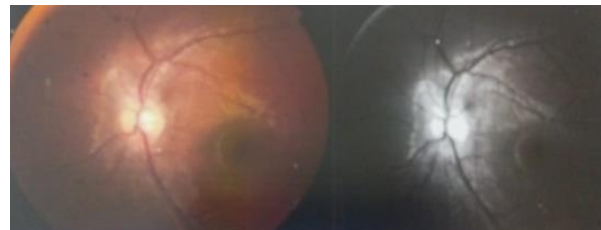
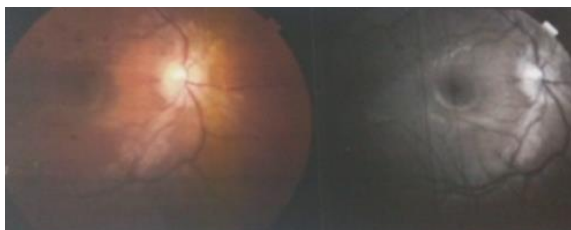


Figure 2. Fundus examination showed bilateral papilledema



lower motor neuron features, which is a false localizing sign with bilateral papilledema that fulfills the criteria of IIH with no evidence of radiological or clinical manifestations or laboratory evidence of infection or space-occupying lesion.

Obesity is an important risk factor of IIH, but other causes, such as endocrine abnormalities, effect of some drugs, and infections must be considered. IIH in children can be associated with recombinant (synthetic) growth hormone therapy, levonorgestrel implants, desmopressin nasal spray, cytarabine, All-Trans Retinoic Acid (ATRA) syndrome, such as Addison's disease, acute sinusitis, varicella, and Miller Fisher syndrome [7]. None of these cases were found in our case. Papilledema and sixth nerve palsy are described in the symptomatology of IIH [9] in addition to facial nerve palsy, which is observed in many cases with IIH [10].

Few cases have been reported with an association between measles vaccination and increased intracranial pressure. For example, a 10-month old male infant in India presented with sudden onset of medial deviation of eyes and irritability, papilledema, normal MRI, and elevated CSF pressure with recent measles vaccination [11]. Another 8-year-old girl with measles was found with a manifestation of increased intracranial tension, papilledema, normal MRI, and elevated CSF pressure [12]. In both cases, no known cause suggestive of IIH was observed; thus, measles can be regarded as the risk factor.

There is no report on cases with IIH associated with measles vaccination, except for the Indian infant who is similar to our case; thus, measles vaccination may be related to IIH; however, it cannot be considered as an etiology based on two cases only.

We considered therapeutic tapping in our case, which resulted in a dramatic improvement in neurological manifestations, such as headache, bilateral sixth nerve palsy, and facial nerve palsy, and the same case has been reported in the Indian infant with marked improvement in neonate irritability and sixth nerve palsy [12]. Also, medical treatment using acetazolamide was continued for three months after the insult and showed marked improvement in papilledema in the follow-up. Pediatric patients with IIH have a relatively favorable prognosis, with prompt diagnosis and treatment [12].

In conclusion, in any child presented with a manifestation of increased intracranial pressure, sixth nerve palsy, and elevated CSF pressure, and normal MRI, IIH

must be suspected in addition to considering the association between recent measles vaccination and IIH.

Ethical Considerations

Compliance with ethical guidelines

All ethical principles are considered in this article. The participant was informed of the purpose of the research and its implementation stages. He was also assured about the confidentiality of their information and were free to leave the study whenever they wished, and if desired, the research results would be available to them. A written consent has been obtained from the subjects. Principles of the Helsinki Convention was also observed.

Funding

This research did not receive any grant from funding agencies in the public, commercial, or non-profit sectors.

Conflict of interest

The authors declared no conflict of interest.

References

- [1] Friedman DI, Jacobson DM. Diagnostic criteria for idiopathic intracranial hypertension. *Neurology*. 2002; 59(10):1492-5. [DOI:10.1212/01.WNL.0000029570.69134.1B] [PMID]
- [2] Tibussek D, Distelmaier F, Von Kries R, Mayatepek E. Pseudotumor cerebri in childhood and adolescence—results of a Germany-wide ESPED-survey. *Klinische Pädiatrie*. 2013; 225(2):81-5. [DOI:10.1055/s-0033-1333757] [PMID]
- [3] Gordon K. Pediatric pseudotumor cerebri: Descriptive epidemiology. *The Canadian Journal of Neurological Sciences*. 1997; 24(3):219-21. [DOI:10.1017/S031716710002182X] [PMID]
- [4] Balcer LJ, Liu GT, Forman S, Pun K, Volpe NJ, Galetta SL, et al. Idiopathic intracranial hypertension: Relation of age and obesity in children. *Neurology*. 1999; 52(4):870-2. [DOI:10.1212/WNL.52.4.870] [PMID]
- [5] Friedman DI, Jacobson DM. Idiopathic intracranial hypertension. *Journal of Neuro-Ophthalmology*. 2004; 24(2):138-45. [DOI:10.1097/00041327-200406000-00009] [PMID]
- [6] Soler D, Cox T, Bullock P, Calver DM, Robinson RO. Diagnosis and management of benign intracranial hypertension. *Archives of Disease in Childhood*. 1998; 78(1):89-94. [DOI:10.1136/adc.78.1.89] [PMID] [PMCID]
- [7] Rangwala LM, Liu GT. Pediatric idiopathic intracranial hypertension. *Survey of Ophthalmology*. 2007; 52(6):597-617. [DOI:10.1016/j.survophthal.2007.08.018] [PMID]

- [8] Hartmann AJ, Peragallo JH. Pediatric Idiopathic Intracranial Hypertension. *Journal of Pediatric Neurology*. 2017; 15(01):053-61. [DOI:10.1055/s-0036-1593848]
- [9] Ko MW, Liu GT. Pediatric idiopathic intracranial hypertension (pseudotumor cerebri). *Hormone Research in Paediatrics*. 2010; 74(6):381-9. [DOI:10.1159/000321180] [PMID]
- [10] Phillips PH, Repka MX, Lambert SR. Pseudotumor cerebri in children. *Journal of American Association for Pediatric Ophthalmology and Strabismus*. 1998; 2(1):33-8. [DOI:10.1016/S1091-8531(98)90107-0] [PMID]
- [11] Gowda VK, Reddy B, Reddy H, Shivappa SK, Ramaswamy P, Gowda SH, et al. Idiopathic intracranial hypertension following measles vaccine. *Journal of Pediatric Neurology*. 2014; 12(01):055-8. <https://www.thieme-connect.com/products/ejournals/abstract/10.3233/JPN-140639>
- [12] Taşdemir HA, Dilber C, Totan M, Onder A. Pseudotumor cerebri complicating measles: A case report and literature review. *Brain and Development*. 2006; 28(6):395-7. [DOI:10.1016/j.braindev.2005.10.014] [PMID]