



Case Report

Journal Homepage: <http://crp.tums.ac.ir>

Successful Laparoscopy Management of a 20-cm Mass Causing 1260 Degrees Rotation of Adnexa in the First Trimester of Pregnancy: A Case Report

Shahla Noori Ardebili^{1*}, Samaneh Chegeni², Malihe Arab³, Ali Mehrafshar⁴

1. Department of Gynecology, Atieh Hospital, Tehran, Iran.

2. Department of Genetics, Reproductive Biomedicine Research Center, Royan Institute for Reproductive Biomedicine, Academic Center for Education, Culture and Research, Tehran, Iran.

3. Cancer Research Center, Shahid Beheshti University of Medical Sciences, Tehran, Iran.

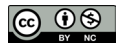4. School of Medicine, Zhejiang University, Hangzhou, China.

Use your device to scan and read the article online



Citation Noori Ardebili Sh, Chegeni S, Arab M, Mehrafshar A. Successful Laparoscopy Management of a 20-cm Mass Causing 1260 Degrees Rotation of Adnexa in the First Trimester of Pregnancy: A Case Report. Case Reports in Clinical Practice. 2021; 6(6):227-230.

Running Title Laparoscopy Management of Adnexal Torsion in Pregnancy

**Article info:****Received:** 24 Nov 2021**Revised:** 13 Dec 2021**Accepted:** 20 Dec 2021**Keywords:**

Adnexal torsion; Ovarian cyst; Pregnancy; Laparoscopy

ABSTRACT

Diagnosing and managing pelvic pain during pregnancy is often challenging. This pain can be obstetrical, gynecological, or non-obstetrical_non-gynecological. Ovarian torsion, recognized as the consequence of ovarian twisting on its supporting ligaments, causes gynecological pelvic pain. It can occur during pregnancy and cause emergencies. However, early detection can preserve the ovaries and maintain the patient's current and future fertility. Surgery is the gold standard for the diagnosis and treatment of ovarian torsion. Choosing the best surgical technique (laparoscopy or laparotomy) is essential to reduce possible complications during and after surgery. Our case is a 7-8 weeks' pregnant woman who underwent laparoscopic surgery with an ovarian mass of 85×152 mm and an acute abdomen. It was found that the mass has caused a 1260-degree rotation in the patient's left adnexa. The results during and after surgery and the condition of the mother and baby were favorable.

Introduction

M

ost adnexal masses in pregnancy are accidentally detected during routine pregnancy care. In the past, considering the lack of technology for early

detection, their detection rate was low; usually, these masses remained unidentified until cesarean section or being marked [1]. In general, the prevalence of adnexal masses in pregnancy is 1%-2% [2]. Moreover, 5%-20% of adnexal masses do not resolve spontaneously, become symptomatic during pregnancy, and require surgery [3].

*** Corresponding Author:****Shahla Noori Ardebili, MD.****Address:** Department of Gynecology, Atieh Hospital, Tehran, Iran.**E-mail:** dr.shahlanooriardabili@gmail.com

Sometimes, masses can cause adnexa twisting. Ovarian torsion occurs when the ovary, adnexa, or fallopian tube undergoes at least one complete rotation around a central axis consisting of tubo-ovarian and infundibulo-pelvic ligaments [4]. Torsion can disrupt ovarian blood flow, leading to stromal edema, hemorrhagic infarction, and eventually tissue necrosis [5]. This condition is rare during pregnancy and occurs about 1 per 5000 pregnancies [6]. The diagnosis of ovarian torsion during pregnancy is controversial because the symptoms are not specific. The organs inside the abdomen, especially the gravid uterus, have been displaced due to pregnancy. It seems that if a skilled and experienced team performs laparoscopic surgery during pregnancy, it is safe for the mother and the fetus and has advantages.

Case Presentation

The patient, a 34-year-old pregnant woman G3P2L2 (spontaneous pregnancy), who was at 6 weeks and 5 days based on CRL (crown-rump length) on vaginal ultrasound, who had a fetus with a marked heart rate, was referred to the clinic. The patient reported no surgery and had two previous normal vaginal deliveries. Ultrasound determined a 53×49×60 mm mass in the left ovary with a simple cyst view. The patient reported no pain or nausea. Besides, all vital signs were stable, with only occasional abdominal pain reported by the patient. The patient had no specific medical or family history and took only 1 mg of folic acid daily. The patient also denied a history of smoking, alcohol, or drug use and presented no drug or food allergies. The patient was requested to rest more and return to the clinic in severe pain. Control ultrasound was also requested to check the size of the mass a week later.

After 7 days, the patient was referred to the clinic with abdominal pain on the left side, i.e., started 15 hours ago and had intensified. Furthermore, the patient's nausea began 15 hours ago, and the patient vomited twice. The patient denied any recent illness, fever, chills, night sweats, nausea, vomiting, or suspected food intake. Physical examination revealed that active bowel sounds were positive. Murphy's sign was negative. No epigastric left or right upper quadrant tenderness and severe rebound tenderness in the left lower quadrant with guarding were seen. Examination of the vagina and cervix revealed that the cervix was posterior of a suitable length and is closed, and there was no vaginal discharge. The patient's vital signs were then checked.

The blood pressure was 100/60 mmHg. The heart rate was 80 beats per minute. The temperature was 37.8°C; the respiration rate was 14-16 per minute. The patient

was immediately admitted to the hospital, and an emergency abdominal and pelvic ultrasound was requested. Routine abdominal ultrasound was reported. However, in pelvic ultrasound, which was performed transvaginally, an 85×152 mm hypoechoic mass image containing a 54 mm diameter cystic segment in the left adnexa stretching to the lower abdomen was reported. According to CRL=22 mm, gestational age was 8 weeks and 5 days from LMP (last menstrual period), and the gestational sac containing the live embryo was detected. Blood tests, including CBC (complete blood count) diff, coagulation factors, and tumor markers, were requested. In the emergency department, the patient had stable vital signs.

According to laboratory studies, the hemoglobin level was 12.3 g/dL, platelet 253×103/micL, WBC (white blood cells) count 9.95×103/micL, Neutrophils 89.1%, Lymphocytes 7.9%, RBC (red blood cell) count 4.66×106/micL, SGPT (Serum Glutamic Pyruvic Transaminase) 25 U/L, SGOT (serum glutamic-oxaloacetic transaminase) 16 U/L, Patient PT (prothrombin time) 13 seconds, index INR (international normalized ratio) 1 and PTT (partial thromboplastin time) 32 seconds.

According to the ultrasound data and total evidence, the emergency decision was made to perform laparoscopic surgery to maintain ovarian function and prevent adverse effects on the mother and fetus. Considering the patient's pregnancy and the large mass, the entrance to the abdomen was performed with extreme caution. The entrance to the abdomen was performed openly with trocar number 12 from the supraumbilical area, the laparoscope camera was inserted into the abdomen, and CO₂ gas was blown into the abdominal cavity at a pressure of 10 mm Hg. The gas pressure is normally 12 mm Hg; we decreased this pressure due to the patient pregnancy. Then two trocars, number 5, were entered in the lateral sections and one in the suprapubic area. The mass was about 5 cm larger than the size reported in radiology and extended to the patient's spleen, creating a 1260-degree torsion (Figure 1). Considering the volume of the mass and tissue necrosis and the presence of numerous clots, there was no possibility of detorsion, and the left salpingo-oophorectomy was performed entirely (Figure 2). No particular complications were experienced during the laparoscopic surgery, and the operation was completed successfully after 35 minutes.

Additionally, after the end of anesthesia, the O₂ saturation rate was 99%. After surgery, and according to the response of the tumor markers and the patient's pathology, the hemorrhagic corpus luteum cyst and hemorrhage in the entire adnexa were confirmed. All tumor

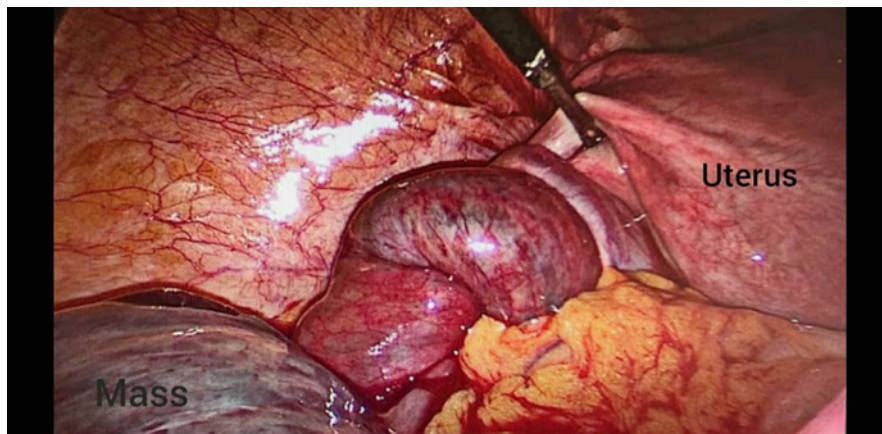


Figure 1. The laparoscopic view reveals a massive mass that creates a 1260-degree torsion in the left adnexa of 7-8 week pregnant women

markers except CA125 were in the normal range. The rate of this marker was reported to be 92.4, i.e., often considered normal due to the patient's pregnancy. After laparoscopy, the patient underwent a 400 mg daily rectal progesterone suppository and 10 mg progesterone tablet every 6 hours until 12 weeks of gestation. Finally, in the 38th week of pregnancy, the patient naturally entered the delivery phase, and the infant was born by the NVD (normal vaginal delivery) method with a 9/10 Apgar. After 5 minutes, a 10/10 Apgar was recorded.

Discussion

Most adnexal masses identified during pregnancy are below 5 cm and are simple benign cysts. Most of these cysts are caused by normal ovarian function, such as corpus luteum or follicular cysts. Most adnexal cystic masses, accidentally detected in the first trimester of pregnancy, are removed in the early second trimester without any intervention (about 70%), consistent with functional ovarian cysts [7]. Occasionally, adnexal masses can cause torsion. Ovarian torsion occurs in 5% of

pregnant women due to benign or malignant masses [8]. According to a review study, adnexal masses between 6-8 cm have the highest torsion rate than smaller or larger masses [9].

Emergency surgery during pregnancy is not typical for the management of torsion or torn masses, and the prevalence is less than 5% [8, 10]. It was initially assumed that laparoscopic surgery should not be performed in the first trimester of pregnancy. Still, various studies suggested that laparoscopy can be performed at any time during pregnancy with minimal associated complications for both mother and fetus. There were no cognitive or motor impairment reports in fetuses whose mothers underwent laparoscopy during pregnancy [3]. A study of 29 pregnant women undergoing laparoscopic appendectomy provided no movement, sensory or social defects in their children by age 3 [11].

Furthermore, the specific benefits of using this technique during pregnancy include less uterine manipulation than laparotomy. Laparoscopic surgery in the first

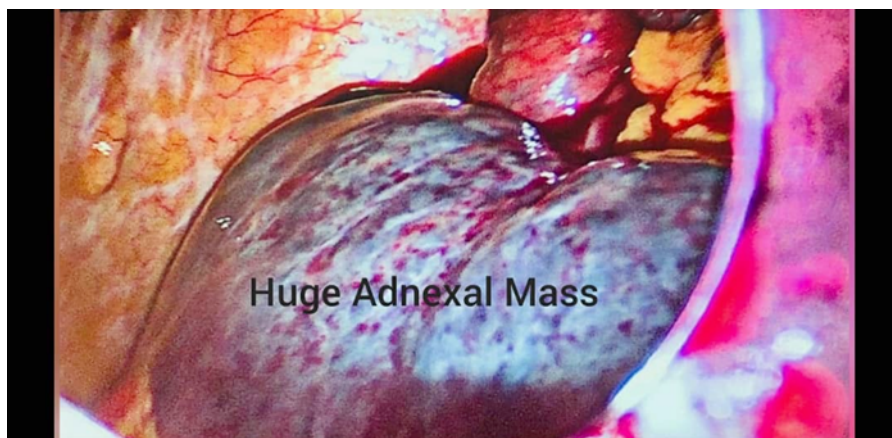

Figure 2. Laparoscopic view of 20cm adnexal mass with tissue necrosis and the presence of numerous clots

trimester of pregnancy is associated with an increased risk of miscarriage (12%) and possible teratogenicity [12]. However, if the pneumoperitoneal pressure remains below mmHg12 and the duration is less than 30 minutes, no adverse fetal adverse events are seen [13]. To be cautious and increase the quality of laparoscopic surgery, it is best to place the patient in the left lateral decubitus position to prevent uterine pressure on the inferior vena cava, fetal monitoring should be performed with vaginal ultrasound, intra-abdominal pressure should be maintained below 15 mmHg, and the mother Et-Co2 (End-tidal carbon dioxide) should be monitored and maintained within the normal range [14]. It is advisable to enter the abdomen with the Hasson technique and the open method; however, it is also possible if the Veress needle is used with sufficient skill and care [14]. A study published in 2019 found that the benefits of laparoscopic surgery in pregnant women for the treatment of adnexal masses include further minor bleeding, shorter hospital stay, and reduced preterm labor. Moreover, no significant findings related to the fetal loss were found between laparoscopic surgery and laparotomy [15].

Ethical Considerations

Compliance with ethical guidelines

All ethical principles are considered in this article. The participants were informed of the purpose of the research and its implementation stages. They were also assured about the confidentiality of their information and were free to leave the study whenever they wished, and if desired, the research results would be available to them. Written consent has been obtained from the subjects. Principles of the Helsinki Convention were also observed.

Funding

This research did not receive any grant from funding agencies in the public, commercial, or non-profit sectors.

Conflict of interest

The authors declared no conflict of interest.

References

- [1] Yacobozzi M, Nguyen D, Rakita D. Adnexal masses in pregnancy. In *Seminars in Ultrasound, CT and MRI*. 2012; 33(1):55-64. [DOI:10.1053/j.sult.2011.10.004] [PMID]
- [2] Bozzo M, Buscaglia M, Ferrazzi E. The management of persistent adnexal masses in pregnancy. *American journal of obstetrics and gynecology*. 1997; 177(4):981-2. [DOI:10.1016/S0002-9378(97)70315-6] [PMID]
- [3] George PE, Shwaartz C, Divino CM. Laparoscopic surgery in pregnancy. *World Journal of Obstetrics and Gynecology*. 2016; 5(2):175-81. [DOI:10.5317/wjog.v5.i2.175]
- [4] Huchon C, Fauconnier A. Adnexal torsion: A literature review. *European Journal of Obstetrics & Gynecology and Reproductive Biology*. 2010; 150(1):8-12. [DOI:10.1016/j.ejogrb.2010.02.006] [PMID]
- [5] Ssi-Yan-Kai G, Rivain AL, Trichot C, Morcelet MC, Prevot S, Deffieux X, et al. What every radiologist should know about adnexal torsion. *Emergency Radiology*. 2018; 25(1):51-9. [DOI:10.1007/s10140-017-1549-8] [PMID]
- [6] Hasson J, Tsafirir Z, Azem F, Bar-On S, Almog B, Mashiach R, et al. Comparison of adnexal torsion between pregnant and nonpregnant women. *American Journal of Obstetrics and Gynecology*. 2010; 202(6):536-e1-e6. [DOI:10.1016/j.ajog.2009.11.028] [PMID]
- [7] Robert L, Giuntoli II, Vang RS, Bristow RE. Evaluation and management of adnexal masses during pregnancy. *Clinical Obstetrics And Gynecology*. 2006; 49(3):492-505. [DOI:10.1097/00003081-200609000-00009] [PMID]
- [8] Schmeler KM, Mayo-Smith WW, Peipert JF, Weitzen S, Manuel MD, Gordnier ME. Adnexal masses in pregnancy: Surgery compared with observation. *Obstetrics & Gynecology*. 2005; 105(5):1098-103. [DOI:10.1097/01.AOG.0000157465.99639.e5] [PMID]
- [9] Yen CF, Lin SL, Murk W, Wang CJ, Lee CL, Soong YK, et al. Risk analysis of torsion and malignancy for adnexal masses during pregnancy. *Fertility and Sterility*. 2009; 91(5):1895-902. [DOI:10.1016/j.fertnstert.2008.02.014] [PMID]
- [10] Whitecar P, Turner S, Higby K. Adnexal masses in pregnancy: A review of 130 cases undergoing surgical management. *American Journal of Obstetrics and Gynecology*. 1999; 181(1):19-24. [DOI:10.1016/S0002-9378(99)70429-1] [PMID]
- [11] Choi JJ, Mustafa R, Lynn ET, Divino CM. Appendectomy during pregnancy: Follow-up of progeny. *Journal of the American College of Surgeons*. 2011; 213(5):627-32. [DOI:10.1016/j.jamcollsurg.2011.07.016] [PMID]
- [12] Soriano D, Yefet Y, Seidman DS, Goldenberg M, Mashiach S, Oelsner G. Laparoscopy versus laparotomy in the management of adnexal masses during pregnancy. *Fertility and Sterility*. 1999; 71(5):955-60. [DOI:10.1016/S0015-0282(99)00064-3] [PMID]
- [13] Curet MJ, Vogt DA, Schob O, Qualls C, Izquierdo LA, Zucker KA. Effects of CO2Pneumoperitoneum in Pregnant Ewes. *Journal of Surgical Research*. 1996; 63(1):339-44. [DOI:10.1006/jsre.1996.0272] [PMID]
- [14] Rauf A, Suraweera P, De Silva S. Operative laparoscopy; Is it a safe option in pregnancy? *Gynecological Surgery*. 2009; 6:381-4. [DOI:10.1007/s10397-008-0417-7]
- [15] Ye P, Zhao N, Shu J, Shen H, Wang Y, Chen L, et al. Laparoscopy versus open surgery for adnexal masses in pregnancy: A meta-analytic review. *Archives of Gynecology and Obstetrics*. 2019; 299:625-34. [DOI:10.1007/s00404-018-05039-y] [PMID] [PMCID]