

# Antenatally Diagnosed Fetal Subdural Hematoma: A Case Report



Ameneh Abiri<sup>1</sup> , Masoumeh Saleh<sup>1\*</sup> , Azadeh Shabani<sup>2</sup>

1. Department of Obstetrics and Gynecology, Arash Hospital, School of Medicine, Tehran University of Medical Sciences, Tehran, Iran.  
 2. Preventative Gynecology Research Center, Shahid Beheshti University of Medical Sciences, Tehran, Iran.



**Citation** Abiri A, Saleh M, Shabani A. Antenatally Diagnosed Fetal Subdural Hematoma: A Case Report. Case Reports in Clinical Practice. 2021; 6(6):259-264.

**Running Title** Subdural Hematoma and Alloimmune Thrombocytopenia



## Article info:

**Received:** 11 Nov 2021

**Revised:** 06 Dec 2021

**Accepted:** 18 Dec 2021

## Keywords:

Fetal-neonatal alloimmune thrombocytopenia; Intracranial hemorrhage; Subdural hematoma

## ABSTRACT

Fetal and Neonatal Alloimmune Thrombocytopenia (FNAIT) is a disease that affects babies. In FNAIT, the platelet count is decreased because the mother's immune system attacks her fetus platelets. A low platelet count increases the risk of bleeding in the fetus and newborn. FNAIT is the leading cause of severe thrombocytopenia in the fetus and neonate. The most severe complication of FNAIT is intracranial hemorrhage, which occurs in 10%-20% of symptomatic infants. If the bleeding occurs in the brain, there may be long-term effects. The Pathophysiology of atraumatic fetal Subdural Hematoma (SDH) remains unknown. It is extrapolated from the SDH of a shaken baby syndrome in infants. A detailed prenatal investigation is crucial to elucidate the underlying etiology, which may be associated with a better prognosis. We present a case of antenatally diagnosed SDH secondary to FNAIT that was normal up to one month after follow-up.

## Introduction

**F**etal and Neonatal Alloimmune Thrombocytopenia (FNAIT) is a disease that affects babies. FNAIT is the leading cause of severe thrombocytopenia in the fetus and neonate. The most severe complication of FNAIT is intracranial hemorrhage, which occurs in 10%-

20% of symptomatic infants. If the bleeding occurs in the brain, there may be long-term effects [1, 2].

Fetal Intracranial Hemorrhage (ICH) may result in significant fetal and neonatal mortality and long-term neurological morbidity in surviving babies. The estimated incidence is 0.6-1/1,000 [3-5]. Still, the true incidence is difficult to ascertain because of under-diagnosis and

## \*Corresponding Author:

**Masoumeh Saleh, Perinatology Fellowship.**

**Address:** Department of Obstetrics and Gynecology, Arash Hospital, School of Medicine, Tehran University of Medical Sciences, Tehran, Iran. **E-mail:** [salehmaasoumeh@yahoo.com](mailto:salehmaasoumeh@yahoo.com)



the varied description used in the literature, including fetal stroke, prenatal cerebrovascular disorder, or inclusion in the series of perinatal stroke and perinatal brain injury [6]. Depending on the anatomical location, ICH may be sub-classified into intra-ventricular, intra-cerebral, cerebellar, subarachnoid, and subdural [7]. A Subdural Hematoma (SDH) is a bleeding condition in which a collection of blood gathers between the inner layer of the dura mater and the arachnoid mater of the meninges surrounding the brain. It usually results from tears in bridging veins that cross the subdural space. Hemorrhage in a subdural location has been mainly related to maternal trauma, often causing utero-placental or other fetal injuries [8].

FNAIT is caused by maternal antibodies raised against alloantigens carried on fetal platelets. Platelets are blood cells, i.e., essential in helping blood clot. All platelets have natural proteins on their surface called Human Platelet Antigens (HPAs). Half of these antigens are inherited from the mother and half from the father in babies. Some of the baby's platelets can cross into the mother's bloodstream during pregnancy.

In most cases, this does not cause a problem. But in cases of FNAIT, the mother's immune system does not recognize the baby's HPAs inherited from the father and develops antibodies; it can cross the placenta and attack the baby's platelets. These antibodies are called anti-HPAs, and the commonest antibody implicated is anti-HPA-1a; however, there are other rarer antibody types. The baby's platelets may be destroyed if this happens, causing their platelet count to fall dangerously low [9]. Numerous cases are mild; however, FNAIT is a significant cause of morbidity and mortality in newborns and is the most common cause of intracranial hemorrhage in full-term infants.

Advances in ultrasound imaging have increased this entity's prenatal detection, which is generally associated with poor prognosis [7]. Ultrasonography can be used to detect, classify, and monitor the progression of various types of ICH [5]. The overall adverse perinatal outcomes of fetal SDH include stillbirth, neonatal death, and abnormal neurological development [3, 10, 11]. Recognition is important because of the potential for poor outcomes with the consequent implications for pregnancy management and the possibility of recurrence in future pregnancies in conditions such as alloimmune thrombocytopenia [6]. VIG (intravenous immune globulin) should be provided to women whose pregnancies are at risk of FNAIT. Following one pregnancy affected by FNAIT, maternal IVIG would normally be

first-line therapy in the subsequent pregnancy at 1g/kg/week from 18 weeks of gestation [12, 13]. In continuing pregnancies, the elective cesarean section should be planned after 36 weeks' gestation, depending on the ultrasound finding, to reduce the possible risk of further intracranial bleeding during labor [14].

## Case Presentation

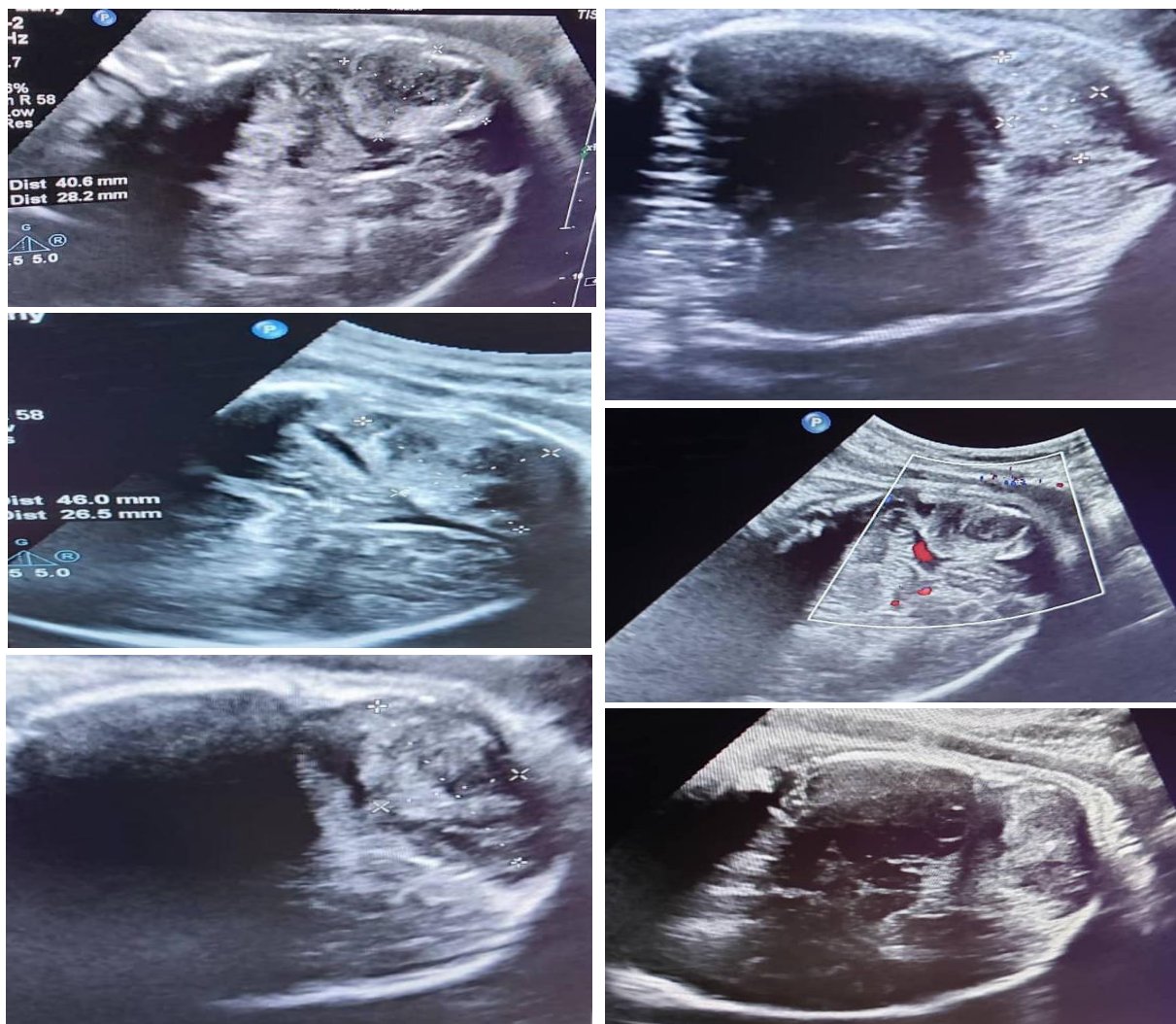
The case was a pregnant woman referring to our center due to fetal intracranial hemorrhage reported in fetal ultrasound at 36 weeks gestation. Mother was a 32-year-old woman, Gravida 3 and Parity 2. She reported no history of medical diseases and drug usage during this pregnancy. Furthermore, she had no history of trauma to the abdomen. She had two normal-term vaginal deliveries in obstetric history without any problem in her fetuses. General physical examination was regular. Hemoglobin (Hgb), platelet count, and coagulation factors were normal in her lab tests. In our center, fetal ultrasound showed a 40×28 mm hyper-echoic mass in the brain in the posterior fossa (right occipital lobe) without vascular components, suggestive of subdural hematoma (Figure 1). It had a compressive effect on the cerebellum and caused the cerebellum to shift. Fetal growth and amniotic fluid volume were average. No ventriculomegaly and hydrocephalous were detected. We detected no fetal anomaly.

Moreover, other structures of the Central Nervous System (CNS) were normal in ultrasound. Middle Cerebral Artery (MCA) Doppler indices and infections lab tests were normal. In serial ultrasound, the size of the lesion was stable. Finally, pregnancy terminated at 38 weeks gestation with cesarean section.

The baby girl weighing 3000 grams was born with a good APGAR score and normal PH in ABG. After birth, the neonate was visited by a pediatrician and neurosurgeon. The neonate presented no change in the level of consciousness, nausea, and vomiting. Her reflexes were healthy in physical examination. No focal neurological signs and Fontanella bulging were detected.

Additionally, her head circumference was normal. We did not find any signs of bleeding in other organs in general physical examination. Brain ultrasound demonstrated a 25×50 mm subdural hematoma in the right occipital lobe with pressure effect on the cerebellum; however, without active bleeding in the brain, intra-ventricular hemorrhage, hydrocephalous, or increased intracranial pressure. She received anticonvulsant prophylaxis.

Head circumference was serially checked, i.e., normal. In the serial examination and fetal brain ultrasound, the



**Figure 1.** Cerebral subdural hematoma in the right occipital lobe

size of the hematoma was stable. The neonate tolerated breastfeeding. Hgb, coagulation profile, and TORCH study were normal in her lab tests, and COVID-19 PCR was negative, but she had thrombocytopenia (platelet: 72,000). With the diagnosis of FNAIT, IVIG was started. Her platelet increased after 4 doses of IVIG to 160,000. Also, during admission, she underwent phototherapy due to hyperbilirubinemia. After 10 days, the neonate was discharged with good condition, normal platelet, and the hematoma was 45×25 mm. The size of the hematoma decreased in follow-up and completely disappeared after a month in brain MRI. After one month, her neurological examination and platelet count were normal. Long-term follow-up is needed for further neurological evaluation.

## Discussion

Fetal ICH is a rare condition. With the widespread use of obstetric ultrasound, many cases of fetal intracranial

hemorrhage have been detected in utero before the onset of labor [14]. ICH in the fetus can be intra-axial or extra-axial [4]. As many of these cases were associated with placental abruption, or Intrauterine Growth Retardation (IUGR), the exact hypoxic/asphyxic pathogenesis that is often relevant in newborns was hypothesized to be so in fetuses [15, 16]. In other cases, fetal ICH has been linked to fetal thrombocytopenia or coagulation disorders [17, 18]. Hemorrhage in a subdural location has been mainly related to maternal trauma, often causing utero-placental or other fetal injuries [8]. Minor maternal trauma resulting from, e.g., abdominal massage has also been related to intracranial, especially subdural hemorrhage [19, 20].

Furthermore, fetal intracranial hemorrhage has also been described in association with various maternal pathologies, such as pancreatitis, cholecystectomy, seizures, and cytomegalovirus infection. It has also been



associated with amniocentesis [14]. However, many cases remain unexplained [1]. Identifying the specific etiology is essential, as it may change the course of the current pregnancy or impact future pregnancies [6]. The workup of any fetal abnormality requires a detailed history, including all forms of trauma; direct questions regarding injury are essential, as adverse fetal consequences may be seen with even minor degrees of damage [14, 21-23]. A complete record of maternal drugs of abuse such as cocaine or methamphetamine usage and over-the-counter medications such as aspirin is needed. Coumadin should rarely be encountered in pregnancy, but heparin is used in patients with thrombophilia [6]. In pregnant females, factor V Leiden and SSA/SSB antibody positivity and full-blown systemic lupus erythematosus are causes of thrombophilia and the rare but potentially devastating paroxysmal nocturnal hemoglobinuria [24]. FNAIT is the most frequent cause of isolated severe thrombocytopenia in the fetus and neonate [25-27]. It is generated by maternal alloantibodies against antigens of paternal origin on fetal platelets, resulting in platelet destruction and severe fetal and neonatal thrombocytopenia [28]. The most feared complication of severe neonatal thrombocytopenia is ICH; it occurs with an incidence of 14%-20% in untreated first pregnancies affected by FNAIT [29-31]. Most of these hemorrhages arise at the end of the second trimester, and clinical outcomes are devastating in most cases [32, 33].

Ultrasound is the initial screening modality for fetal anatomy. The differential diagnosis of some of the sonographic findings in ICH is broad. MRI helps exclude ICH and confirm its presence; however, it is an expensive imaging modality and not always locally available [6]. The main treatment goal in FNAIT is to prevent ICH from occurring either antenatally or during delivery. A non-invasive strategy with the antenatal weekly injection of IVIG given to the mother is nowadays considered the optimal antenatal management in FNAIT.

Invasive approaches with repeated fetal blood sampling and intrauterine platelet transfusions are associated with procedure-related complications such as rupture of membrane, bleeding from the puncture site, and acute fetal distress and are no longer regarded as primary management options [34-36]. In the USA, fetuses with ICH are delivered by cesarean section to avoid additional bleeding due to head compression during labor and vaginal delivery [6]. The route of delivery in our case was a cesarean section.

In a study by Cheung et al. [7], the typical neurological outcome was observed in 58% of the survivors, whereas the remaining 42% had neurological morbidity. Optimization of antenatal care and avoidance of trauma to

reverse or reduce further bleeds may be contributing factors for better outcomes in cases with determined bleeding tendencies.

Non-invasive antenatal treatment of FNAIT with weekly maternal IVIG and, if necessary, postnatal transfusion of matched platelets is safe and effective (matched platelets to non-bleeding neonates with a platelet count of <20000 and bleeding neonates with a platelet count <50000). In general, postnatal administration of IVIG can be helpful in addition to platelet transfusion [37, 38].

## Conclusion

FNAIT is the most common cause of severe thrombocytopenia and ICH among term infants. To prevent the devastating and potentially life-threatening manifestations of the disease, the goal is to initiate treatment early. A diagnosis should be considered for any neonate with unexplained thrombocytopenia. Once the diagnosis is established, it is known that all subsequent pregnancies are at risk for severe disease.

## Ethical Considerations

### Compliance with ethical guidelines

The patient signed a written consent form freely for publishing/using of her medical data.

### Funding

The research did not receive any grant from funding agencies in the public, commercial, or non-profit sectors.

### Conflict of interest

The authors declared no conflict of interest.

## References

- [1] Duhaime AC, Gennarelli TA, Thibault LE, Bruce DA, Margulies SS, Wiser R. The shaken baby syndrome. A clinical, pathological, and biomechanical study. *Journal of Neurosurgery*. 1987; 66(3):409-15. [DOI:10.3171/jns.1987.66.3.0409] [PMID]
- [2] Brown JK, Minns RA. Non-accidental head injury, with particular reference to whiplash shaking injury and medico-legal aspects. *Developmental Medicine & Child Neurology*. 1993; 35(10):849-69. [DOI:10.1111/j.1469-8749.1993.tb11563.x] [PMID]
- [3] Vergani P, Strobelt N, Locatelli A, Paterlini G, Tagliabue P, Parravicini E, et al. Clinical significance of fetal intracranial hemorrhage. *American Journal of Obstetrics and Gynecology*. 1996; 175(3):536-43. [DOI:10.1053/ob.1996.v175.a73598] [PMID]

- [4] Kutuk MS, Yikilmaz A, Ozgun MT, Dolanbay M, Canpolat M, Uludag S, et al. Prenatal diagnosis and postnatal outcome of fetal intracranial hemorrhage. *Child's Nervous System*. 2014; 30(3):411-18. [DOI:10.1007/s00381-013-2243-0] [PMID]
- [5] Abdelkader MA, Ramadan W, Gabr AA, Kamel A, Abdelrahman RW. Fetal intracranial hemorrhage: sonographic criteria and merits of prenatal diagnosis. *The Journal of Maternal-Fetal & Neonatal Medicine*. 2017; 30(18):2250-6. [DOI:10.1080/14767058.2016.1245283] [PMID]
- [6] Putbrese B, Kennedy A. Findings and differential diagnosis of fetal intracranial hemorrhage and fetal ischemic brain injury: What is the role of fetal MRI? *The British Journal of Radiology*. 2017; 90(1070):20160253. [DOI:10.1259/bjr.20160253] [PMID] [PMCID]
- [7] Cheung KW, Tan LN, Seto MTY, Moholkar S, Masson G, Kilby MD. Prenatal diagnosis, management, and outcome of fetal subdural hematoma: A case report and systematic review. *Fetal Diagnosis and Therapy*. 2019; 46(5):285-95. [DOI:10.1159/000496202] [PMID]
- [8] Larroche JC. Fetal cerebral pathology of circulatory origin. In: Levene MI, Lilford LJ, editors. *Fetal and Neonatal Neurology and Neurosurgery*. Edinburgh: Churchill Livingstone; 1994. 321-324. [Fetal and neonatal neurology and neurosurgery \(1994 edition\) | Open Library](#)
- [9] Regan F, Lees CC, Jones B, Nicolaidis KH, Wimalasundera RC, Mihovic A. Royal college of obstetricians and gynaecologists. Prenatal management of pregnancies at risk of fetal neonatal alloimmune thrombocytopenia (FNAIT). *An International Journal of Obstetrics and Gynecology*. 2019; 126(10):173-85. [DOI:10.1111/1471-0528.15642] [PMID]
- [10] Akman CI, Cracco J. Intrauterine subdural hemorrhage. *Developmental Medicine and Child Neurology*. 2000; 42(12):843-6. [DOI:10.1111/j.1469-8749.2000.tb00699.x] [PMID]
- [11] Chi T, Simonazzi G, Perolo A, Savelli L, Sandri F, Bernardi B, et al. Outcome of antenatally diagnosed intracranial hemorrhage: Case series and review of the literature. *Ultrasound in Obstetrics and Gynecology*. 2003; 22(2):121-30. [DOI:10.1002/uog.191] [PMID]
- [12] Birchall JE, Murphy MF, Kaplan C, Kroll H. European feto-maternal alloimmune thrombocytopenia study group. European collaborative study of the antenatal management of feto-maternal alloimmune thrombocytopenia. *British Journal of Haematology*. 2003; 122(2):275-88. [DOI:10.1046/j.1365-2141.2003.04408.x] [PMID]
- [13] Kahai HH, van den Akker ES, Walther FJ, Brand A. Intravenous immunoglobulins without initial and follow-up cordocentesis in alloimmune fetal and neonatal thrombocytopenia at high risk for intracranial hemorrhage. *Fetal Diagnosis and Therapy*. 2006; 21(1):55-60. [DOI:10.1159/000089048] [PMID]
- [14] Sringini FAL, Cioni G, Canapicchi R, Nardini V, Carpiello P, Carmignani A. Fetal intracranial hemorrhage: Is minor maternal trauma a possible pathogenic factor? *Ultrasound Obstet Gynecol*. 2001; 18(4):335-42. [DOI:10.1046/j.0960-7692.2001.00486.x] [PMID]
- [15] Belfer HL, Kuller JA, Hill LM, Kislak S. Evolving fetal hydranencephaly mimicking intracranial neoplasm. *Journal of Ultrasound in Medicine*. 1991; 10(4):231-33. [DOI:10.7863/jum.1991.10.4.231] [PMID]
- [16] Bondurant S, Boehm FH, Fleischer AC, Machin JE. Antepartum diagnosis of fetal intracranial hemorrhage by ultrasound. *Obstetrics and Gynecology*. 1984; 63(3 Suppl):25S-7S. [PMID]
- [17] Leidig E, Dannecker G, Pfeiffer KH, Salinas R, Pfeiffer J. Intrauterine development of posthemorrhagic hydrocephalus. *European Journal of Pediatrics*. 1998; 147(1):26-9. [DOI:10.1007/BF00442606] [PMID]
- [18] De Vries LS, Connell J, Bydder GM, Dubowitz LMS, Rodeck CH, Mibashan RS, et al. Recurrent intracranial hemorrhage in utero in an infant with alloimmune thrombocytopenia. *Case Report. BJOG: An International Journal of Obstetrics & Gynaecology*. 1998; 95(3):299-302. [DOI:10.1111/j.1471-0528.1988.tb06873.x] [PMID]
- [19] Gunn TR, Mok PM, Becroft DM. Subdural hemorrhage in utero. *Pediatrics*. 1985; 76(4):605-10. [DOI:10.1542/peds.76.4.605] [PMID]
- [20] Gunn TR, Mora JD, Becroft DMO. Congenital hydrocephalous secondary to prenatal intracranial hemorrhage. *Australian and New Zealand Journal of Obstetrics and Gynaecology*. 1988; 28(3):197-200. [DOI:10.1111/j.1479-828X.1988.tb01663.x] [PMID]
- [21] Farmer DL, Adzick NS, Crombleholme WR, Crombleholme TM, Longaker MT, Harrison MR. Fetal trauma: Relation to maternal injury. *Journal of Pediatric Surgery*. 1990; 25(7):711-14. [DOI:10.1016/S0022-3468(05)80002-8] [PMID]
- [22] Chames MC, Pearlman MD. Trauma during pregnancy: Outcomes and clinical management. *Clinical Obstetrics and Gynecology*. 2008; 51(2):398-408. [DOI:10.1097/GRF.0b013e31816f2aa7] [PMID]
- [23] Mastushita H, Harada A, Sato T, Kurabayashi T. Fetal intracranial injuries following motor vehicle accidents with airbag deployment. *Journal of Obstetrics and Gynaecology Research*. 2014; 40(2):599-602. [DOI:10.1111/jog.12188] [PMID]
- [24] American College of Obstetricians and Gynecologists Women's Health Care Physicians. ACOG Practice Bulletin No. 138: Inherited thrombophilias in pregnancy. *Obstetrics Gynecology*. 2013; 122(3):706-16. [DOI:10.1097/01.AOG.0000433981.36184.4e] [PMID]
- [25] Katz D, Beilin Y. Disorders of coagulation in pregnancy. *British Journal of Anaesthesia*. 2015; 115(Suppl 2):ii75-ii88. [DOI:10.1093/bja/aev374] [PMID]
- [26] Bussel JB, Zacharoulis S, Kramer K, McFarland JG, Pauliny J, Kaplan C. Clinical and diagnostic comparison of neonatal alloimmune thrombocytopenia to non-immune cases of thrombocytopenia. *Pediatr Blood Cancer*. 2005; 45(2):176-83. [DOI:10.1002/pbc.20282] [PMID]
- [27] Burrows RF, Kelton JG. Fetal thrombocytopenia and its relation to maternal thrombocytopenia. *New England Journal of Medicine*. 1993; 329(20):14636. [DOI:10.1056/NEJM19931113292005] [PMID]
- [28] Dreyfus M, Kaplan C, Verdy E, Schlegel N, Durand-Zaleski I, Tchernia G. Frequency of immune thrombocytopenia in newborns: A prospective study. *Immune thrombocytopenia working group. Blood*. 1997; 89(12):4402-6. [DOI:10.1182/blood.V89.12.4402] [PMID]
- [29] Pearson HA, Shulman NR, Marder VJ, Cone TJR. Isoimmune neonatal thrombocytopenic purpura. *Clinical and therapeutic considerations. Blood*; 1964; 23(2):154-77. [DOI:10.1182/blood.V23.2.154.154] [PMID]
- [30] Knight M, Pierce M, Allen D, Kurinczuk JJ, Spark P, Roberts DJ et al. The incidence and outcomes of feto-maternal alloimmune thrombocytopenia: A UK national study using three data sources. *British Journal of Haematology*. 2011; 152(2):460-8. [DOI:10.1111/j.1365-2141.2010.08540.x] [PMID]
- [31] Mueller-Eckhardt C, Kiefel V, Grubert A, Kroll H, Weisheit M, Schmidt S, et al. 348 cases of suspected neonatal alloimmune thrombocytopenia. *Lancet*. 1989; 333(8634):363-6. [DOI:10.1016/S0140-6736(89)91733-9] [PMID]
- [32] Bussel JB, Zabusky MR, Berkowitz RL, McFarland JG. Fetal alloimmune thrombocytopenia. *New England Journal of Medicine*. 1997; 337(1):22-6. [DOI:10.1056/NEJM199707033370104] [PMID]

- [33] Spencer JA, Burrows RF. Feto-maternal alloimmune thrombocytopenia: A literature review and statistical analysis. *Australian and New Zealand Journal of Obstetrics and Gynaecology*. 2001; 41(1):45-55. [DOI:10.1111/j.1479-828X.2001.tb01293.x] [PMID]
- [34] Tiller H, Kamphuis MM, Flodmark O, Papadogiannakis N, David AL, Sainio S, et al. Fetal intracranial hemorrhage caused by fetal and neonatal alloimmune thrombocytopenia: An observational cohort study of 43 cases from an international multicenter registry. *BMJ Open*. 2013; 3(3):e0024490. [DOI:10.1136/bmjopen-2012-002490] [PMID] [PMCID]
- [35] van den Akker ESA, Oepkes D, Lopriore E, Brand A, Kanhai HHH. Non-invasive antenatal management of fetal and neonatal alloimmune thrombocytopenia: Safe and effective. *BJOG: An International Journal of Obstetrics & Gynaecology*. 2007; 114(4):469-73. [DOI:10.1111/j.1471-0528.2007.01244.x] [PMID]
- [36] Berkowitz RL, Kolb EA, McFarland JG, Wissert M, Primani A, Lesser M, et al. Parallel randomized trials of risk-based therapy for fetal alloimmune thrombocytopenia. *Obstetrics & Gynecology*. 2006; 107(1):91-6. [DOI:10.1097/01.AOG.0000192404.25780.68] [PMID]
- [37] Rayment R, Brunskill SJ, Sothill PW, Roberts DJ, Bussell JB, Murphy MF. Antenatal interventions for feto-maternal alloimmune thrombocytopenia. *Cochrane Database of Systematic Reviews*. 2011;(5):CD004226. [DOI:10.1002/14651858.CD004226.pub3] [PMID]
- [38] van der Lugt NM, Kamphuis MM, Paridaans NPM, Figue A, Oepkes D, Walther FJ, et al. Neonatal outcome in alloimmune thrombocytopenia after maternal treatment with intravenous immunoglobulin. *Blood Transfusion*. 2015; 13(1):66-71. [DOI:10.2450/2014.0309-13] [PMID][PMCID]