



## Case Report

Journal Homepage: <http://crcp.tums.ac.ir>

# Benign Metastasizing Leiomyoma of the Lung: A Case Report

Marzieh Pazoki<sup>1</sup>, Elham Nazar<sup>2\*</sup>, Behnaz Jahanbin<sup>3</sup>

1. Department of Pulmonary Medicine, Sina Hospital, Tehran University of Medical Sciences, Tehran, Iran.

2. Department of Pathology, Sina Hospital, Tehran University of Medical Sciences, Tehran, Iran.

3. Department of Pathology, Imam Khomeini Complex Hospital, Tehran University of Medical Sciences, Tehran, Iran.



**Citation** Pazoki M, Nazar E, Jahanbin B. Benign Metastasizing Leiomyoma of the Lung: A Case Report. Case Reports in Clinical Practice. 2022; 7(2): 86-90.

**Running Title** Benign Metastasizing leiomyoma

**Article info:****Received:** 23 March 2022**Revised:** 04 May 2022**Accepted:** 16 May 2022**Keywords:**

Leiomyoma; Lung; Metastasis

**ABSTRACT**

Benign metastasizing leiomyoma of the lung which is categorized by the growth of uterine leiomyoma in the lung is an extremely exceptional disease.

We report a 39-year-old woman who had a previous history of uterine leiomyoma. Chest computed tomography (CT) scan exhibited round nodules well-defined margins in both lungs. Thoracoscopic partial resection of the lung was done. Pathological and immunohistochemical examination showed that neoplastic tissue composed of spindle-shaped smooth muscle cells, compatible with uterine leiomyoma. Thus, these tumors can be reflected to be lung metastases from a uterine leiomyoma (benign metastasizing leiomyoma).

It is an uncommon condition but it would be careful in women of re-productive age with a past medical history of uterine leiomyoma, who existing with pulmonary nodules.

**Introduction**

Uterine leiomyoma is a benign tumor of smooth muscle derivation and is a very common gynecological tumor in women of reproductive age. A rare benign uterine leiomyoma displays unusual growing patterns accompanying by extra-uterine benign looking smooth muscle tumors, like to the smooth muscle cells originated in a uterine

leiomyoma [1]. Benign metastasizing leiomyoma (BML) is the word used to describe a divisive object regarded as a proliferation of bland-looking smooth muscle in lung or abdominopelvic lymph nodes [2]. BML is not a well-known clinicopathological condition which structures are histologically benign 'metastatic' smooth muscle tumor [3]. The identification of BML is founded on the past medical history of leiomyoma in uterine and histopathologic and immunohistochemical investigation of lung nodules. Pulmonary metastases

**\* Corresponding Author:****Elham Nazar****Address:** Department of Pathology, Sina Hospital, Tehran University of Medical Sciences, Tehran, Iran.**E-mail:** [elhamnazar@yahoo.com](mailto:elhamnazar@yahoo.com)

are usually asymptomatic and distinguished by chest radiological studies. Some patients have symptoms including cough, pain, or dyspnea; however they are frequently linked with primary conditions including pneumonia or bronchitis [4]. Even though it is an exceptional situation, it should be careful in women of reproductive age with a history of uterine leiomyoma, who present with solitary or multiple pulmonary nodules. Herein, we report a case of pulmonary benign metastasizing leiomyoma in a woman with asthma presentation.

### Case presentation

A 39-year old female who presented in the department of pulmonary disease in Sina hospital affiliated with Tehran University of Medical Sciences with a several years' history of cough and shortness of breath. The patient diagnosed as Asthma from years ago who underwent Asthma's treatment. At first, outpatient examination findings were unremarkable. The patient's family history and past medical history was unremarkable. General examination was negative. Routine laboratory investigations were normal. Chest X-ray showed bilateral multiple nodules. The patient underwent chest computed tomography (CT) scan which revealed round nodules with well-defined margins in both lungs (Fig. 1).

Therefore, imaging diagnosis of metastasis of the lung was virtually possible. Diagnosis required histopathologic examination. For found a conclusion, we done a pulmonary wedge resection by video-assisted thoracoscopic surgery and resected one of the largest nodules, which was placed at the periphery of the right lung. A wedge biopsy shown the pulmonary nodule containing of branching airway structures delimited by rich smooth muscle cells with no atypia. We did a gynecologic investigation to detect the primary origin of the pulmonary smooth muscle tumors. A uterine leiomyoma was found on sonography. As a result, we diagnosed the pulmonary lesions as BMLs. The pathology description discovered that neoplastic tissues consisted of well differentiated spindle shaped cells with no nuclear atypia. Moreover, there were no mitotic figures and necrosis (Fig. 2). Immunohistochemical examination for smooth muscle actin (SMA), desmin, and estrogen receptor (ER) was positive and Human Melanoma Black-45 (HMB-45) was negative (Fig. 3). The final pathology findings ruled out the probability of leiomyosarcoma or other metastatic diseases, and established that the pulmonary lesions were BML. But, she couldn't tolerate well the procedure and she had massive emphysema after wedge biopsy which underwent treatment in our hospital for a week. Thus, based on the diagnosis, the patient referred to gynecologist.

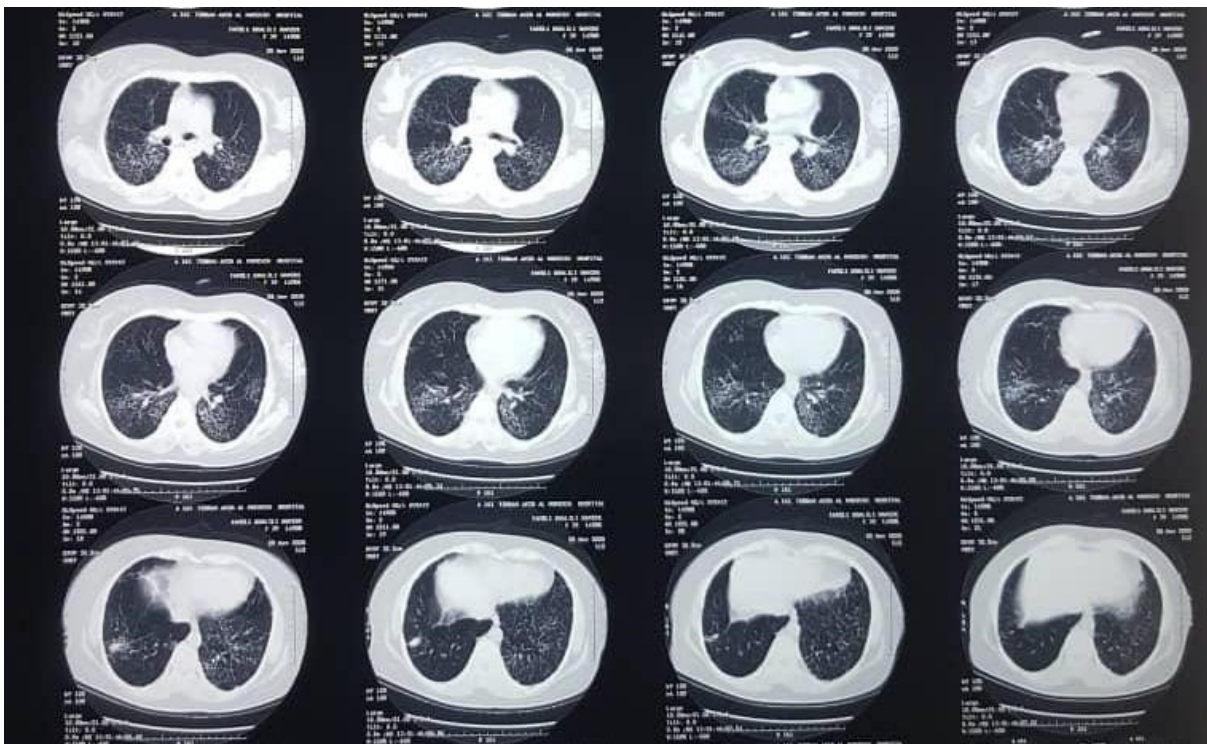
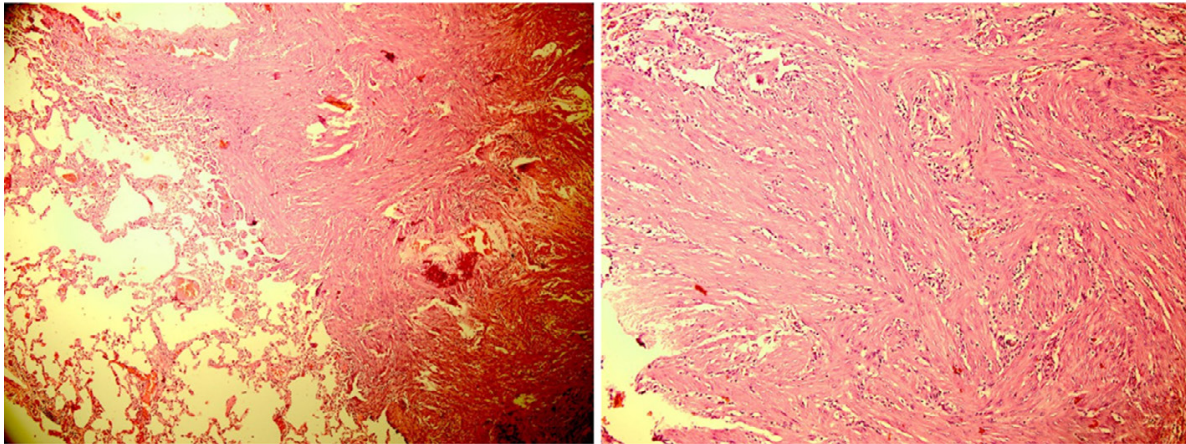
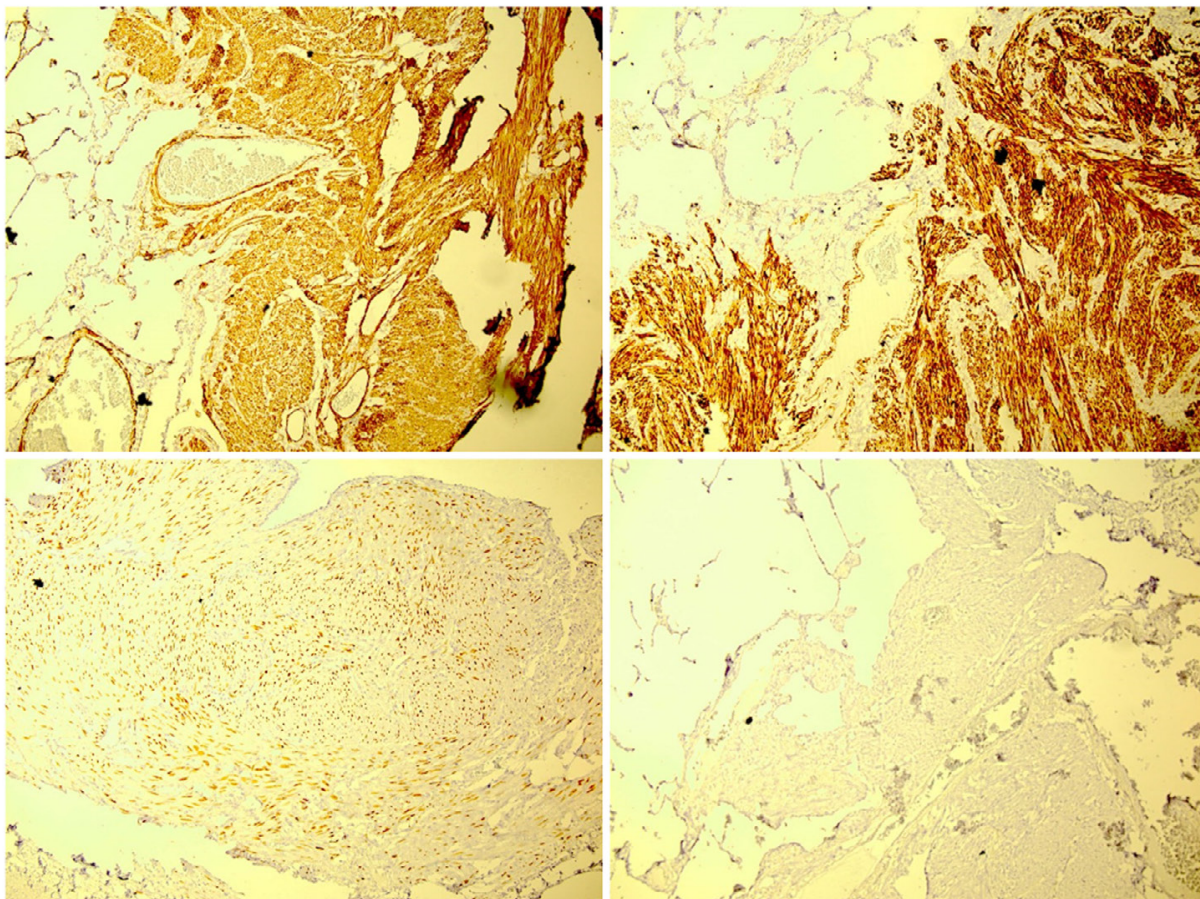


Fig. 1. CT scan shows multiple round nodules with well-defined margins in bilateral lung.



**Fig. 2.** Histopathologic examination revealed neoplastic tissue consisted of well differentiated spindle shaped cells with no nuclear atypia; there were no mitotic figures and necrosis (left: x100 and right: x400)



**Fig. 3.** Immunohistochemical examination revealed benign metastasizing leiomyoma (BML) with positive staining for smooth muscle makers comprising smooth muscle actin (left upper), desmin (right upper). Strong expression of estrogen receptor in tumor cells (left lower), and HMB-45 staining was negative (right lower).

## Discussion

Leiomyoma of uterine is the most common benign gynecological tumors. But, 0.13 to 6% of them show malignant potential. Smooth muscle tumors of uterine with unusual progress patterns comprise a variety of lesions including intravenous leiomyomatosis, benign metastasizing leiomyoma and disseminated peritoneal leiomyomatosis [5]. BML is initially used to describe the distinct or multiple pulmonary nodules consist of smooth muscle cells proliferation with no nuclear atypia in women. The lung is the most commonly complicated location, therefore; comprising numerous malignant and benign objects in the differential diagnosis [6]. BML was presented by Steiner in 1939. It implies to a category of lesion described by well defined, solitary or, often, multiple nodules of smooth muscle cells proliferation in the lungs of women with a past medical history of leiomyoma of uterine [7]. While, about 100 cases have been informed in the literature, the prevalence, pathogenesis and treatment persist uncertain. Because of low morbidity and absence of information regarding this situation, there is no agreement on which approaches must be used to treat this disease [8]. BML of the lung is slightly hard to diagnose by routine imaging or physical analysis and is frequently misdiagnosed for example pneumonia, bronchitis, phthisic or metastasizing lung cancer. Open lung biopsy (OLB) is the standard diagnostic method for BML [9]. We had to done this procedure for diagnosis of our patient. Establishing the diagnosis of BML is actual difficult. It is according to the combination of the findings of chest imaging, immunohistochemical staining, and medical history of leiomyoma of uterine. Lack of hypercellularity, nuclear cellular atypia, coagulative tumor cell necrosis, and increased mitosis (> 5 per 10 high-powered fields) with a low proliferative state and benign nature of these tumors [10] is similar to our case. Abramson et al. described that the median age of patients with BML is 48 years old but our case was younger than this report. Horstmann et al. informed that the radiological appearance of benign metastasizing leiomyoma of the lung is multiple nodules in 87% of the cases (70% bilateral nodules and 17% unilateral nodules) or by way of a solitary nodule in 13% of the cases [11] which our case had multiple nodules. Besides, Tsunoda et al. described a patient of benign metastasizing leiomyoma of the lung who complicated with primary lung cancer [12]. A standard management for BML has not been recognized up till now. For the hormone sensitive features of BML, treatments are constructed on hormonal use alongside with any surgical or medical oophorectomy [3]. In addition, standard method

residues to be not recognized for the treatment of this disease, but the clinical progression of BML differs between cases and a specific treatment approach should be considered. Thoracic surgeons must be conscious of this uncommon reason of multiple pulmonary nodules.

In summary, even though chest CT-scan discoveries of BML are like to malignancies, the clinical outcome is good. Regardless of ER with strong positive expression, the efficacy of hormone-related usage is restricted. Therefore, a close follow-up is recommended even to those uneventful patients.

## Acknowledgment

None.

## Ethical Considerations

### Compliance with ethical guidelines

There were no ethical considerations to be considered in this research.

### Funding

This research did not receive any grant from funding agencies in the public, commercial, or non-profit sectors.

### Authors' contributions

All authors equally contributed in preparing this article.

### Conflict of interest

Authors declare that there is no conflict of interest.

## References

- [1] Awonuga AO, Shavell VI, Imudia AN, Rotas M, Diamond MP, Puscheck EE. Pathogenesis of benign metastasizing leiomyoma: a review. *Obstetrical & gynecological survey*. 2010;65(3):189-95. <https://doi.org/10.1097/OGX.0b013e3181d60f93>
- [2] Nucci MR, Drapkin R, Dal Cin P, Fletcher CD, Fletcher JA. Distinctive cytogenetic profile in benign metastasizing leiomyoma: pathogenetic implications. *The American journal of surgical pathology*. 2007;31(5):737-43. <https://doi.org/10.1097/01.pas.0000213414.15633.4e>
- [3] Ki EY, Hwang SJ, Lee KH, Park JS, Hur SY. Benign metastasizing leiomyoma of the lung. *World Journal of Surgical Oncology*. 2013;11(1):1-7. <https://doi.org/10.1186/1477-7819-11-279>

- [4] Fan D, Yi X. Pulmonary benign metastasizing leiomyoma: a case report. *International journal of clinical and experimental pathology*. 2014;7(10):7072-75. PMID: 25400799
- [5] Saadeh FA, Riain CO, Mc Cormack C, Gleeson N. Lung metastases from benign uterine leiomyoma: does 18-FDG-PET/CT have a role to play? *Irish Journal of Medical Science* (1971). 2019;188(2):619-24. <https://doi.org/10.1007/s11845-018-1876-0>
- [6] Loukeri AA, Pantazopoulos IN, Tringidou R, Giampoudakis P, Valaskatzi A, Loukeri PA, et al. Benign metastasizing leiomyoma presenting as cavitating lung nodules. *Respiratory care*. 2014;59(7):e94-e7. <https://doi.org/10.4187/respcare.02775>
- [7] Kayser K, Zink S, Schneider T, Dienemann H, André S, Kaltner H, et al. Benign metastasizing leiomyoma of the uterus: documentation of clinical, immunohistochemical and lectin-histochemical data of ten cases. *Virchows Archiv*. 2000;437(3):284-92. <https://doi.org/10.1007/s004280000207>
- [8] Wei WT, Chen PC. Benign metastasizing leiomyoma of the lung: A case report and literature review. *Oncology letters*. 2015;10(1):307-12. <https://doi.org/10.3892/ol.2015.3224>
- [9] Chen S, Liu R-M, Li T. Pulmonary benign metastasizing leiomyoma: a case report and literature review. *Journal of thoracic disease*. 2014;6(6):E92.
- [10] Rege AS, Snyder JA, Scott WJ. Benign metastasizing leiomyoma: a rare cause of multiple pulmonary nodules. *The Annals of thoracic surgery*. 2012;93(6):e149-e51. <https://doi.org/10.1016/j.athoracsur.2011.12.047>
- [11] Fu Y, Li H, Tian B, Hu B. Pulmonary benign metastasizing leiomyoma: a case report and review of the literature. *World journal of surgical oncology*. 2012;10(1):1-4. <https://doi.org/10.1186/1477-7819-10-268>
- [12] Tsunoda Y, Tanaka K, Hagiwara M. A case of benign metastasizing leiomyoma of the lung complicated with primary lung cancer. *Jpn J Lung Cancer*. 2009;49:445-9. <https://doi.org/10.2482/haigan.49.445>