



## Cardiac Tamponade in a Neglected Case of Thyroid Agenesis

Zeinab Naderpour<sup>1</sup>, Elnaz Vahidi<sup>2</sup>, Mahbubeh Ebrahimpur<sup>1</sup>

1- Department of Internal Medicine, Shariati Hospital, Tehran University of Medical Sciences, Tehran, Iran

2- Department of Emergency Medicine, Shariati Hospital, Tehran University of Medical Sciences, Tehran, Iran

Received: 24 October 2016

Revised: 22 November 2016

Accepted: 19 December 2016

### ARTICLE INFO

Corresponding author:  
Zeinab Naderpour

Email:  
[z\\_naderpour@yahoo.com](mailto:z_naderpour@yahoo.com)

Keywords:  
Cardiac tamponade;  
Hypothyroidism;  
Thyroid agenesis

### ABSTRACT

Mild pericardial effusion is common in severe form of hypothyroidism, but massive pericardial effusion with or without cardiac tamponade is rare. A 49-year-old man with short stature, large head, and facial puffiness was brought to the emergency department because of progressive altered mental status and severe dyspnea. Cardiac tamponade and hypothyroidism were diagnosed in work ups. Lack of thyroid tissue in his imagines, confirmed the diagnosis of thyroid agenesis. With pericardiocentesis, hydration, and starting levothyroxine, his clinical symptoms were resolved dramatically. Our case was presented with full-blown clinical manifestations and irreversible consequences of congenital hypothyroidism. This shows us the important role of newborn screening tests.

**Citation:** Naderpour Z, Vahidi E, Ebrahimpur M. **Cardiac Tamponade in a Neglected Case of Thyroid Agenesis.** Case Rep Clin Pract 2016; 1(4): 106-9.

### Introduction

Congenital hypothyroidism, occurring in approximately 1:2000 to 1:4000 newborns, is the most common preventable cause of mental retardation and delay in physical growth. Geographic location and ethnicity have a great impact on its prevalence. The incidence of congenital hypothyroidism has risen over the last few decades, mainly because of changes in newborn screening strategies, shifting demographics, and increase in survival of

preterm infants at high risk of congenital hypothyroidism (1, 2).

In the past, children born with congenital hypothyroidism, often suffer serious morbidities because of late diagnosis. With the introduction of newborn screening programs in the 1970s, the attitude towards these children has changed dramatically. By means of early diagnosis and treatment, even in severely affected cases, patients can be expected to have normal intelligence and growth and gain healthiness like others

without hypothyroidism (3, 4).

Severe hypothyroidism is rare cause of massive pericardial effusion or tamponade. Cardiac tamponade is life-threatening condition characterized by compression of heart due to accumulation of pericardial fluid. Malignancy, uremia, tuberculosis, acute idiopathic pericarditis, post-acute myocardial infarction, and collagen vascular diseases are more common causes of cardiac tamponade (5).

In this case report, we present a 49-year-old man with cardiac tamponade. His clinical and laboratory findings were in favor of hypothyroidism. Finally, based on the clinical appearance and lack of thyroid tissue in his imaging, thyroid agenesis was diagnosed.

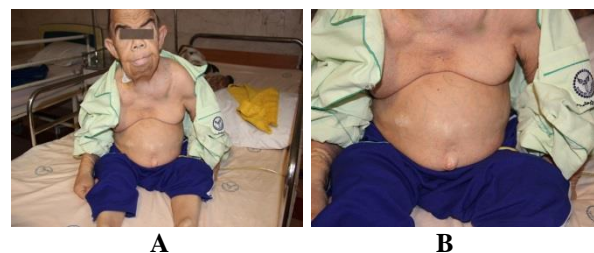### Case Report

A 49-year-old male was brought to the emergency department with progressive altered mental status, severe dyspnea, and decreased urine output since four days before his admission. He had a history of urinary retention which was diagnosed as benign prostate hyperplasia and treated with intermittent urinary catheterization. He had no complaint of fever, chest pain, previous seizure, or headache. On physical examination, he had engorged jugular vein. Lungs were clear bilaterally. Heart sounds were muffled. There was no neck stiffness. His tendon reflexes showed delayed relaxation. His vital signs were as:

Blood pressure: 70/pulse mmHg; Heart Rate: 50-60 beats/minute; Respiratory rate: 11 /minute; Temperature: 36.5 °C

In physical examination, we found that he had a short stature with large head, short neck, facial puffiness, coarse hair, dry and cold skin, pallor, macroglossia, and non-pitting edema (Figure 1).

On admission, he was intubated and underwent invasive ventilation because of low O<sub>2</sub> saturation, poor respiratory effort, and loss of consciousness. Nasogastric (NG) tube, Foley catheter, and central venous access were fixed for him.



**Figure 1.** A. Short stature and facial features of the patient; B. Umbilical hernia of his abdomen

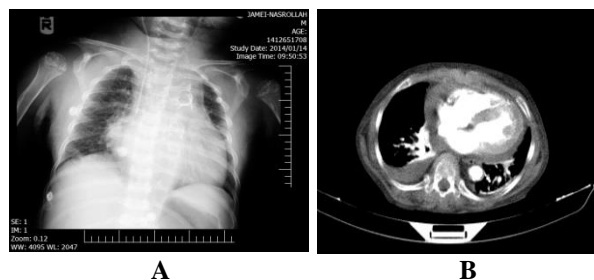
The electrocardiogram showed sinus bradycardia with low voltage complexes, and no electrical alternance was observed. Chest X-ray showed enlarged cardiac silhouette and echocardiogram revealed massive pericardial effusion with right atrial collapse; and an ejection fraction (EF) of about 40-45 percent was detected. Therefore, cardiac tamponade was confirmed and patient underwent urgent closed pericardiocentesis with drainage of 400 cc of serous fluid. Fluid cultures were negative, and cytology analysis was negative for malignant cells. Pericardiocentesis and hydration dramatically improved his urine output and hemodynamics.

So based on the aforementioned findings, our initial diagnosis was hypothyroidism. Thyroid function test results were as:

Thyroid-stimulating hormone (TSH): 154 MIU/ml (range: 0.4 - 6 MIU/ml); T<sub>4</sub> < 2 µg/dl (range: 5.4-12.6 µg/dl); T<sub>3</sub> < 50 ng/dl (range: 52-158 ng/dl).

Thus, the diagnosis of primary hypothyroidism was confirmed.

In neck ultrasonography and chest computed tomography (CT) scan, no thyroid tissue was detected; so, the diagnosis of congenital hypothyroidism was made (Figure 2).



**Figure 2.** Chest imaging of the patient. A. Chest X-ray; B. Chest computed tomography (CT) scan

After doing all critical cares in the emergency ward, his condition gained stability gradually. No pericardial effusion was detected in follow-up echocardiography. He received treatment of hypothyroidism (levothyroxine 50 µg, then titrated to 100 µg). After starting this treatment, no further similar attacks occurred and several clinical symptoms and signs were alleviated. After 8 months, pericardial effusion completely absorbed.

## Discussion

Normal levels of thyroid hormones are necessary for optimal physical growth and development throughout childhood. It is also necessary for normal brain growth in the first two years of life as well as brain function throughout life (3).

Tiredness, weakness, dry hair, constipation, weight gain with poor appetite, and cold intolerance are common symptoms in hypothyroidism and dry coarse skin, cold peripheral extremities, puffy face, non-pitting edema, and bradycardia are typical features (6). Pericardial effusion occurs in up to 30% of patients, but massive effusions with compromised cardiac function are seen only in 1 to 3% of cases (7, 8).

We presented a neglected case of hypothyroidism with full-blown clinical manifestation which left untreated until 40s. In the literature, untreated congenital hypothyroidism cases who were alive until 50 years/old, were rarely reported. Many cases of neglected congenital hypothyroidism were diagnosed during work ups for developmental delay, short stature, low intelligence quotient (IQ), and delayed puberty (9). Our patient encountered irreversible complications in the late 40s. Recognizing congenital hypothyroidism in early stages is difficult; because clinical manifestations are usually subtle. Therefore, screening tests for hypothyroidism in newborns are included in health care service programs in many countries like Iran (10).

Routine screening tests for hypothyroidism

in newborns lead to early diagnosis and treatment; therefore, nowadays finding cardiac tamponade in association with congenital hypothyroidism is so rare. Although other cardiovascular manifestations of hypothyroidism such as dyspnea and decreased exercise tolerance, bradycardia, diastolic hypertension, peripheral edema, and mild pericardial effusion are common, massive pericardial effusion with or without tamponade is rare and associated with severe forms of disease (7, 8). It is important to remember that cardiac tamponade is almost always associated with sinus tachycardia but hypothyroidism is an exception and can be associated with bradycardia (11).

In conclusion, unrecognized hypothyroidism should be considered in cases of cardiac tamponade with bradycardia especially among patients with other clinical manifestations of hypothyroidism.

## Conflict of Interests

Authors have no conflict of interests.

## Acknowledgments

None.

## References

1. Wassner AJ, Brown RS. Congenital hypothyroidism: Recent advances. *Curr Opin Endocrinol Diabetes Obes* 2015; 22(5): 407-12.
2. Mitrovic K, Vukovic R, Milenkovic T, Todorovic S, Radivojcevic J, Zdravkovic D. Changes in the incidence and etiology of congenital hypothyroidism detected during 30 years of a screening program in central Serbia. *Eur J Pediatr* 2016; 175(2): 253-9.
3. Australasian Paediatric Endocrine Group. Congenital hypothyroidism: A guide for parents [Online]. [cited 2006]; Available from: URL: <http://globalpedendo.org/escan/article/congenital-hypothyroidism-a-guide-for-parents>
4. Wassner AJ, Brown RS. Subclinical hypothyroidism in infancy: To treat or not to treat, that is the question. *J Pediatr* 2016; 170: 17-9.
5. Patil VC, Patil HV, Agrawal V, Patil S. Cardiac tamponade in a patient with primary

- hypothyroidism. *Indian J Endocrinol Metab* 2011; 15(Suppl 2): S144-S146.
6. McDermott MT. In the clinic. Hypothyroidism. *Ann Intern Med* 2009; 151(11): ITC61.
  7. Ekka M, Ali I, Aggarwal P, Jamshed N. Cardiac tamponade as initial presenting feature of primary hypothyroidism in the ED. *Am J Emerg Med* 2014; 32(6): 683.
  8. Purkait R, Prasad A, Bhadra R, Basu A. Massive pericardial effusion as the only manifestation of primary hypothyroidism. *J Cardiovasc Dis Res* 2013; 4(4): 248-50.
  9. Mahmoud MM. Neglected case of congenital hypothyroidism in a 17-year-old female. *Int J Case Rep Imag* 2013; 4(9): 481-4.
  10. Veisani Y, Sayehmiri K, Rezaeian S, Delpisheh A. Congenital hypothyroidism screening program in iran; a systematic review and metaanalysis. *Iran J Pediatr* 2014; 24(6): 665-72.
  11. Bajaj R, Mehrzad R, Singh K, Gupta JP. Cardiac tamponade in hypothyroidism. *BMJ Case Rep* 2014; 2014.