

Respiratory Distress Due to Giant Pulmonary Hydatid Cyst

Reza Ershadi 

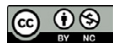Department of Thoracic Surgery, Valiasr Hospital, Tehran University of Medical Sciences, Tehran, Iran.

Use your device to scan and read the article online



Citation Ershadi R. Respiratory Distress Due to Giant Pulmonary Hydatid Cyst. Case Reports in Clinical Practice. 2022; 7(2): 91-96.

Running Title Giant Pulmonary Hydatid Cyst

**Article info:****Received:** 04 April 2022**Revised:** 18 April 2022**Accepted:** 21 May 2022**Keywords:**

Lung; Hydatid cyst; Children

ABSTRACT

Pulmonary echinococcosis most frequently occurs in the right and both lower lobes. Children are more likely to develop pulmonary rather than hepatic echinococcal cysts. Some evidence suggests that echinococcal cysts develop more rapidly in the lungs of children than those of adults, which may explain the more common appearance of pulmonary cysts in children. Younger patients have larger cysts owing to their greater tissue elasticity. Large pulmonary hydatid cysts are critical because they pose a higher risk of rupture. Herein, we present an eight-year-old girl presented with severe respiratory distress due to giant hydatid cyst of right lung with shift of the mediastinum at left. The lesion displaced the trachea at left. The patient was successfully treated by parenchymal-saving operation. In conclusion, Giant hydatid lung cysts represent a distinct clinical entity most frequently encountered in children and adolescents with more serious symptoms. Although non-complicated giant hydatid cysts have a good prognosis regardless of their size and can be safely treated by parenchyma-preserving surgery.

Introduction

H ydatid cyst is caused by infection with the *Echinococcus granulosus* tapeworm. Humans are incidental hosts of *Echinococcus*. The definitive hosts are dogs and other canines, while the intermediate hosts are most commonly sheep and occasionally other livestock. Human infection occurs mainly from contact with infected

dogs or from ingesting fresh products contaminated with parasite eggs [1, 2]. The liver is most commonly infected with hydatid disease followed by the lung. Pulmonary echinococcosis most frequently occurs in the right and both lower lobes [3]. Children are more likely to develop pulmonary rather than hepatic echinococcal cysts. Some evidence suggests that echinococcal cysts develop more rapidly in the lungs of children than those of adults, which may explain the more common appearance of pulmonary cysts

*** Corresponding Author:****Reza Ershadi****Address:** Department of Thoracic Surgery, Valiasr Hospital, Bagherkhan Street, Tehran, Iran**E-mail:** ershadyr@yahoo.com

in children. Younger patients have larger cysts owing to their greater tissue elasticity. Large pulmonary hydatid cysts are critical because they pose a higher risk of rupture. Sometimes, the entire hemithorax of a young child is occupied by parasitic cysts [4] as in my case. Lung hydatid cysts measuring more than 10 cm in the largest diameter, are defined as giants [5]. In this study, we present a case of giant pulmonary hydatid cyst with severe respiratory distress.

Patient

An eight-year-old girl presented with severe respiratory distress. The patient had 7-month history of gradual and progressive dyspnea and dry cough.

On admission, her vital signs were temperature 36.2C, heart rate 143 beats per minute, blood pressure 114/68 mm Hg, and oxygen saturation 90% in room air. On physical examination there were no breath sounds over the right lung. . Chest X-ray (Fig. 1) and CT (Fig. 2) revealed a giant cystic lesion occupying the entire right hemithorax with shift of the mediastinum at left. The lesion displaced the trachea at left. Abdominal ultrasonography has not revealed cysts. The ELISA test for echinococcosis was positive. It should be noted that these documents were accompanied by the patient. The patient was taken urgently to the operating room. Intraoperatively, a very large cyst of 18 cm of diameter of the lower lobe was found. The cyst compresses the middle and the upper lobe of the right lung.

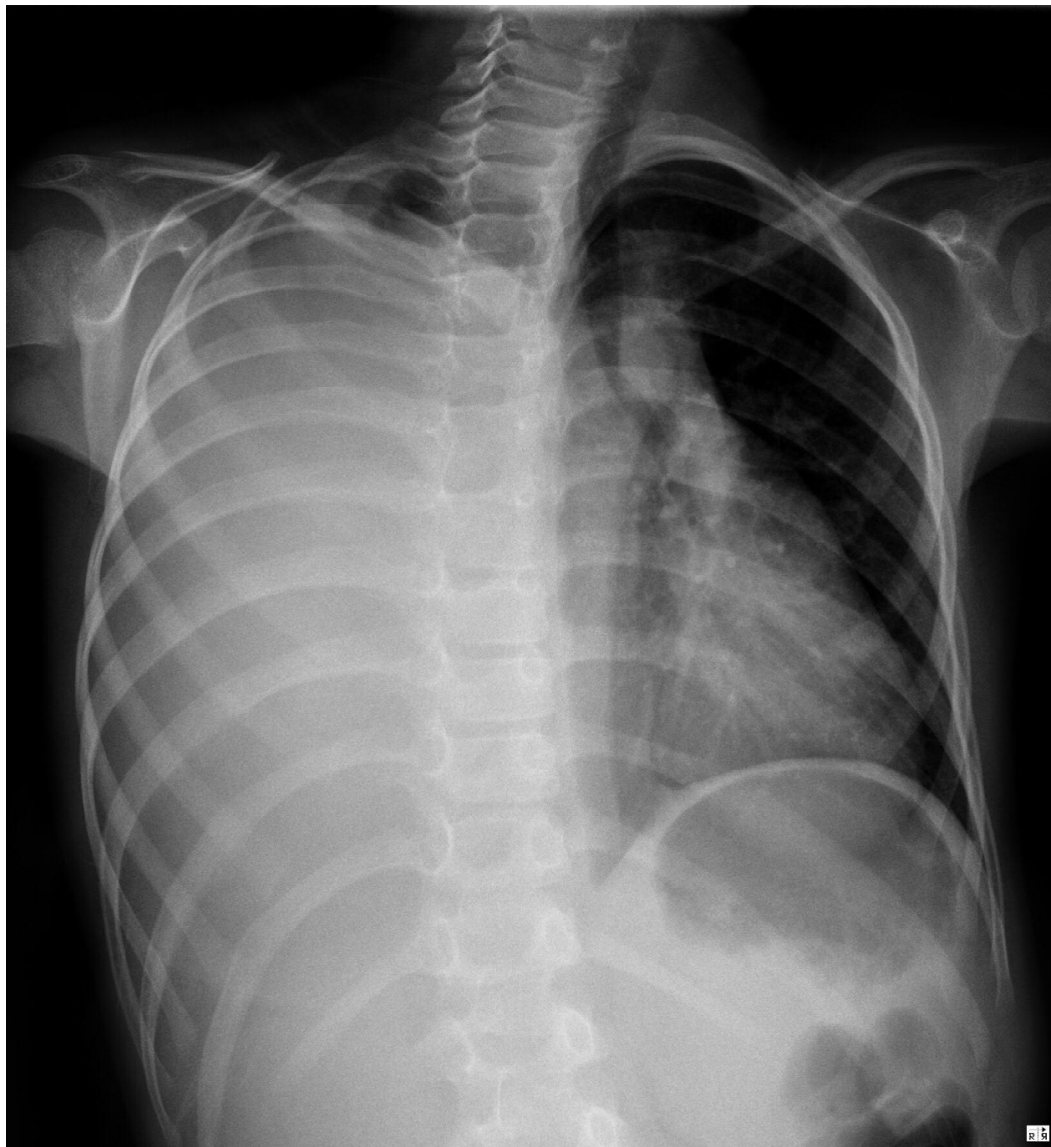
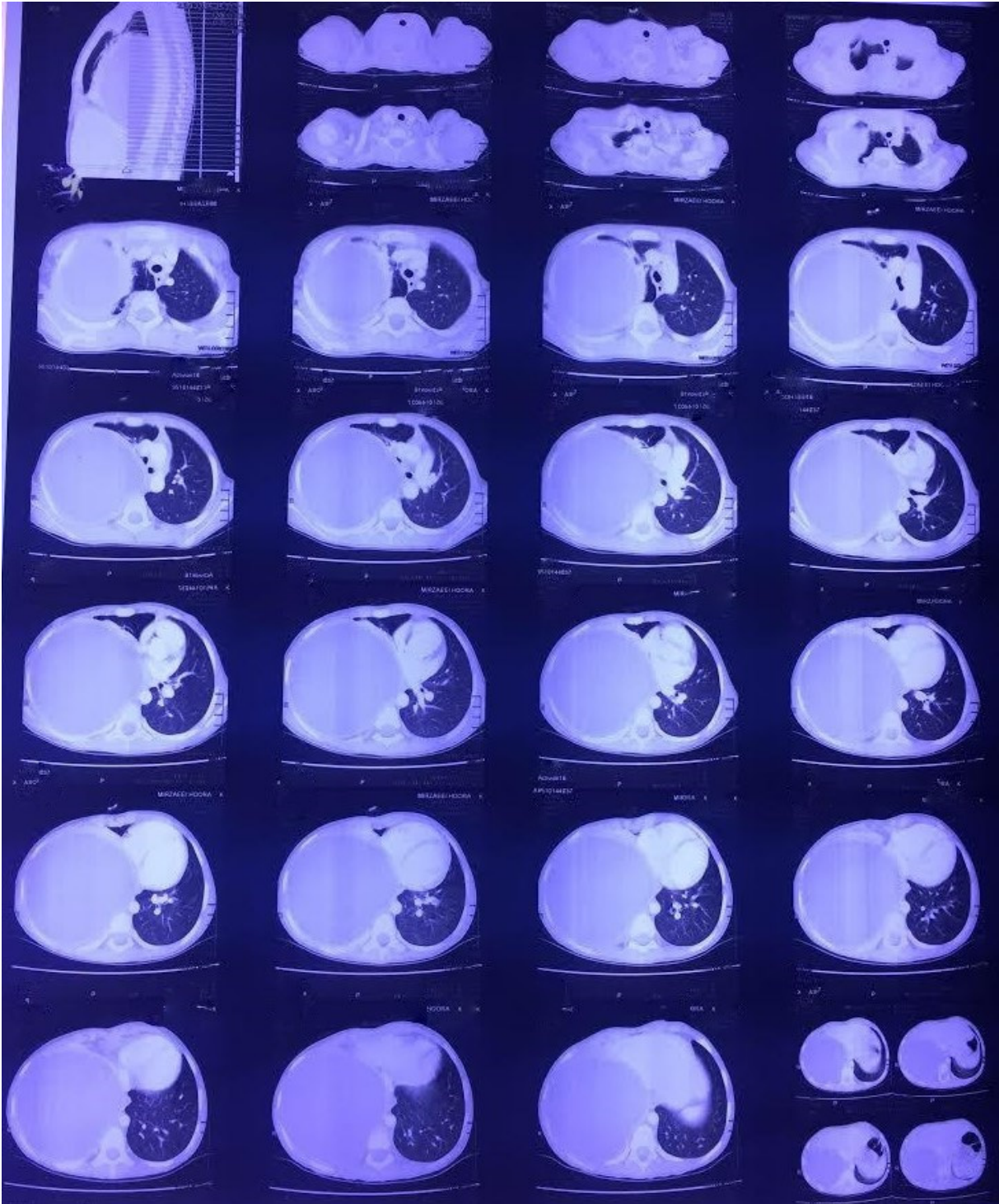
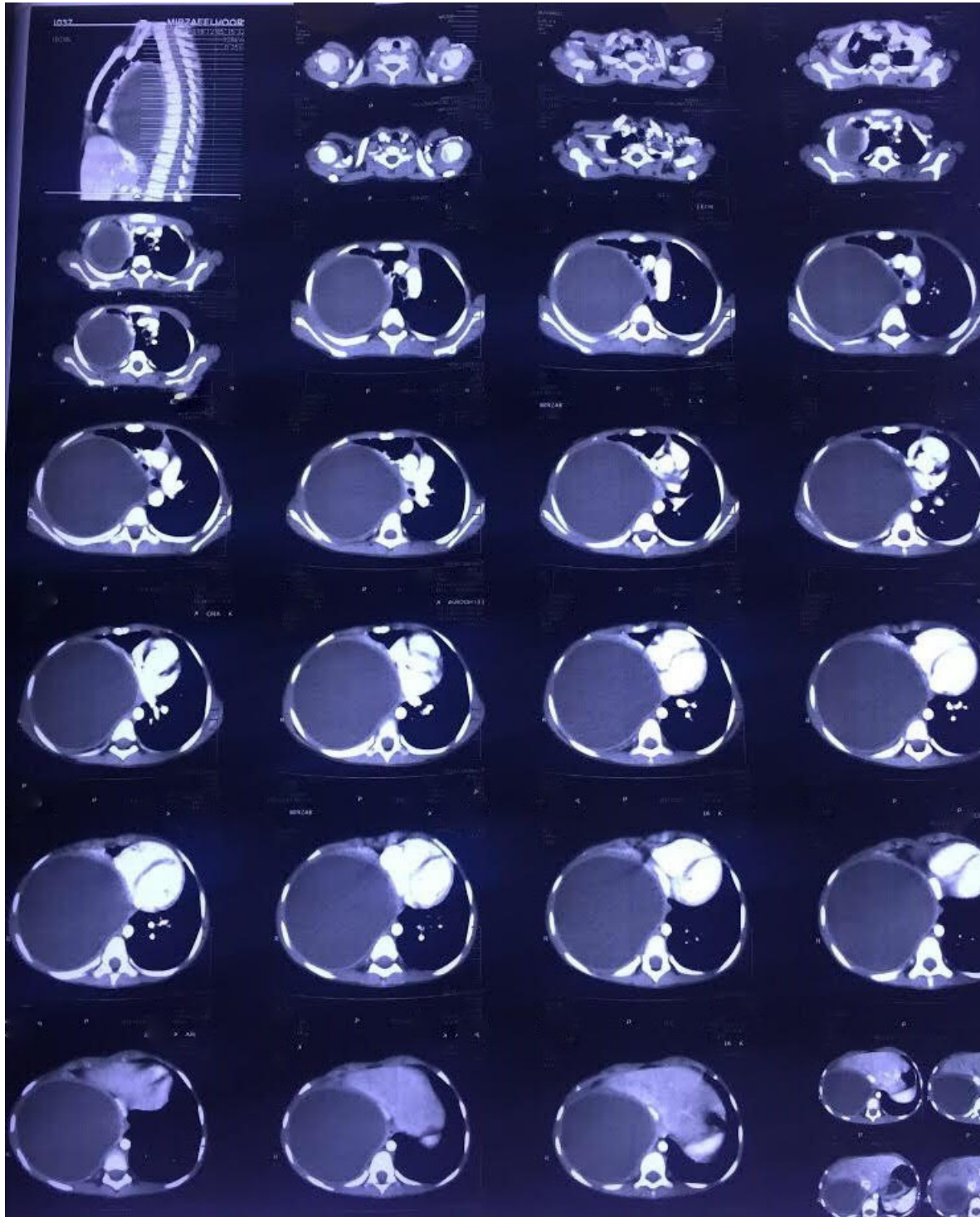


Fig. 1. Chest X-ray showed a high-density shadow involving the total of right hemithorax with shift of the trachea.



A.

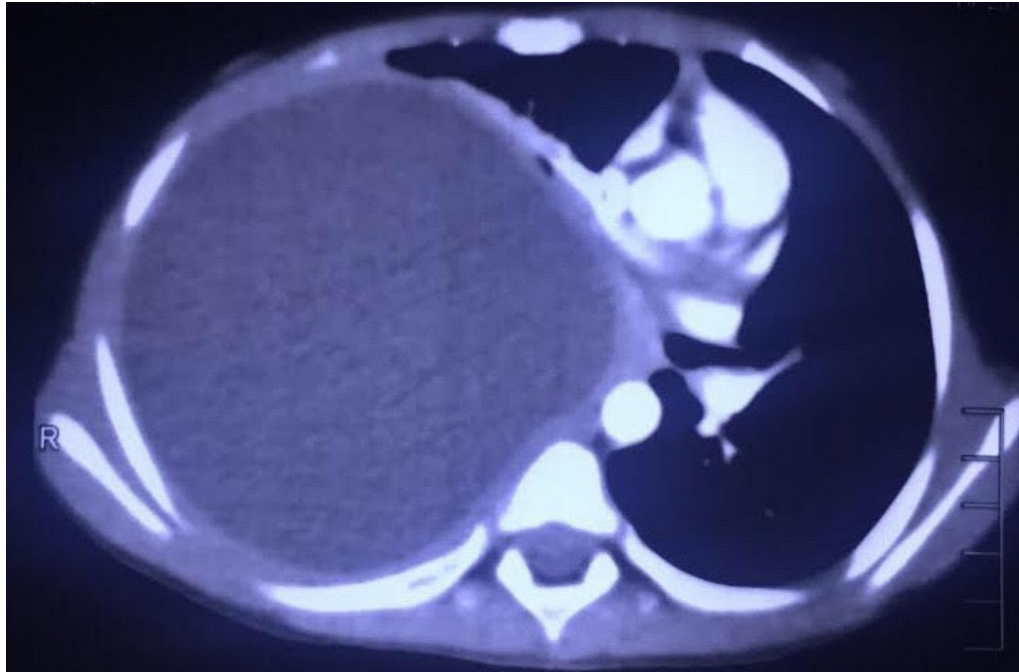
Fig. 2 (A-B-C). Chest CT revealed that right hemithorax was occupied with a giant tension cystic lesion with shifted the mediastinum to the left side.



B.



Continued Fig. 2 (A-B-C). Chest CT revealed that right hemithorax was occupied with a giant tension cystic lesion with shifted the mediastinum to the left side.



C.



Continued Fig. 2 (A-B-C). Chest CT revealed that right hemithorax was occupied with a giant tension cystic lesion with shifted the mediastinum to the left side.

The operative field and pleura were covered with wet sponges diluted with hypertonic saline serum to prevent seeding of possible daughter cysts. As the lung was kept inflated, a large needle connected to the suction tip was inserted into the cyst. When the cyst was aspirated and its fluid evacuated as completely as possible, the most prominent part of the cyst was opened (cystotomy) and the cyst membrane was removed with ring forceps. Then the cavity was cleaned with sponges moistened with hypertonic saline and the bronchial openings were sutured. Then cystic cavity was capitonnaged. Thoracotomy was closed after insertion of a chest tubes. The patient made a full and uneventful recovery from the procedure and was discharged from the hospital 6 days after surgery. Six months later, chest X-Ray showed a well expanded right lung.

Discussion

Hydatidosis is a parasitic disease caused by the larval growth of the tapeworm *Echinococcus granulosus*. The dog-sheep cycle is the paradigm for the life cycle of the parasite. Human becomes involved in this cycle when he/she is associated with infected dogs or by consuming contaminated vegetables [6]. The liver is the most common and the lung is the second most common area affected in adults. However, children are more likely to have pulmonary than hepatic echinococcus cysts [7]. Pulmonary hydatid

cysts can be located in any pulmonary lobe. The right lower lobe is the most frequently affected area of the lung [6]. The cysts grow more rapidly in the lungs than in other organs, mainly because of the negative pressure and the great elasticity of the pulmonary tissue. In the course of their natural evolution, many cysts gradually cease growing and degenerate. During the growth period of the cyst, it may rupture spontaneously or during coughing, sneezing, or any other cause of increased intrathoracic pressure, or after injury during diagnostic thoracentesis. Large cysts are especially vulnerable to rupture because of the increased pressure exerted by the fluid. The rupture may occur within the boundaries of the pericystic layer, into the pleural space, or into a neighbouring organ, bronchus or blood vessel [8]. Giant hydatid cysts of the lung constitute a distinct clinical entity most frequently encountered in adolescents and in children older than ten years [7]. This predominance is explained by the fact that the immune system and the relatively higher elasticity of the lung tissue in children and adolescents allow the rapid growth of cysts. The rate of growth is much higher in children and the ranges from a few millimetres to 5 cm per year (9). The clinical presentation of hydatid cysts of the lung depends on whether the cysts are intact or ruptured. Intact or simple cysts of the lung produce no characteristic symptoms. Their clinical manifestations depend on

their site and size. Small and peripherally located cysts may manifest with symptoms of compression of adjacent organs. If the patient is symptomatic, the first complaint is often a nonproductive cough; some patients, particularly those with centrally located cysts, may have blood-streaked sputum, although massive hemoptysis does not occur. Some patients complain of a dull or acute chest pain or present with a sensation of pressure in the chest with no aggravating or relieving features. During infancy, the hydatid cyst may disturb growth. In children who have a supple chest wall, a bulge in the ipsilateral chest may also be observed [8]. The lung hydatid disease is frequently asymptomatic in children. Nevertheless, giant lung hydatid cysts were constantly symptomatic [5] as in my case with respiratory distress. Diagnosis of an intact echinococcal cyst is usually based on a suspicion resulting from an unexpected finding on routine chest radiographs. Radiographically, the cyst appears as a homogeneous spherical opacity with definite edges. Computed tomography (CT), has added to the diagnosis of hydatid disease of the lung, particularly to the early discovery of coexistent small cysts in the lung and of pending or existing rupture of the cyst. CT scanning with contrast may demonstrate a thin enhancing rim if the cyst is intact. The contents of these cysts are homogeneous, with a density similar to that of water. Magnetic resonance imaging may show detached membranes, local host reactions, or communications between the cyst and the bronchial tree in the case of ruptured cysts. It may also show regression of the cyst during chemotherapy with albendazole, which destroys the germinal layer and accelerates the degeneration of the parasite or increases the local host reaction [10]. The optional treatment for pulmonary hydatid cysts is operation. Various surgical procedures have been described in the literature, namely, excision of entire cyst by enucleation (Barrett technique), excision of pericyst (Perez Fontana), cystotomy, capitonnage, wedge resection, segmentectomy and lobectomy [6]. Parenchyme-saving operations can also be more suitable for the patients with giant cysts [11]. Resection of the lung must be avoided for two reasons: the first reason is the compressed lung parenchyma which is generally healthy and should be expanded post operatively, and the second one is the possibility of recurrence of hydatid cysts [7].

Conclusion

Giant hydatid lung cysts is a frequent clinical entity in children with more serious symptoms. Although non-complicated giant hydatid cysts have a good prognosis regardless of their size, they can be safely treated by parenchyma-preserving surgery.

Ethical Considerations

Compliance with ethical guidelines

There were no ethical considerations to be considered in this research.

Funding

This research did not receive any grant from funding agencies in the public, commercial, or non-profit sectors.

Conflict of interest

Authors declare that there is no conflict of interest.

References

- [1] Santivanez S, Garcia HH. Pulmonary cystic echinococcosis. *Curr Opin Pulm Med.* 2010;16(3):257–261. doi:10.1097/MCP.0b013e3283386282
- [2] Arinc S, Kosif A, Ertugrul M, et al. Evaluation of pulmonary hydatid cyst cases. *Int J Surg.* 2009;7(3):192–195. doi:10.1016/j.ijso.2008.11.003
- [3] Aletras HA. Hydatid cyst of the lung. *Scand J Thorac Cardiovasc Surg* 1968;2:918. <https://doi.org/10.3109/14017436809131909>
- [4] Balci AE, et al. Ruptured hydatid cysts of the lung in children: clinical review and results of surgery. *Ann Thorac Surg* 2002;74:889. [https://doi.org/10.1016/S0003-4975\(02\)03785-2](https://doi.org/10.1016/S0003-4975(02)03785-2)
- [5] N. Karaoglanoglu, I.C. Kurkcuoglu, M. Gorguner, A. Eroglu, A. Turkyilmaz Giant hydatid lung cysts *Eur J Cardiothorac Surg*, 19 (2001), pp. 914-917. [https://doi.org/10.1016/S1010-7940\(01\)00687-X](https://doi.org/10.1016/S1010-7940(01)00687-X)
- [6] Aytaç A, Yurdakul Y, İkizler C, Olga R, Saylam A. Pulmonary hydatid disease: report of 100 patients. *Ann Thorac Surg* 1977;23:145-51. [https://doi.org/10.1016/S0003-4975\(10\)64088-X](https://doi.org/10.1016/S0003-4975(10)64088-X)
- [7] Haliloğlu M, Saatçi I, Akhan O, Özmen M, Besim A. Spectrum of imaging findings in pediatric hydatid disease. *AJR Am J Roentgenol* 1997;169:1627-31. <https://doi.org/10.2214/ajr.169.6.9393178>
- [8] Ramos G, Orduña A, Garcia-Yuste MG. Hydatid cyst of the lung: diagnosis and treatment. *World J Surg* 2001;25:46.
- [9] N. Symbas, H. Aletras Hydatid disease of the lung T.W. Shieds, J. Lociero, R.B. Ponn (Eds.), *General thoracic surgery*, Lippincott, Williams and Wilkins, Philadelphia (2000), pp. 1113-1122. <https://doi.org/10.1007/s002680020007>
- [10] Saksouk FA, Fahl MH, Rizk GH. Computed tomography of pulmonary hydatid disease. *J Comput Assist Tomogr* 1986; 10:226. <https://doi.org/10.1097/00004728-198603000-00011>
- [11] M. Celik, C. Senol, M. Keles, et al. Surgical treatment of pulmonary hydatid disease in children: report of 122 cases *J Pediatr Surg*, 35 (2000), pp. 1710-1713. <https://doi.org/10.1053/jpsu.2000.19219>