

Starry Sky on MRI Brain: Unusually Observed in a Pediatric Case of Japanese Encephalitis



Durgesh Kumar¹, Dinesh Kumar¹, Rajesh Kumar Yadav²

1. Department of Pediatrics, Uttar Pradesh University of Medical Sciences, Saifai, Etawah, India.

2. Department Department of Pediatrics, Uttar Pradesh University of Medical Sciences, Saifai, Etawah, India.

Use your device to scan and read the article online



Citation Kumar D, Kumar D, Kumar Yadav R. Starry Sky on MRI Brain: Unusually Observed in a Pediatric Case of Japanese Encephalitis. Case Reports in Clinical Practice. 2022; 7(3): 163-166.

Running Title Starry Sky Appearance in Japanese Encephalitis



Article info:

Received: 02 April 2022

Revised: 24 April 2022

Accepted: 03 May 2022

Keywords:

Japanese encephalitis;
 Starry sky; Pediatric; Acute encephalitis syndrome

ABSTRACT

A 13-year-old girl presented with fever, nausea and projectile vomiting and altered sensorium. On physical examination, the meningeal signs were presented without focal neurological deficits and Grade II papilledema was presented on fundus examination. The patient was found to be positive for Japanese encephalitis virus in cerebrospinal fluid. Focal neurological deficit in the form of right hemiparesis was noticed at day 6 of hospitalisation. Multiple lesions with minimal enhancement with perilesional edema were observed in cerebral cortex in contrast with enhanced magnetic resonance imaging of the brain, giving rise to starry sky appearance. No tests for neurotuberculosis were found positive. Serum IgG enzyme-linked immunosorbent assay test was negative for Cysticercosis, but magnetic resonance spectroscopy was suggestive of cysticercal meningitis. During treatment, she had intermittent episodes of nausea and vomiting with waxing and waning sensorium. Subsequently, it was planned to start Albendazole after steroids coverage and anticonvulsants but the patient did not improve and succumbed to her illness.

Introduction

Japanese encephalitis (JE) is an endemic flaviviral encephalitis that is spread through Culex mosquito bite and is one of the important health problem in Southeast Asia including India. Most of the infected patients get admitted with fever and flu-like symptoms, nausea and vomiting, neck rigidity, altered sensorium and/or convulsions with or

without hemiparesis. The disease mostly affects the children under 15 years of age [1]. The neuroimaging in JE can reveal lesions in substantia nigra, thalamus, basal ganglia, brain stem, cerebellum and cerebral cortex, but starry sky pattern on magnetic resonance imaging (MRI) is very unlikely [1, 2]. The co-existing infection of JE along with acute cysticercal meningitis with starry sky appearance on neuroimaging is rare. When neurocysticercosis (NCC) is presented with JE, it might be misinterpreted and may cause delay

* Corresponding Author:

Dr Durgesh Kumar

Address: Department of Pediatrics, Uttar Pradesh University of Medical Sciences, Saifai, Etawah, India.

E-mail: drdurgeshk@gmail.com

in diagnosis. In this study, we report a case of JE encountered recently whose MRI brain reveals starry sky pattern.

Case presentation

A 14-year-old girl presented with five days history of high grade fever, nausea and projectile vomiting with altered sensorium for last 2 days. No abnormalities were observed on computed tomography of the head done from outside. On examination, her vitals were normal and meningeal signs were presented. With a provisional diagnosis of acute encephalitis syndrome, relevant investigations in the form of lumbar puncture (Cytological and biochemical, gram staining, Cartridge Based Nucleic Amplification Test for Tuberculosis, virology, culture and sensitivity), malarial parasite serology and smear, Widal test etc. were sent. The patient was empirically started on intravenous antibiotics, antiviral and antimalarial with intravenous mannitol and antiepileptics while awaiting reports. Fundus examination was indicative of grade II papilledema, so oral Acetazolamide was added. Lumbar puncture revealed 6 cells (all mononuclear), protein 120 mg/dl, sugar 40mg/dl with concurrent blood sugar 98mg/dl and found to be positive for JE virus in cerebrospinal fluid (CSF) as well as in serum sample. Other investigations were non-contributory. The patient remained static for the next 4 days. Focal neurological deficit in the form of right hemiparesis was noticed at day 6 of hospitalisation, prompting MRI of the brain revealed multiple lesions with enhancement, some perilesional edema in

cerebral cortex suggestive of starry sky appearance (Fig. 1). Mantoux test was negative. Cysticercosis was also negative in serum by IgG enzyme-linked immunosorbent assay (ELISA) test. Steroids were started, awaiting reports. Magnetic resonance spectroscopy (MRS) was performed to differentiate between the two most common causes in our clinical practice neurotuberculosis and NCC. The patient had intermittent episodes of vomiting with waxing and waning altered sensorium during treatment. Subsequently, it was planned to add Albendazole. Despite inotropic and ventilator support with continued decongestant measures (3% hypertonic saline infusion), the patient did not improve and succumbed to her illness.

Discussion

The patient was initially diagnosed as a case of acute encephalitis syndrome on the basis of her clinical presentation. When the patient developed focal neurological deficit on 6th day and deteriorated; brain abscess, ventriculitis or subdural effusion were the possibility. But to our surprise, the presence of starry sky on MRI brain was documented. With signs of meningeal irritation were present, the diagnosis of cysticercal meningitis was also considered. This finding could be coincidental. Viable cysts might be presented in up to 1.3% of normal asymptomatic persons for a long period [3]. In this case, classic signs of acute meningitis were presented with MRS suggesting the possibility of cysticercal meningitis. Enzyme-linked immunoelectro transfer blot test

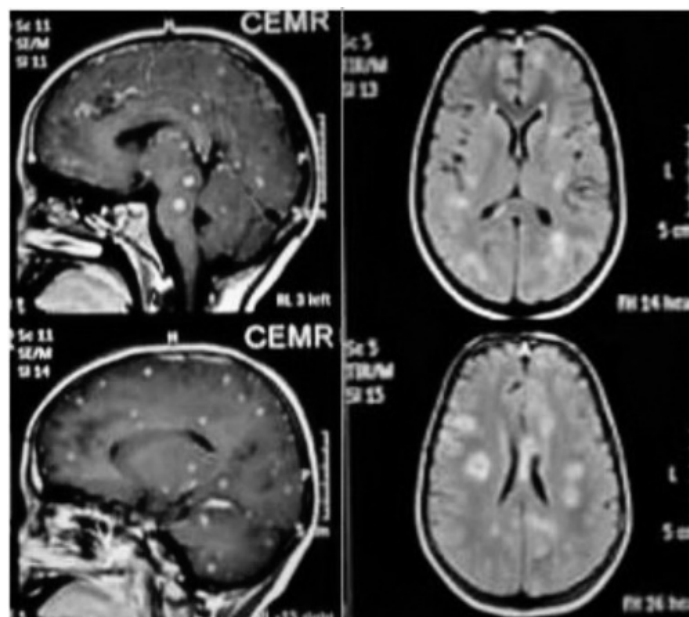


Fig. 1. MRI of brain showing multiple lesions with enhancement (Starry sky appearance).

(EITB) has a high sensitivity for cysticercal meningitis in CSF but not feasible in our setup. The incidence of Cysticercal meningitis is very low in India [4]. No standard treatment guidelines are available for the treatment of acute cysticercal meningitis in India. Anti-parasitic therapy is used for the management of chronic cysticercal meningitis [5]. Presence of multiple cysts like lesions on MRI brain justified our decision to treat this patient. Presence of JE positivity along with starry sky appearance in MRI complicated the picture in this case. During the initial prodromal stage in JE, it is not possible to make the definitive clinical diagnosis of the disease. As the prevalence of NCC in Indian patients is high, CSF eosinophilia should be kept in mind, when a concurrent parenchymal lesion is present. After prodromal stage, the encephalitis stage started on third to fifth day manifesting with seizures, altered sensorium and neck rigidity. Specific treatment for JE is still not available. Mortality in JE occurs in the first week due to neurological illness. Mortality is high which ranges from 8.5% to 72% [6]. T2-weighted MRI images have shown multiple hyperintense lesions of the cerebrum, thalamus as well as of cerebellum [7], but starry sky appearance is not reported yet. Corticosteroids are commonly used to suppress the inflammation in this condition [8]. The antiparasitic agent should not be given to such patients as it may further increase cerebral oedema by inflammatory response and that may lead to exacerbation of neurologic symptoms [9]. The prognosis of NCC encephalitis remains poor [10]. Few studies have described this co-infection of JE and NCC, as their epidemiologic and socio-demographic factors are similar like hygienic conditions, poor socioeconomic status, pig rearing, malnutrition etc [11, 12]. The presence of NCC with JE has been suggested as a factor of poor outcome resulting from additive effect of the two infections [13, 14]. Co-infections of JE and NCC may still be prevalent in children due to immunologic factors, an immature central nervous system, or neuronal plasticity, factors that have been implicated for JE being more common in children [15]. Although the mortality in JE is high but co-infection with NCC further increased the mortality from JE in the study by Desai et al. [13].

Conclusion

JE is rare in patients with multilesional NCC presenting as starry sky. Therefore, a thorough evaluation of the MRI brain for JE lesions in suspected patients with acute encephalitis and NCC can be helpful for making diagnosis of the patients with co-infection. Synergistic effect suggests the need for control of JE by vaccination, vector control and additive measures for the control of NCC.

Ethical Considerations

Consent

The consent was taken from the patient for the case report to be published.

Compliance with ethical guidelines

There were no ethical considerations to be considered in this research.

Funding

This research did not receive any grant from funding agencies in the public, commercial, or non-profit sectors.

Authors' contributions

All authors equally contributed in preparing this article.

Conflict of interest

Authors declare that there is no conflict of interest.

References

- [1] Basumatary LJ, Raja D, Bhuyan D, Das M, Goswami M, Kayal AK. Clinical and radiological spectrum of Japanese encephalitis. *J Neurol Sci* 2013;325:15-21. <https://doi.org/10.1016/j.jns.2012.11.007>
- [2] Kalita J, Misra UK. Comparison of CT scan and MRI findings in the diagnosis of Japanese encephalitis. *J Neurol Sci* 2000;174:3-8. [https://doi.org/10.1016/S0022-510X\(99\)00318-4](https://doi.org/10.1016/S0022-510X(99)00318-4)
- [3] Mahajan RC. Geographical distribution of human cysticercosis. In *Cysticercosis: Present state of Knowledge and Perspectives*, (Ed.) Ana Flisser, et al. Academic Press 1982, 39- 46.
- [4] Singhi P, Singhi S. Neurocysticercosis in children. *Indian J Pediatr*. 2009;76:537-545. <https://doi.org/10.1007/s12098-009-0139-5>
- [5] Kalra V, Mittal R, Rana KS, Gupta A. Neurocysticercosis: Indian experience. Perat MV (Ed), *New Developments in Hawaii. Neurology*, Monduzzi Editore S.P.A. Bologna, Italy; 1998 pp 353-359
- [6] Sengupta SN, Sen MK, Das PK, et al. Clinical profile of epidemic of Japanese encephalitis. *Indian J Med Res* 1976;54:1393-402. PMID: 190166
- [7] Abe TK, Kojima K, Shoji N, et al. Japanese encephalitis. *J Magn Reson Imaging* 1998;8:755-61. <https://doi.org/10.1002/jmri.1880080402>

- [8] Garcia HH, Gonzalez AE, Gilman RH. Cysticercosis of the central nervous system— how should it be managed? *Curr Opin Infect Dis* 2011;24:423–7. <https://doi.org/10.1097/QCO.0b013e32834a1b20>
- [9] Singhi P. Neurocysticercosis. *Ther Adv Neurol Disord* 2011;4:67–81. <https://doi.org/10.1177/1756285610395654>
- [10] GarciaHH,NashTE,BruttoOHD.Clinicalsymptoms,diagnosis,and treatment of neurocysticercosis. *Lancet Neurol* 2014;13:1202–15. <https://doi.org/10.1177/1756285610395654>
- [11] Singh P, Kalra N, Ratho RK, et al. Co-existent neurocysticercosis and Japanese B encephalitis: MR imaging co-relation. *AJNR Am J Neuroradiol*. 2001;22(6):1131-6. PMID: 11415909
- [12] Azad R, Gupta RK, Kumar S, et al. Is neurocysticercosis a risk factor in coexistent intracranial disease? An MRI based study. *J Neurol Neurosurg Psychiatry* 2003;74:359–6. <https://doi.org/10.1136/jnnp.74.3.359>
- [13] Desai A, Shankar SK, Jayakumar PN, et al. Co-existence of cerebral cysticercosis with Japanese encephalitis: a prognostic modulator. *Epidemiol Infect* 1997;118:165–71. <https://doi.org/10.1017/S0950268896007327>
- [14] Shankar SK, Vasudev Rao T, Mruthyunjayanna BP, Gourie Devi M, Deshpande D H. Autopsy study of brains during an epidemic of Japanese encephalitis in Karnataka. *Ind J Med Res* 1983;78:431–40. PMID: 6325338
- [15] Kalita J, Misra UK, Pandey S, et al. A comparison of clinical and radiological findings in adults and children with Japanese encephalitis. *Arch Neurol* 2003;60:1760–64. <https://doi.org/10.1001/archneur.60.12.1760>