



Case Report

Journal Homepage: <http://crp.tums.ac.ir>

Successful Pregnancy in A Patient with Fontan Surgery: A Case Report

Shadi Zamansaraei¹, Milad Nazari Sabet², Parvin Bahrami^{3*}

1. Assistant professor of Obstetrics and Gynecology Surgery, Isfahan University of Medical Sciences, Isfahan, Iran.
2. School of Medicine, Isfahan University of Medical Sciences, Isfahan, Iran.
3. Department of Cardiology, Alzahra University Hospital, Isfahan University of Medical Sciences, Isfahan, Iran.



Citation Zamansaraei Sh, Nazari Sabet M, Bahrami P. Successful Pregnancy in A Patient with Fontan Surgery: A Case Report. Case Reports in Clinical Practice. 2022; 7(5): 249-252.

Running Title Fontan Surgery and Pregnancy

**Article info:**

Received: August 10, 2022

Revised: August 28, 2022

Accepted: September 24, 2022

Keywords:

Fontan circulation;
Pregnancy; Congenital heart
Disease

ABSTRACT

The Fontan operation is a palliative procedure for patients with several forms of congenital heart disease unsuitable for biventricular circulation, especially tricuspid valve atresia. In this procedure, the vena cava flow is directed to the pulmonary arteries bypassing the ventricle. Pregnant patients with Fontan surgery in their post-surgical history have more maternal risks. We should counsel patients with saturations <85%, depressed ventricular function, refractory arrhythmia, or protein-losing enteropathy against pregnancy (mWHO; IV). In this study, we review a pregnant case that has successful pregnancy and Fontan palliation and lv systolic heart failure (LVEF: 35%) in her past medical history.

Background

Fontan surgery was initially invented in 1971 to treat a patient with tricuspid atresia [1]. In this surgery, the vena cava is anastomosed to the pulmonary artery with cavopulmonary connection [2]. After the surgery, one functional ventricle generates systematic blood flow, and systemic venous blood returns directly into the pulmonary arteries.

The circulation is volume-dependent, requiring an adequate preload and normal to low afterload to maintain cardiac output. In pregnancy, changes in body demand like increasing blood volume, decreasing systemic vascular resistance, and increased heart rate can influence patients with Fontan surgery and deteriorate their conditions [3]. Up to date, about 60 case reports have been published. According to different studies, nearly half of patients had a miscarriage, and one-third of them had cardiovascular

*** Corresponding Author:****Parvin Bahrami**

Address: Department of Cardiology, Alzahra University Hospital, Isfahan University of Medical Science, Isfahan, Iran.

E-mail: Parvinbahrami194194@gmail.com

complications during their pregnancies [1]. Some fetal complications during these high-risk pregnancies are low birth weight, preterm labor, intrauterine growth retardation and miscarriage [4]. In this study, we review a pregnant woman who experienced her first pregnancy had Fontan surgery in her childhood. In the end, we achieved the result that pregnancy is not an absolute contraindication in such patients. However, risks must be considered, including high-risk obstetric care, specialized cardiology assessment, follow-up, genetic counseling and neonatal care.

Case presentation

We report a 28-year-old Iranian woman diagnosed with tricuspid atresia in childhood and had undergone Fontan surgery at age 10 (unfortunately, the report of her surgery was not available). She married at the age of 26 and did not receive any hospitalized care during her pregnancy.

The patient was referred to our clinic every two weeks for prenatal care and received hydralazine 5mg tablet T.D.S., enoxaparin 60 mg B.D., isosorbide 10 mg tablet T.D.S., digoxin 0.25 mg tablet

daily, and metoprolol succinate 23.75 mg tablet daily. According to pharmacological references, hydralazine and isosorbide are in the C category. Although digoxin and metoprolol cross the placenta, there is no evidence of increased risk of adverse pregnancy outcomes. Enoxaparin cannot cross the placenta and is a safe agent during pregnancy. She was admitted to our hospital at a gestational age of 31 weeks in August 2017, with a chief complaint of dyspnea and breathed shortness. At admission, the patient's WHO class of heart disease was 4 with the systemic arterial blood pressure of 100/70 mmHg, regular pulse rate of 82 bpm, and blood oxygen saturation level of 93% in the room. Physical examination revealed no jugular venous congestion. The electrocardiogram showed sinus rhythm. Hemoglobin, hematocrit and platelet values were 16.9 g/dl, 47.3%, and 107*1000, respectively. The serum albumin level was 3.7 g/dl.

Maternal transthoracic echocardiography confirmed mild LV enlargement and moderate systolic function. Ejection fraction was 35%, hypoplastic R.V., mild M.R., hypoplastic P.V., Tricuspid atresia, large V.S.D., dilated sinus coronary(1.2cm), large V.S.D. (2.5cm) and thin inter-

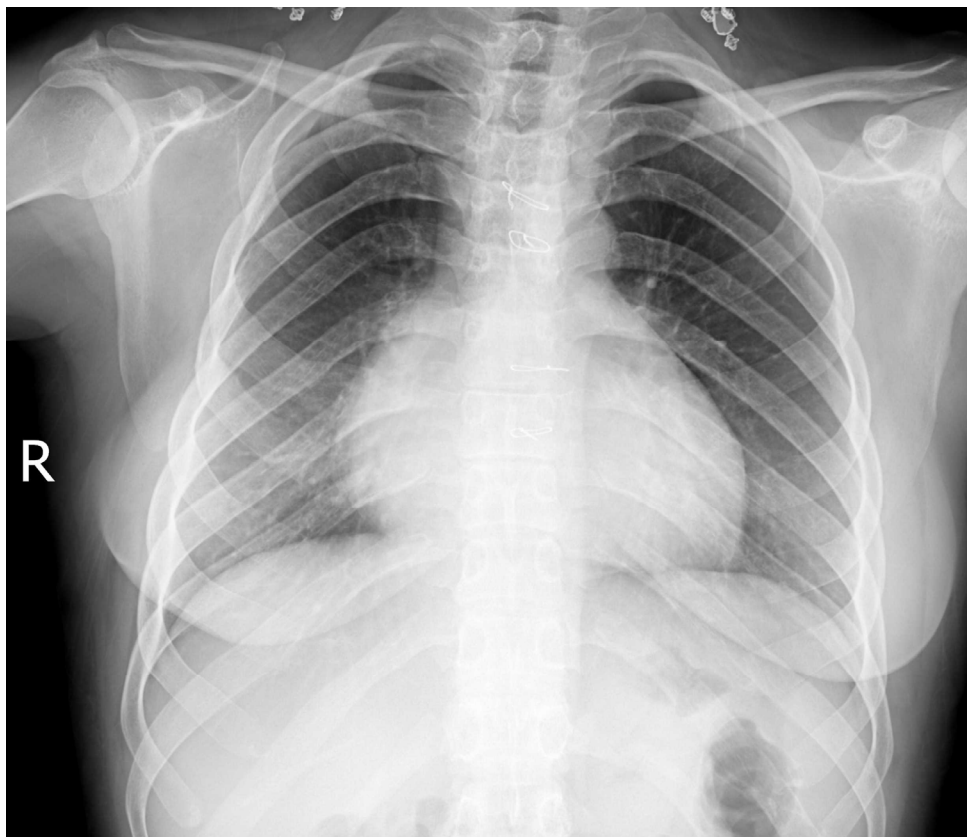

Fig. 1. C.X.R. of the patient.

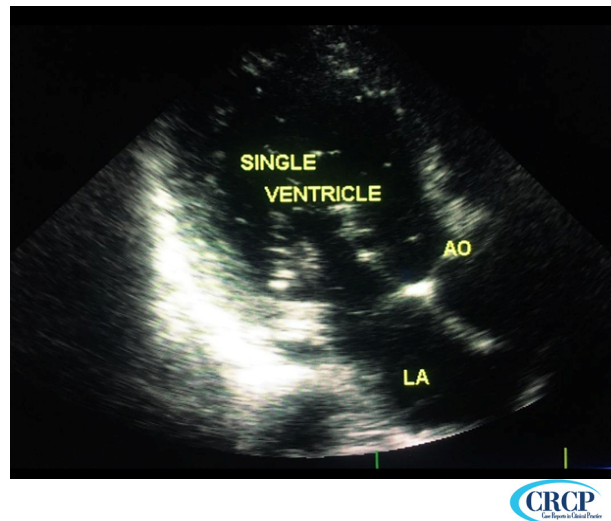


Fig. 2. The echocardiography of patients

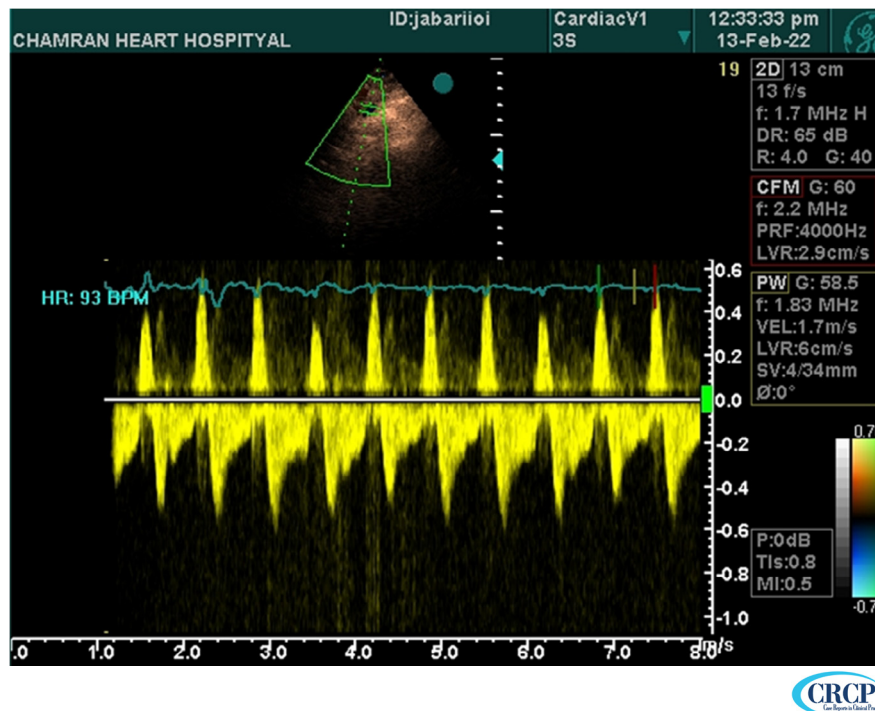


Fig. 3. Laminar circuit

atrial septa were noticed. Her prenatal care was done and fetal echocardiography at the age of 20 weeks and other fetal health screenings during her pregnancy, including anomaly scan, were normal. After hospitalization, the patient received Enoxaparin 60 bd during pregnancy and 48 hours of corticosteroid for fetal lung maturation. After 48 hours, the patient was admitted to CCU. Due to a decrease in platelet level and increased blood pressure level up to 130/90, the patient was suspected of pregnancy-induced hypertension and preeclampsia. After that, the oxygen saturation decreased to 88%, department of cardiology and obstetrics, anesthesiology, and perinatology decided to terminate the pregnancy

with the cesarean section under spinal-epidural anesthesia. The delivery was placed under maternal monitoring during labor alongside checking E.C.G., blood pressure, pulse oximetry and occasionally invasive blood pressure reading. Antibiotic prophylaxis at the time of delivery and adequate hydration were prescribed. After delivery, oxytocin is infused at a low rate (<2 units/min) to prevent vasodilatation. The male infant was born without any sign of congenital cardiovascular abnormality. Our patient received an anticoagulant during pregnancy and the peripartum six weeks after delivery. The patient was discharged after one week. C.X.R. and echocardiography of patients are shown in advance.

Discussion

A Fontan patient's ability to tolerate pregnancy depends on the ability to increase cardiac

output, even though venous pressure had been elevated. Fontan patients with good hemodynamic states before and during pregnancy can tolerate pregnancy. Pregnancy is not contraindicated in Fontan, but in patients with saturations < 85% physicians should counsel, depressed ventricular function, refractory arrhythmia, or protein-losing enteropathy against pregnancy (mWHOIV). Although comparative evaluation like monitoring during pregnancy and after delivery should be done for them [5]. In our case, increasing arterial pressure and decreasing platelet level promoted preeclampsia, so the department of cardiology, perinatology, and obstetrics decided to terminate her pregnancy at a gestational age of 33 weeks [5]. Every Fontan patient should admit for her delivery and have hospitalized care, and according to the evaluation of the maternal condition, her doctor could decide the time of delivery. Many Fontan pregnant cases reports had a successful pregnancy with no adverse outcome [6].

Conclusion

Although many articles presented successful pregnancies in Fontan patients, this study focused on Fontan and depressed systemic ventricular function. It was about individualized evaluating of every Fontan pregnant patient's risks. It emphasized maternal condition to terminate the pregnancy.

Monitoring should be focused on early signs of heart failure, arrhythmias, thromboembolic complications and worsening cyanosis. Generally, the patient should inform about the risks and complications of pregnancy before attempting to have a child.

Abbreviations

Three times a day (T.D.S.)

Twice a day (B.D.)

World Health Organization (WHO)

Right Ventricle (R.V.), Left Ventricle (LV)

Mitral Regurgitation (M.R.)

Pulmonary Valve (P.V.)

Ventricular Septa Defect (VSD)

Critical Care Unit (CCU)

Electrocardiograph (ECG)

Ethical Considerations

Ethics approval and consent to participate

The authors have ultimately observed ethical issues (including plagiarism, data fabrication, double publication). Also, the consent has been taken.

Consent to publish

The consent of publishing identifying images or other personal or clinical details have been taken.

Availability of data and materials

The data and material are available in Alzahra hospital, Isfahan, Iran.

Competing interests

Not applicable.

Funding

Not applicable

References

- Drenthen, W., et al., pregnancy and delivery in women after Fontan palliation. *Heart*, 2006. 92(9): p. 1290-4. <https://doi.org/10.1136/hrt.2005.085407>
- Al Najashi, K.S., et al., Four successful pregnancies in a patient with Fontan palliation and congenital heart disease: a case report. *J Cardiothorac Surg*, 2017. 12(1): p. 104. <https://doi.org/10.1186/s13019-017-0678-1>
- Khairy, P., N. Poirier, and L.A. Mercier, Univentricular heart. *Circulation*, 2007. 115(6): p. 800-12. <https://doi.org/10.1161/CIRCULATIONAHA.105.592378>
- Gorton, M., et al., Maternal and fetal outcomes of Pregnancy with Fontan circulation: A multicentric observational study. *Int J Cardiol*, 2015. 187: p. 84-9. <https://doi.org/10.1016/j.ijcard.2015.03.344>
- Canobbio, M.M., et al., Pregnancy outcomes after the Fontan repair. *J Am Coll Cardiol*, 1996. 28(3): p. 763-7. [https://doi.org/10.1016/0735-1097\(96\)00234-3](https://doi.org/10.1016/0735-1097(96)00234-3)
- Pundi, K.N., et al., Contraception Practices, and Pregnancy Outcome in Patients after Fontan Operation. *Congenit Heart Dis*, 2016. 11(1): p. 63-70. <https://doi.org/10.1111/chd.12291>
- (WHO), W.H.O., Global Antimicrobial Resistance, and Use Surveillance System (GLASS) Report: 2021. 2021: Geneva, Switzerland.
- Barbisan, P.R.T., et al., Macular phototoxicity after corneal cross-linking. *Clinical ophthalmology (Auckland, N.Z.)*, 2018. 12: p. 1801-1807. <https://doi.org/10.2147/OPTH.S176025>