



## Case Report

Journal Homepage: <http://crp.tums.ac.ir>

# Charcot Spine Arthropathy (CSA): A Rare Case Report



Mahendra Singh , Nandlal Bharwani<sup>\*</sup> , Navendu Ranjan , Mahesh Bhati

Department of Orthopaedics, Dr.S.N Medical College, Jodhpur.

Use your device to scan and read the article online



**Citation** Singh M, Bharwani N, Ranjan N, Bhati M. Charcot Spine Arthropathy (CSA): A Rare Case Report. Case Reports in Clinical Practice. 2023; 8(2):60-63

**Running Title** Charcot Spine: A Rare Entity



### Article info:

**Received:** 3 March 2023

**Revised:** 24 March 2023

**Accepted:** 25 April 2023

### Keywords:

Charcot spine; American Spinal Injury Association (ASIA) grading; Thoracic spine; Trauma; Male

## ABSTRACT

Charcot Spine Arthropathy (CSA) is a form of degenerative disease affecting vertebra of lumbar and thoraco-lumbar region. It is commonly seen after injury to the spinal cord or in patients with traumatic paraplegia. It was first described by Kronig in 1884.

Case Report- A 35year old male patient presented to our outpatient clinic with complaint of difficulty in changing his position while sitting, lying down, and sitting on a wheel chair. In 2014, he had sustained injury to his spinal cord with bowel and bladder involvement with ASIA-A grade neurology for which long segment fixation was performed from D7-D10 level and the patient was wheel chair bound after surgery. In the present case scenario, the patient was managed conservatively with bed rest, immobilization and medications for pain relief as stated in the existing literature.

Conclusion- CSA is a disease of surgical origin commonly seen in patients with spinal cord injury in the past. Although surgery in the form of circumferential arthrodesis is the treatment of choice in most of cases, it is reserved for cases with instability, as it is associated with complications like infections and hardware failure.

### \* Corresponding Author:

**Nandlal Bharwani, MD.**

**Address:** Department of Orthopaedics, Dr.S.N Medical College, Jodhpur.

**E-mail:** [id-nandlalbharwani21@gmail.com](mailto:nd-nandlalbharwani21@gmail.com)



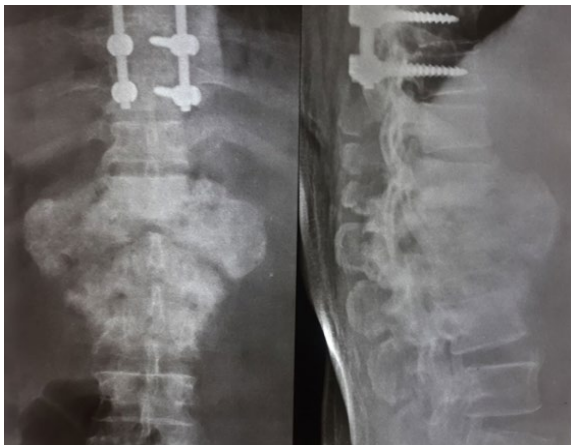## Introduction

In 1884, the first description of Charcot spine was given by Kronig for a patient presenting with tabes dorsalis.[1] Although lower limbs are commonly involved, spine is involved in 6-20% of all the cases. It is a form of degenerative disease commonly affecting vertebral body of the thoraco-lumbar region.[2] Conditions like injury to spinal cord and disease leading to loss of nociception and proprioception can result in CSA in the near future. [3,4] Microtrauma leading to loss of muscular contraction that helps in giving stability to the spine was thought to be the mechanism behind this condition.[3-5] CSA results in destruction of ligaments, endplates, and intervertebral disc space narrowing, which leads to instability of vertebral column, and fractures of the vertebral body. [3-6] In the present case, patient presenting with Charcot spine arthropathy had history of spinal cord injury in the past. Treatment protocol was elicited in a study done on 201 patients and in a case series which included 23 patients. [7,8]

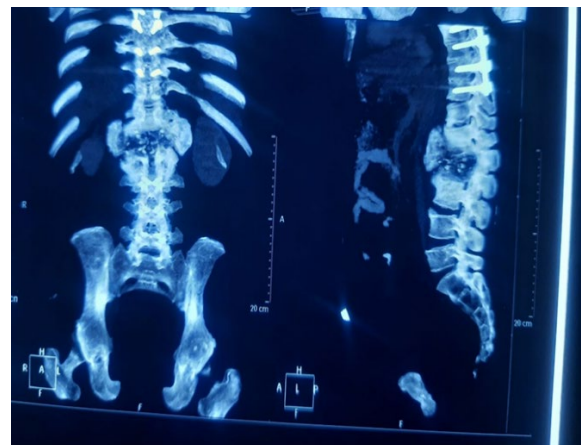
## Case Presentation

A 35-year-old male patient presented to our outpatient clinic with complaint of difficulty in changing his position while sitting, lying down, and sitting on a wheel chair. In 2014, he had sustained injury to his spinal cord with bowel and bladder involvement and ASIA-A grade neurology for which long segment fixation was performed and the patient became paraplegic with bowel, bladder involvement post-surgery. Digital radiograph of dorso-lumbar spine was performed to investigate the cause of back pain and difficulty in ambulation. Digital radiograph showed destruction of lumbar vertebrae (L1 and L2) which was just below the injured segment. Then CT-scan and MRI were performed for further detailed evaluation of the condition, and on the CT-scan of dorso-lumbar region, vacuum disc phenomenon and disc space involvement was noted.

MRI showed destruction of endplates and necrosis at L1& L2 level, and vertebral body was replaced by large area of disorganized paraspinal and intraspinal calcified mass. From T12-L3 vertebrae, lytic areas were seen with involvement of both anterior and posterior column along with soft tissue mass extension. Wagner et al. "6 D's" was seen in the present case scenario and could be observed on the available imaging. [9,10] In the present case scenario, the patient was managed conservatively with bed rest, immobilization and medications for pain relief, as stated in the existing literature.



**Fig. 1.** AP and Lateral view of dorso-lumbar spine showed pseudotumor and hypertrophic ossification from D12-L3 level.



**Fig. 2.** Coronal and Sagittal sections of CT-scan showing endplates erosion and debris at disc space level with vacuum phenomenon.

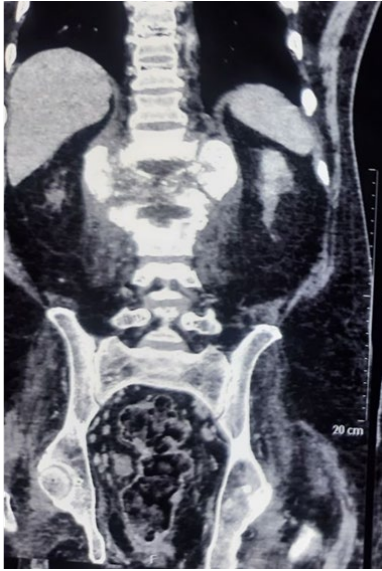

Fig. 3. Coronal section of MRI LUMBO-SACRAL area showing Wagner et al. '6D's'.

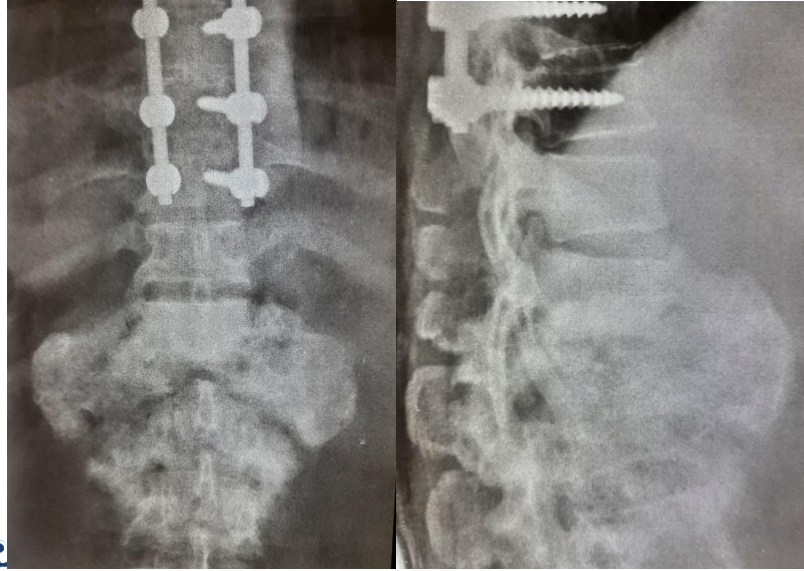


Fig. 4. AP and Lateral of Dosro-lumbar region showing Hypertrophic stage of CSA at final follow-up

## Discussion

In 1831, for the first time, a correlation between peripheral joint arthropathy and lesion in spinal cord was stated by Mitchell et al.[11,12] In 1978, the first case was noted with traumatic spinal cord injury and since then cases are increasing.[2,12] In the present case report, CSA was seen after seven years of traumatic spinal cord injury which correlates with the existing literature that states occurrence of CSA seen in the present report is likely between 2.5 to 34 years after spinal cord injury.[12,13] In the present report, clinical features like difficulty in changing position, sitting on a wheel chair and painless swelling, deformity are similar to the clinical features noted in the past studies. The possible mechanism for CSA is thought to be decreased proprioception and pain perception. In cases with traumatic paraplegia, use of upper limb for daily routine activities and position change was considered as a possible cause.[13]

The other differentials of CSA consist of metastatic spinal disease, spondylodiscitis, pyogenic discitis, Paget's disease and Osteomyelitis. [7,14] CSA and Spondylodiscitis can be differentiated by vacuum disc phenomenon and history of SCI with long segment fixation in the past, seen commonly in patients of CSA.[15] Tumors of spinal origin or metastatic disease can be differentiated on the basis of immunohistochemistry. In case of Paget's disease, a characteristic picture frame vertebrae sign is seen on radiographs (hypertrophied trabecular bone, end plates and resorption of anterior and posterior vertebral borders).[17]

X-ray, CT-scan, MRI of the affected segment shows joint space narrowing, debris from endplates and bone from subchondral region.[4] If proper treatment protocol for CSA is not followed, it may lead to subluxation, dislocation and creation of pseudo-arthrosis at the affected segment.[16]

Although surgery in the form of arthrodesis is considered as the treatment of choice for CSA patients, conservative treatment should be given to all patients in the form of pain killers, neurotropic drugs, physiotherapy and orthoses. In the study conducted by Moreau et al., out of 12 patients, 7 cases were given conservative treatment out of which 5 patients had improvement in symptoms and 2 patients had to undergo

surgery.[15] Therefore, conservative treatment was given to this present case and relief in symptoms was noted.

Conclusion- CSA is a disorder of degenerative changes in spine which is seen commonly after injury to the spinal cord or in patients with traumatic paraplegia. Repeated micro-trauma leads to vertebral joint subluxation and dislocation and can result in neurological deficits. Proper imaging helps in making diagnosis easy. Though surgery in the form of arthrodesis circumferentially is considered as the treatment of choice for CSA patients, it is reserved for cases presenting with severe instability due to its potential complications like infection and hardware failure. In the present report, conservative treatment was given to the patient. Till now, many studies exist where conservative treatment was administered and the patient showed good progress clinically.

Declaration of Patient Consent- The authors certify that they have obtained all appropriate patient consent forms. In the form, the patient's parent gave his consent for the patient's images and other clinical information to be reported in this manuscript. The parent understood that the patient's name and initials will not be published and due efforts will be made to conceal her identity but anonymity cannot be guaranteed.

## Ethical Considerations

### Compliance with ethical guidelines

consent was taken from patient and relatives

### Funding

This research did not receive any grant from funding agencies in the public, commercial, or non-profit sectors.

### Conflict of interest

The authors declared no conflict of interest.

### Acknowledgements

None

### References

- [1] Kronig G. Spondylolisthesis at a tabetic spine. *Zeit Klin Med* 1884; 7: 165-170.
- [2] Park YH, Taylor JA, Szollar SM, et al. Imaging findings in spinal neuroarthropathy. *Spine (Phila Pa 1976)* 1994; 19: 1499-1504.
- [3] Gupta R. A short history of neuropathic arthropathy. *Clin Orthop Relat Res* 1993; 49: 43-49.
- [4] Barrey C, Massourides H, Cotton F, et al. Charcot spine: two new case reports and a systematic review of 109 clinical cases from the literature. *Am Phys Rehabil Med* 2010; 53: 200-220.
- [5] Wirth CR, Jacobs RL and Rolander SD. Neuropathic spinal arthropathy a review of the Charcot spine. *Spine (Phila Pa 1976)* 1980; 5: 558-567.
- [6] Harrison MJ, Sacher M, Rosenblum BR, et al. Spinal Charcot arthropathy. *Neurosurgery* 1991; 28: 273-277.
- [7] Jacobs WB, Bransford RJ, Bellabarba C, et al. Surgical management of Charcot spinal arthropathy: a single-center retrospective series highlighting the evolution of management. *F Neurosurg Spine* 2012; 17: 422-431.
- [8] Solinsky R, Donovan JM and Kirshblum SC. Charcot spine following chronic spinal cord injury: an analysis of 201 published cases. *Spinal Cord* 2019; 57: 85-90.
- [9] Lebetter LN, Salzman KL, Sanders RK, et al. Spinal neuroarthropathy: pathophysiology, clinical and imaging features, and differential diagnosis. *Radiographics* 2016; 36: 783-789.
- [10] Wagner SC, Schweitzer ME, Morrison WB, et al. Can imaging findings help differentiate spinal neuropathic arthropathy from disk space infection? Initial experience. *Radiology* 2000; 214:693-699.
- [11] McNeel DP, Ehni G (1969) Charcot joint of the lumbar spine. *J Neurosurg* 30: 55-61.
- [12] Schwartz HS (1990) Traumatic Charcot spine. *J Spinal Disord* 3: 269-275.
- [13] Crim JR et al (1988) Spinal neuroarthropathy after traumatic paraplegia. *Am J Neuroradiol* 9: 359-362.
- [14] van Eeckhoudt S, Minet M, Lecouvet F, Galant C, Banse X, Lambert M, et al. Charcot spinal arthropathy in a diabetic patient. *Acta Clin Belg* 2014; 69:296-8.
- [15] Moreau S, Lonjon G, Jameson R, Judet T, Garreau de Loubresse C. Does all Charcot spine require surgery? *Orthop Traumatol Surg Res* 2014; 100:779-84
- [16] Sobel JW, Bohlman HH, Freehafer AA (1985) Charcot's arthropathy of the spine following spinal cord injury. *J Bone Jt Surg* 67-A (5): 771-776.
- [17] Graham TS. The ivory vertebra signs. *Radiology* 2005; 235 2: 614–615. [PubMed]