

# Portal Vein Thrombosis in a Woman with a Large Uterine Fibroma



Fariba Almassinokiani<sup>1</sup>, Peyman Akbari<sup>2\*</sup>, Alireza Almasi Nokiani<sup>3</sup>, Niloufar Sarchami<sup>4</sup>

1. Obstetrician and Gynecologist, Fellowship of laparoscopy, minimally invasive surgery research center, Iran University of Medical Sciences, Tehran, Iran.
2. Tehran University of medical sciences, Tehran, Iran.
3. Firoozabadi Clinical Research Development Unit (FCRDU), Iran University of Medical Sciences (IUMS), Tehran, Iran.
4. Iran University of Medical Sciences, Tehran, Iran.

Use your device to scan and read the article online



**Citation** Almassinokiani F, Akbari P, Almasi Nokiani A, Sarchami N. Portal Vein Thrombosis in a Woman with a Large Uterine Fibroma. Case Reports in Clinical Practice. 2022; 7(6): 306-312.

**Running Title** Portal Vein Thrombosis in a Woman with a Large Uterine Fibroma



## Article info:

Received: November 2, 2022

Revised: November 23, 2022

Accepted: December 14, 2022

## Keywords:

Portal vein; Thrombosis;  
Uterine fibroma

## ABSTRACT

This article presents a case of portal vein thrombosis accompanied by a large uterine fibroma. A 37-year-old virgin woman presented with vaginal bleeding, abdominal mass, fever, dyspnea and lower limbs edema. In past medical history, she did not have any systemic diseases. She had menometrorrhagia from four years ago. She was admitted with diagnosis of a large uterine fibroma and was suspected of COVID 19 pneumonia or thrombophlebitis. The final diagnosis was a large uterine fibroma with chronic portal vein thrombosis. Although uterine fibromas are benign tumors, they may make serious life-threatening complications like thrombosis. The cause of thrombosis is the pressure effect of fibroma and/ or transfusion to treat anemia. Although there may be other unknown etiologies for thrombosis in these patients. We suggest that existence of a large uterine myomas should be known as a risk factor for thrombosis ( like IBS, Covid 19 and etc.) and be given a score in Caprini Score system, to start anticoagulation before and after any surgical intervention.

## Introduction

Uterine leiomyoma (fibroma) is the most common benign pelvic neoplasm in women [1]. They are noncancerous monoclonal tumors arising from myometrium [2]. The common symptoms of these tumors are abnormal uterine bleeding (AUB), pelvic pain or pressure, abdominal mass and also reproductive effects (e.g.,

infertility, adverse pregnancy outcomes). Bulk related symptoms can cause urinary tract or bowel obstruction or venous compression [3]. Very large uteri may compress the veins and lead to an increase risk of thromboembolic events as it can change the blood flow as a reason of venous return obstruction [4]. Paying more attention to this effect is well defined as Virchow's triad, consist of three factors which may predispose developing of venous thrombosis including: Hypercoagulability (inherited or acquired),

### \* Corresponding Author:

**Peyman Akbari**

Address: Tehran University of Medical Sciences, Tehran, Iran.

E-mail: [Peymanakbarii1372@gmail.com](mailto:Peymanakbarii1372@gmail.com)



Stasis due to alternation in blood flow (as it happens in very large uterine leiomyoma) and vascular endothelial injury. Thrombosis and thromboembolism in combination with fibroma have been reported rarely [4-12]. Furthermore, portal vein thrombosis which is defined as a complete or partial occlusion of portal vein has been reported less frequent than thrombosis in other vessels.

### Case report

On May 2020, a 37-year-old unmarried and virgin woman referred to emergency ward of a tertiary level hospital due to vaginal bleeding, fever, and dyspnea. She had a history of menometrorrhagia, anemia and pelvic pain from four years ago. She was in the hysterectomy operation list due to AUB and large uterine myomas. She referred to hospital with dyspnea, malaise, fever, abdominal distention and

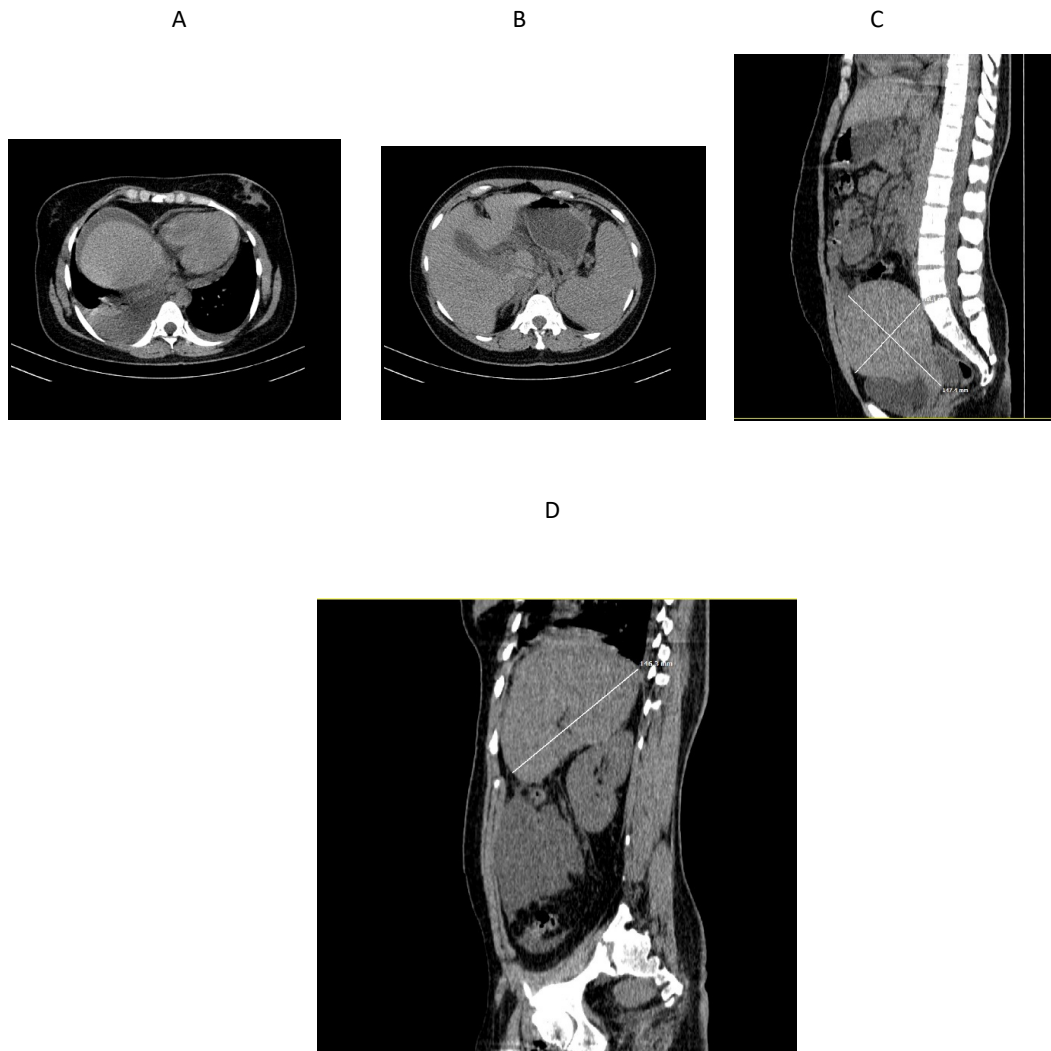
both legs edema with no size discrepancy which all had been started five days ago.

She had the past history of a large uterine fibromas (according to her recent ultrasound).

Vital signs on arriving to emergency ward were:

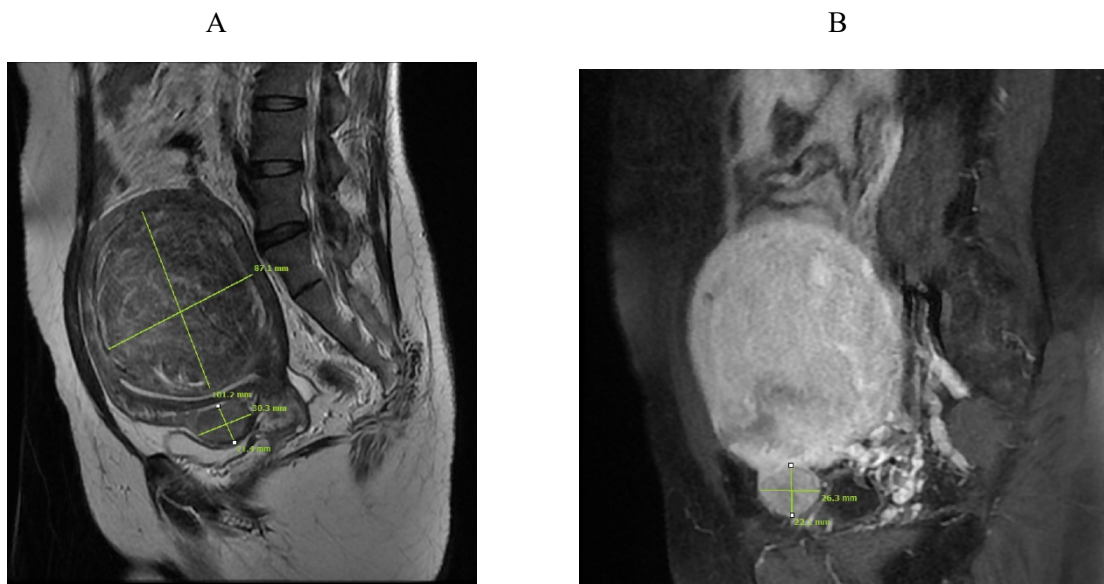
PR= 130/min, Blood pressure= 100/70 mmHg, Oral temperature: 38° C, Respiratory rate: 28/min, O2 saturation with face mask: 98%

On physical examination, she had pale and non-icteric sclera. She had fine crackles on auscultation at base of her both lungs. Abdomen was distended and in palpation was soft with mild generalized tenderness. A 30 weeks of pregnancy sized mass was detectable. Considering the large mass, the evaluation of liver and spleen was not accurate. Hymen was intact so vaginal examination did not perform. She had 2+ vaginal bleeding. Upper extremities were normal but both lower extremities had moderate pitting edema just below the knees.



**Fig. 1.** CT scan of the abdomen and pelvis without contrast dated 25.1.2020. Axial (a and b), sagittal (c) and oblique sagittal (d) sections show ascites and bilateral pleural effusion with normal liver border and no evidence of cirrhosis in addition to crowding in the porta hepatis, a large uterus (147x108mm) and a large spleen (146mm in length).

Fig. 2.



**Fig. 2.** Pelvic MRI dated 28.4.2020. T2W (a) and contrast-enhanced T1W fat-saturated sagittal (b) images show three uterine myomas: a posterior wall FIGO3 myoma, measuring 101x87mm and two anterior wall myomas FIGO6, measuring 30x21mm and 26x22mm.

The patient was admitted with differential diagnosis of: Myoma accompanied with Pulmonary thromboembolism or COVID 19 infection Pneumonia.

Initial Para-clinical results:

CBC: WBC: 21000/microliter (PMN: 83%), Hb: 6 mg/dl, Platelet: 269000/microliter.

ESR: >140, CRP: 48, LDH: 702 U/L.CPK: 229 U/L.

AST, ALT and ALP and bilirubin were in normal range.

Cr: 0.8 mg/dl

Total protein: 4.9 mg/dl

Albumin: 2.7mg/dl,

COVID 19 IgM and IgG were negative.

Venous blood gas (VBG): PH: 7.38, Pco2: 40.6 mmHg, HCO3: 24.3, PO2: 80.8 mmHg

Report of abdominopelvic computed tomography and MRI without contrast which was performed before admission: The uterus is grossly enlarged with moderate ascites and mild splenomegaly. The portal vein is undetectable that can be due to portal vein thrombosis. There are few myomas (two larger ones are intramural subserosal 14\*10\*10 cm on posterior wall and few smaller fibromas)

(Figures 1 and 2).

Report of spiral chest computed tomography on admission day: moderate ascites, mild cardiomegaly, mild bilateral pleural effusion with collapsed consolidation of adjacent lobes with no pleural thickening were seen. No thrombosis or filling defects were detected in pulmonary artery.

Due to protracted active vaginal bleeding and anemia, the patient received two units of packed cells and 2 units of FFP and underwent midline laparotomy for abdominal hysterectomy. The day after

laparotomy Enoxaparin 40 mg subcutaneous daily was injected for ten days. Then she was discharged with Rivaroxaban 10 mg/day. The tissue was sent for pathology examination. Few days after operation, ascites evaluation was done with fluid paracentesis, gastroesophageal endoscopy and Doppler ultrasound to find out the probability of any portal hypertension. Pathology report: the weight of uterus was 1500 gram; the microscopic diagnosis was leiomyoma.

Paracentesis sample analysis revealed transudate pleural effusion and high SAAG ascites fluid compatibles with portal hypertension.

Plasma level of factor V Leiden, Anti thrombin III, Protein C, Protein S,  $\beta$ 2microglobulin, Anti Cardiolipin antibody, ANA and Lupus anticoagulant antibody were in normal range.

Gastroesophageal endoscopy revealed 2 columns of esophageal varices compatible with F1.

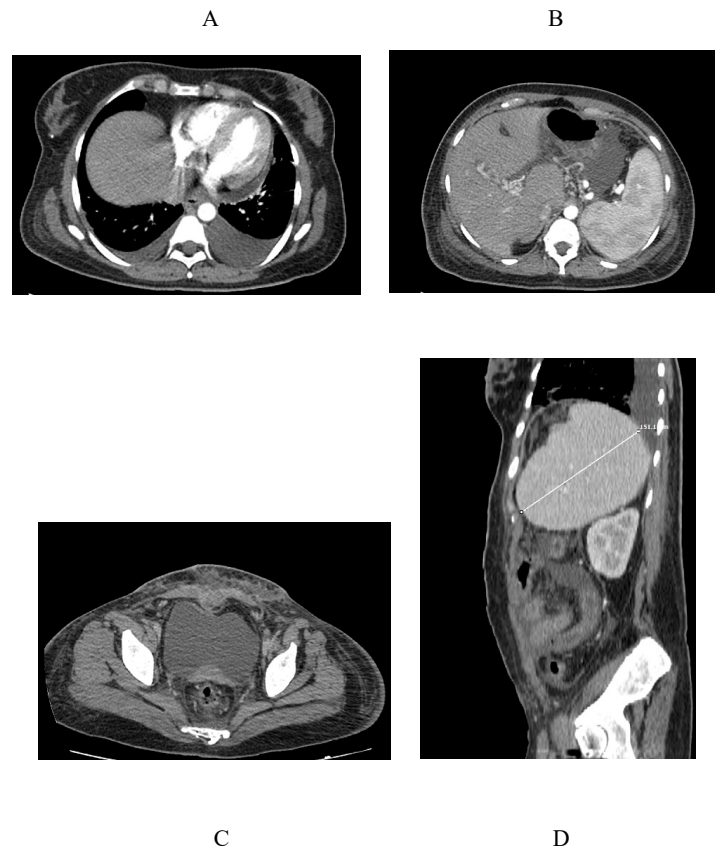
Abdominopelvic CT scan with contrast after hysterectomy: inferior vena cava (IVC) and intrahepatic veins had normal flow. Tortuosity of portal vein makes the diagnosis of chronic vein thrombosis probable. The portal vein branches were not dilated. Splenic vein was tortuous with dilated vessels in hilum of spleen which can be due to portal hypertension (Figure 3).

PCR result of COVID 19 was ready in 72 hours after admission which was negative.

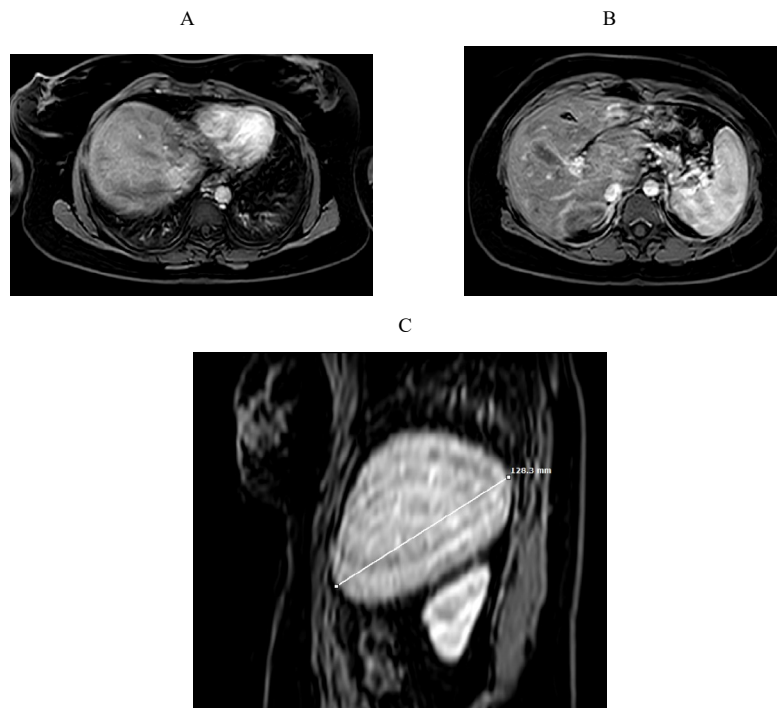
Urine culture after 48 hours was positive (more than 100000 colony count/ml with E.Coli).

After discharge the patient continued her follow-up under the observation of Gastrointestinal department.

Abdominal MRI without contrast in 17 months



**Fig. 3.** Contrast-enhanced CT scan of the abdomen and pelvis dated 31.5.2020. Axial (a-c) and oblique sagittal reconstructed (d) images show bilateral pleural effusion, ascites, cavernous transformation of portal vein and a large spleen (151mm in length) indicating chronic portal vein thrombosis in addition to absence of the uterus due to previous hysterectomy.



**Fig. 4.** Contrast-enhanced MRI of the abdomen dated 2.11.2021. Fat-suppressed axial (a and b) and reconstructed sagittal oblique (c) images show absence of pleural effusion, absence of ascites, cavernous transformation of the portal vein and normal spleen size (128mm in length).

after hysterectomy: no ascites, normal spleen size and cavernous formation due to chronic portal vein thrombosis (Figure 4).

## Discussion

Fibroma or uterine leiomyoma is common benign neoplasm of uterus and is the most common cause of hysterectomy in USA [1]. In most cases, it is not symptomatic and no treatment is required. Its clinical manifestations depend on its size, location and pressure effect on near organs. The most common manifestations of uterine fibroma are abnormal uterine bleeding, pelvic pain, abdominal mass and symptoms due to pressure on adjacent organs. Venous thrombosis is a very rare and life-threatening complication of uterine fibromas and is reported more frequent in Iliac veins and IVC and can cause pulmonary emboli [4-12]. Portal vein thrombosis with a large myoma is reported less frequent than any other veins [12].

Stasis, endothelial damage and hypercoagulable state are three causes of thrombosis (Virchow's triad). Pelvic vein stasis due to the pressure effect of a large leiomyoma and hyper-coagulopathy can be the cause of thrombosis in our patient. Iron deficiency itself, increases the number of megakaryocytes and platelets. Additionally, hypoxemia induced by anemia, can result in endothelial damage [13-15]. Fibroma has estrogen receptor [1] and estrogen is one of the predisposing factors that can affect on hypercoagulable state. Perhaps in our patient being in reproductive age could be one of the causal factors of thrombosis. Thrombosis in combination with fibromas are often detected in lower limbs and 75% of them will be in the left side [16]. It was often after using of oral contraceptive pills for controlling vaginal bleeding. Concurrent thrombosis and fibromas are more common in fibromas weighting more than 1000g [15]. The risk of thrombosis accompanied with fibroma in OCP users is higher than non-users (16). This risk is estrogen dose dependent and also the type of progesterone [17-20].

In this case, dehydration and urinary tract infection were probable causes of fever at admission time and the most probable cause of respiratory distress was due to ascites and pleural effusion.

Budd Chiari syndrome and hepatic vein thrombosis have been reported 47 years after hysterectomy due to large uterine fibromas. In that patient, 47 years after hysterectomy, intravenous leiomyomatosis appeared expanded into the common iliac vein, IVC and portal veins [21]. Budd Chiari syndrome is defined as acute hepatic venous outflow tract obstruction and is characterized by ascites, abdominal pain and hepatomegaly. The large size of fibroma (more

than 10 cm) increases the chance of thrombosis (22). As it is known, generally, the identified factors of thromboembolic events are thrombophilia, malignancies, immobility, history of thrombosis, pregnancy, inflammatory bowel diseases, serious lung disease, abnormal pulmonary function, acute myocardial infarction, congestive heart failure, OCP usage and etc., (23).

Several risk assessment models to estimate the risk of post operative venous thrombophlebitis (VTE) have been developed but the Caprini score (2005) for prediction of the post-operative VTE is most extensively used [24]. The Caprini Score had several revisions since its original publication [25]. The original Caprini Score is validated in many surgical specialists and also in gynecologic surgeries [25-26]. The revisions are due to adding new risk factors to that table. For example the operations lasting more than 6 hours assigns 5 points [27] or asymptomatic covid 19 assigns 2 points [28]. The American Venous Forum has already recommended using the Caprini Score for VTE risk assessment with using the original model of Caprini Score. They suggest that a score of 8 or more needs to pharmacological prophylaxis in the hospital and after discharge [29]. Mayo clinic recommends patients who are at low risk for VTE (Caprini 1-2) to receive either mechanical or pharmacological prophylaxis. Patients with moderate risk factor (Caprini 3-4) and high risk (Caprini 5 or more) to receive pharmacological prophylaxis with or without mechanical prophylaxis [30].

With a large myomas, it exists the Virchow's triad: stasis due to venous pressure [13-15] and hypercoagulable state and endothelial trauma due to transfusion and hypoxemia [31-33]

The American college of chest physician guideline did not recommend any type of anticoagulant agents for large leiomyoma [34].

To discuss how important, it would be to use anti-coagulant in such patients we take a look at some researches around vein thrombosis and treatment results. In one prospective study on 95 patients with acute portal vein thrombosis (PVT) and without cirrhosis anticoagulant, therapy led to recanalization of portal vein in 39% of patients (35). The goal of anti-coagulation in patients with PVT is to prevent recurrent thrombosis, prevent thrombosis extension and promote recanalization. While the rule of anticoagulant therapy in chronic PVT is unclear but, in some studies, it has been prescribed. In a retrospective study on patients with cirrhosis with acute and sub-acute PVT, the anticoagulation therapy led to partial

or complete recanalization in 60% of patients [36]. Of course, spontaneous PVT recanalization in patients with cirrhosis has been reported [37]. As we do not know in which patient recanalization will appear, anticoagulant therapy is recommended for both acute and chronic PVT [38]. Before starting anti coagulation, we must weight for the benefits of therapy against the bleeding risk (For example: thrombocytopenia or high-risk varicose veins). In one RCT on PVT (both acute and chronic) treatment with 1mg/kg low molecular weight heparin (LMWH) BID was compared with 1.5 mg/kg LMWH daily. There was no significant difference in rate of complete or partial recanalization at six months but the risk of bleeding complications in 1.5 mg/kg LMWH was higher [39]. Decision for initiation of anticoagulant therapy in cirrhosis and portal vein thrombosis must be individualized for each patient [38].

## Conclusion

Although uterine fibromas are benign tumors, they may make serious life-threatening complications like thrombosis. Currently, a large myoma does not included in Caprini scoring system and anticoagulant therapy does not depend on the existence of large myomas. As compression effect of large myoma in combination with transfusion related coagulopathy (before or after operation) can increase the risk of thrombosis in such patients, we suggest to consider the effect of a large uterine myoma as an additional factor that can have some effects on the rate of thromboembolic accidents and revise the Caprini score with this considerations. Therefore, prophylactic anticoagulation may have been considered before and after all myomectomy or hysterectomies for large myomas.

## Ethical Considerations

### Compliance with ethical guidelines

There were no ethical considerations to be considered in this article.

### Funding

The authors declare that they did not receive any funding for the elaboration of this paper.

### Conflict of Interests

The authors have no conflict of interest to declare.

## References

1. Parker WH. Uterine fibroids in: Berek JS. Berek & Novak's Gynecology. 16<sup>th</sup> ed. Wolters Kluwer. 2020.
2. Stanko CM, Severson MA, 2nd, Molpus KL. Deep venous thrombosis associated with large leiomyomata uteri. A case report. *J Reprod Med*. 2001;46(4):405-7. PMID: 11354847
3. Sheikh HH. Uterine leiomyoma as a rare cause of acute abdomen and intestinal gangrene. *Am J Obstet Gynecol*. 1998;179(3 Pt 1):830-1. [https://doi.org/10.1016/S0002-9378\(98\)70097-3](https://doi.org/10.1016/S0002-9378(98)70097-3)
4. Falcone M, Serra P. Massive pulmonary embolism in a woman with leiomyomatous uterus causing pelvic deep venous thrombosis. *Ann Ital Med Int*. 2005;20(2):104-7.
5. Srettabunjong S. Systemic thromboembolism after deep vein thrombosis caused by uterine myomas. *Am J Forensic Med Pathol*. 2013;34(3):207-9. <https://doi.org/10.1097/PAF.0b013e318298a456>
6. Hawes J, Lohr J, Blum B, Bhati A, Bhaskaran J, Engel A. Large uterine fibroids causing mechanical obstruction of the inferior vena cava and subsequent thrombosis: a case report. *Vasc Endovascular Surg*. 2006;40(5):425-7. <https://doi.org/10.1177/1538574406291333>
7. Bonito M, Gulemi L, Basili R, Brunetti G, Roselli D. Thrombosis associated with a large uterine myoma: case report. *Clin Exp Obstet Gynecol*. 2007;34(3):188-9.
8. Khilanani R, Dandolu V. Extensive iliac vein thrombosis as a rare complication of a uterine leiomyoma: a case report. *J Reprod Med*. 2007;52(6):537-8.
9. Ippolito E, Buora A, Belcaro G, Alari G, Arpaia G, Ciammaichella G. Deep vein thrombosis and pulmonary embolism in a patient affected by uterine fibroids: clinical case. *Panminerva Med*. 2012;54(1 Suppl 4):97-9.
10. Fernandes FL, Dinardo CL, Terra-Filho M. Uterine myoma as a cause of iliac vein thrombosis and pulmonary embolism: common disease, rare complication. *Respirol Case Rep*. 2014;2(4):132-4. <https://doi.org/10.1002/rcr2.79>
11. Liu B, Liu C, Guan H, Li Y, Song X, Shen K, et al. Intravenous leiomyomatosis with inferior vena cava and heart extension. *J Vasc Surg*. 2009;50(4):897-902. <https://doi.org/10.1016/j.jvs.2009.04.037>
12. Moniaga NC, Randall LM. Uterine leiomyomatosis with intracaval and intracardiac extension. *Gynecol Oncol Case Rep*. 2012;2(4):130-2. <https://doi.org/10.1016/j.gynor.2012.08.003>
13. Shiota M, Kotani Y, Umamoto M, Tobiume T, Tsuritani M, Shimaoka M, et al. Deep-vein thrombosis is associated with large uterine fibroids. *Tohoku J Exp Med*. 2011;224(2):87-9. <https://doi.org/10.1620/tjem.224.87>
14. Cărbunaru A, Herlea, Ionescu M, Dumitrașcu T. Extensive Left Iliac Veins and Inferior Vena Cava Thrombosis Revealing a Giant Uterine Myoma. *Rom J Intern Med*. 2016;54(1):70-3. <https://doi.org/10.1515/rjim-2016-0009>
15. Riat R, Chowdary P, Mavrides E, Magos A, Gatt A. Is there an association between thrombosis and fibroids? A single centre experience and literature review. *Int J Lab Hematol*. 2013;35(1):e13-6. <https://doi.org/10.1111/ijlh.12020>
16. Devabhaktuni P, Gupta P, Bhupatiraju S, Puranam B, Abdul S. Uterine Fibromyoma and Intravascular Thrombosis-Eight Cases. *Open Journal of Obstetrics and Gynecology*. 2014; 04:197-207.

<https://doi.org/10.4236/ojog.2014.44033>

17. van Hylckama Vlieg, A., Helmerhorst, F.M., Vandenbroucke, J.P., Doggen, C.J.M. and Rosendaal, F.R. (2009) The Venous Thrombotic Risk of Oral Contraceptives, Effects of Oestrogen Dose and Progestogen Type: Result of the MEGA Case-Control Study. *British Medical Journal*, 339, b2921.
18. Simioni, P., Sanson, B.J., Prandoni, P., Tormene, D., Friederich, P.W., Girolami, B., Gavasso, S., Huisman, M.V., Buller, H.R., Wouter ten Cate, J., Girolami, A. and Prins, M.H. (1999) Department of Medical and Surgical Sciences, University Hospital of Padua, Italy. Incidence of Venous Thromboembolism in Families with Inherited Thrombophilia. *Thrombosis and Haemostasis*, 81, 198-202. <https://doi.org/10.1055/s-0037-1614442>
19. Stegeman, B.H., de Bastos, M., Rosendaal, F.R., van Hylckama Vlieg, A., Helmerhorst, F.M., Stijnen, T. and Dekkers, O.M. (2013) Different Combined Oral Contraceptives and the Risk of Venous Thrombosis: Systematic Review and Network Meta-Analysis. *British Medical Journal*, 347, f5298. <https://doi.org/10.1136/bmj.f5298>
20. Lidegaard, J., Nielsen, L.H., Skovlund, C.W., Skjeldestad, F.E. and Løkkegaard, E. (2011) Risk of Venous Thromboembolism from Use of Oral Contraceptives Containing Different Progestogens and Oestrogen Doses: Danish Cohort Study, 2001-9. *British Medical Journal*, 343, d6423(1). <https://doi.org/10.1136/bmj.d6423>
21. Kuenen BC, Slee PH, Seldenrijk CA, Wagenaar SS. Intravenous leiomyomatosis complicated by Budd-Chiari syndrome. *Postgrad Med J*. 1996;72(853):686-8. <https://doi.org/10.1136/pgmj.72.853.686>
22. Parthipun AA, Taylor J, Manyonda I, Belli AM. Does size really matter? Analysis of the effect of large fibroids and uterine volumes on complication rates of uterine artery embolisation. *Cardiovasc Intervent Radiol*. 2010;33(5):955-9. <https://doi.org/10.1007/s00270-010-9842-x>
23. Grant PJ, Greene MT, Chopra V, Bernstein SJ, Hofer TP, Flanders SA. Assessing the Caprini Score for Risk Assessment of Venous Thromboembolism in Hospitalized Medical Patients. *Am J Med*. 2016;129(5):528-35. <https://doi.org/10.1016/j.amjmed.2015.10.027>
24. Caprini JA. Thrombosis risk assessment as a guide to quality patient care. *Dis Mon*. 2005 Feb-Mar;51(2-3):70-8. PMID: 15900257. <https://doi.org/10.1016/j.disamonth.2005.02.003>
25. Caprini JA. Risk assessment as a guide to thrombosis prophylaxis. *Curr Opin Pulm Med*. 2010 Sep;16(5):448-52. PMID: 20592595. <https://doi.org/10.1097/MCP.0b013e32833c3d3e>
26. Stroud W, Whitworth JM, Miklic M, Schneider KE, Finan MA, Scalici J, Reed E, Bazzett-Matabele L, Straughn JM Jr, Rocconi RP. Validation of a venous thromboembolism risk assessment model in gynecologic oncology. *Gynecol Oncol*. 2014 Jul;134(1):160-3. Epub 2014 May 4. PMID: 24796634. <https://doi.org/10.1016/j.ygyno.2014.04.051>
27. Cassidy MR, Rosenkranz P, McAneny D. Reducing postoperative venous thromboembolism complications with a standardized risk-stratified prophylaxis protocol and mobilization program. *J Am Coll Surg*. 2014 Jun;218(6):1095-104. Epub 2014 Mar 2. PMID: 24768293. <https://doi.org/10.1016/j.jamcollsurg.2013.12.061>
28. Tsaplin S, Schastlivtsev I, Zhuravlev S, Barinov V, Lobastov K, Caprini JA. The original and modified Caprini score equally predicts venous thromboembolism in COVID-19 patients. *J Vasc Surg Venous Lymphat Disord*. 2021 Nov;9(6):1371-1381. e4. Epub 2021 Mar 17. PMID: 33744497; PMCID: PMC7965848.
29. The COVID-19 Sub-Committee of the American Venous Forum Considerations in prophylaxis and treatment of VTE in COVID-19 patients; 2020. Available at: <https://www.veinforum.org/wp-content/uploads/2020/04/COVID-19-White-Paper-04-17-2020-FINAL-1.pdf>
30. Bartlett MA, Mauck KF, Stephenson CR, Ganesh R, Daniels PR. Perioperative Venous Thromboembolism Prophylaxis. *Mayo Clin Proc*. 2020 Dec;95(12):2775-2798. PMID: 33276846. <https://doi.org/10.1016/j.jmayocp.2020.06.015>
31. Yang SD, Liu H, Sun YP, Yang DL, Shen Y, Feng SQ, et al. Prevalence and risk factors of deep vein thrombosis in patients after spine surgery: a retrospective case-cohort study. *Sci Rep*. 2015; 5:11834. <https://doi.org/10.1038/srep11834>
32. Khorana AA, Francis CW, Blumberg N, Culakova E, Refaai MA, Lyman GH. Blood transfusions, thrombosis, and mortality in hospitalized patients with cancer. *Arch Intern Med*. 2008;168(21):2377-81. <https://doi.org/10.1001/archinte.168.21.2377>
33. Zander AL, Olson EJ, Van Gent JM, Bandle J, Calvo RY, Shackford SR, et al. Does resuscitation with plasma increase the risk of venous thromboembolism? *J Trauma Acute Care Surg*. 2015;78(1):39-43; discussion -4. <https://doi.org/10.1097/TA.0000000000000480>
34. Bates SM, Greer IA, Middeldorp S, Veenstra DL, Prabulos AM, Vandvik PO. VTE, thrombophilia, antithrombotic therapy, and pregnancy: Antithrombotic Therapy and Prevention of Thrombosis, 9th ed: American College of Chest Physicians Evidence-Based Clinical Practice Guidelines. *Chest*. 2012;141(2 Suppl):e691S-e736S. <https://doi.org/10.1378/chest.11-2300>
35. Plessier A, Darwish-Murad S, Hernandez-Guerra M, Consigny Y, Fabris F, Trebicka J, Heller J, Morard I, Lasser L, Langlet P, Denninger MH, Vidaud D, Condat B, Hadengue A, Primignani M, Garcia-Pagan JC, Janssen HL, Valla D; European Network for Vascular Disorders of the Liver (EN-Vie). Acute portal vein thrombosis unrelated to cirrhosis: a prospective multicenter follow-up study. *Hepatology*. 2010 Jan;51(1):210-8. PMID: 19821530. <https://doi.org/10.1002/hep.23259>
36. Delgado MG, Seijo S, Yepes I, Achécar L, Catalina MV, García-Criado A, Abralde JG, de la Peña J, Bañares R, Albillos A, Bosch J, García-Pagán JC. Efficacy and safety of anticoagulation on patients with cirrhosis and portal vein thrombosis. *Clin Gastroenterol Hepatol*. 2012 Jul;10(7):776-83. Epub 2012 Jan 28. PMID: 22289875. <https://doi.org/10.1016/j.cgh.2012.01.012>
37. Chen H, Turon F, Hernández-Gea V, Fuster J, Garcia-Criado A, Barrufet M, Darnell A, Fondevila C, Garcia-Valdecasas JC, Garcia-Pagán JC. Nontumoral portal vein thrombosis in patients awaiting liver transplantation. *Liver Transpl*. 2016 Mar;22(3):352-65. PMID: 26684272. <https://doi.org/10.1002/lt.24387>
38. Young K, Wong R. Evaluation and management of acute and chronic portal vein thrombosis in patients with cirrhosis. *Clin Liver Dis (Hoboken)*. 2018;10(6):152-156. Published 2018 Jan 2. <https://doi.org/10.1002/cld.679>
39. Cui SB, Shu RH, Yan SP, Wu H, Chen Y, Wang L, Zhu Q. Efficacy and safety of anticoagulation therapy with different doses of enoxaparin for portal vein thrombosis in cirrhotic patients with hepatitis B. *Eur J Gastroenterol Hepatol*. 2015 Aug;27(8):914-9. PMID: 25856686. <https://doi.org/10.1097/MEG.0000000000000351>