

Rhino-Sino-Cerebral Mucormycosis Associated with Long-Term Rituximab Therapy in Multiple Sclerosis: A Case Report and Review of the Literature



Mohsen Koosha ¹, Golfam Mehrparvar ², Sepideh Paybast ^{3*}

1. Neurosurgery Department, Imam Hossein Hospital, Shahid Beheshti University of Medical Sciences, Tehran, Iran.
2. Neurosurgery Department, Imam Hossein Hospital, Shahid Beheshti University of Medical Sciences, Tehran, Iran.
3. Multiple Sclerosis Research Center, Neuroscience Institute, Tehran University of Medical Sciences, Tehran, Iran.



Citation Koosha M, Mehrparvar G, Paybast S. Rhino-Sino-Cerebral Mucormycosis Associated with Long-Term Rituximab Therapy in Multiple Sclerosis: A Case Report and Review of the Literature. *Case Reports in Clinical Practice*. 2022; 7(6): 313-318.

Running Title Mucormycosis and Rituximab



Article info:

Received: November 4, 2022
Revised: November 20, 2022
Accepted: December 25, 2022

Keywords:

Multiple sclerosis; Rituximab;
 B-Lymphocytes; Mucormycosis

ABSTRACT

Rituximab is a CD20 depleting agent, widely used as an off-label disease-modifying treatment (DMT) in treating multiple sclerosis (MS). The present study aimed to report the first case of rhino-sino-cerebral mucormycosis in a patient with secondary progressive MS (SPMS), treated with rituximab. The patient was a 38-year-old man with a history of SPMS treated with rituximab, who developed subacute left vision loss and impaired ocular movement. He also mentioned a concomitant severe headache and cheek swelling. Based on the brain and orbital magnetic resonance imaging (MRI) findings, rhino-sino-cerebral mucormycosis was suspected. Subsequent endoscopic examination confirmed the diagnosis. He underwent medical treatment with amphotericin B liposomal and surgical debridement leading to a significant clinical recovery. He was eventually discharged home with a solid recommendation to discontinue rituximab. The present report indicates a case of SPMS treated with rituximab, who developed rhino-sino-cerebral mucormycosis.

Introduction

Multiple sclerosis (MS) is an inflammatory and neurodegenerative demyelinating disease of the central nervous system (CNS). It mainly affects young adults, with more than 2.5 million people worldwide [1]. Rituximab, a human-murine chimeric monoclonal B cell depleting agent, is widely used as an off-label disease-

modifying disease treatment (DMT) in the treatment of all subtypes of MS [2,3]. The most common side effect of rituximab is a mild to moderate infusion reaction, which occurs mainly at the time of the first infusion. However, the main concern in the long-term treatment with rituximab is the increased risk of infection, including respiratory and urinary tract infections [4]. Decreased B-cell secreted cytokines as B-cell activating factor or interleukin 6, leading to hypogammaglobinemia along with impaired B-cell

* Corresponding Author:

Sepideh Paybast

Address: Multiple Sclerosis Research Center, Neuroscience Institute, Tehran University of Medical Sciences, Tehran, Iran.

E-mail: sepideh.paybast@yahoo.com



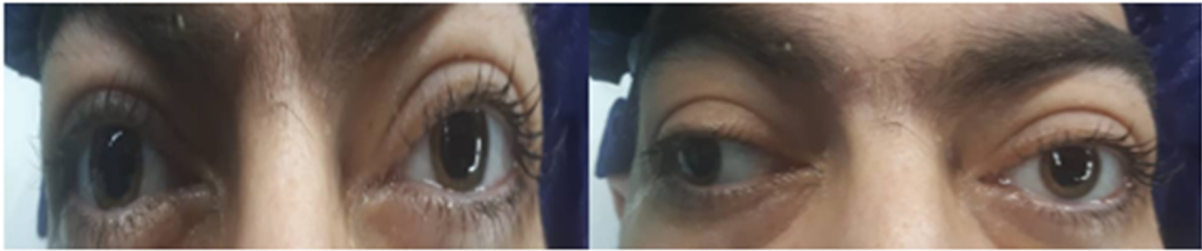

Fig. 1. Severely limited ocular movements in all gaze directions (frozen eye) in the left eye.

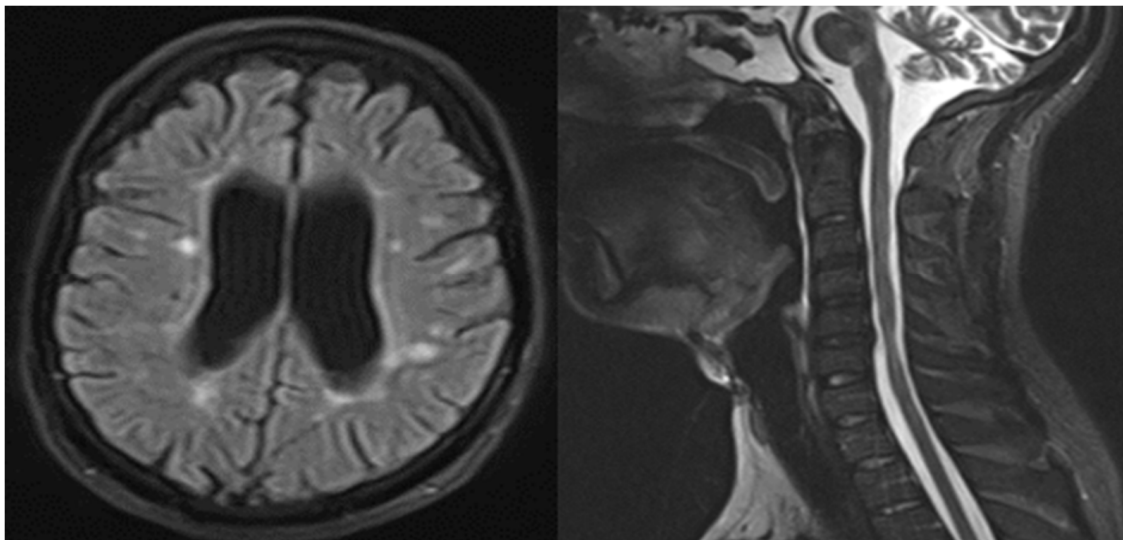


Fig. 2. Rt: Multiple small posterolateral lower cervical, pontine, and medulla hyper-intense lesions in T2 sagittal image, Lt: multiple ovoid periventricular, subcortical, and juxtacortical hyper-intense lesions in FLAIR axial image.

differentiation are considered to be the most crucial risk factors for rituximab-associated infection [4,5].

There are few reports of reactivation of the John Cunningham virus (JCV), human immunodeficiency virus (HIV), tuberculosis, and hepatitis upon rituximab treatment in the literature [4–6]. However, to the best of our knowledge, there is no report of rhino-sino-cerebral mucormycosis associated with rituximab treatment in the MS population.

It is noteworthy that mucormycosis is an extremely rare and life-threatening fungal infection, which mainly affects patients with uncontrolled diabetes mellitus (DM), who are on hemodialysis, high-dose corticosteroids or immunosuppressive, or severely traumatic [7].

Regarding this infection's rarity and destructive nature, we aimed to report the first case of rhino-sino-cerebral mucormycosis in a patient with secondary progressive MS (SPMS), treated with rituximab.

Case presentation

Clinical presentation

The patient was a 38-year-old man admitted to our emergency department with a history of reduced visual acuity, impaired ocular movement, left nasal obstruction, and left cheek swelling associated with refractory headache, all of which had progressed for two months. He reported no history of fever, flu-like symptoms, or trauma. His medical history was notable for previously diagnosed untreated relapse remitting MS (RRMS), which evolved to SPMS 3 years ago. Given the relatively rapid progression of the disease, rituximab was implemented two years ago. The patient initially received regular rituximab infusions (500 mg) every six months. However, after severe COVID-19 infection, treatment intervals were individualized based on CD19+ B-cell monitoring. The last infusion was instituted three months before admission. His COVID-19 vaccination was negative. Moreover, a year ago, following a fall and a vertebral

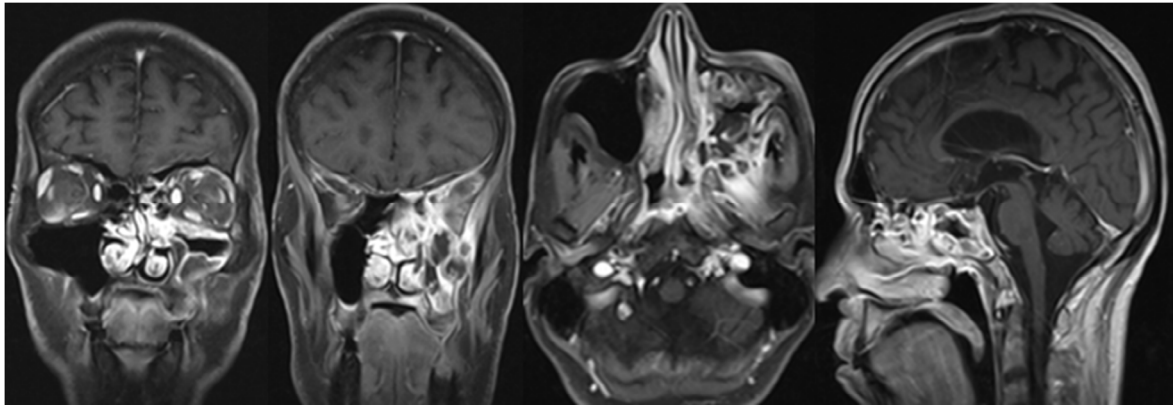


Fig. 3. Evidence of significant opacities in the paranasal sinuses, more prominent in the posterior ethmoidal and sphenoidal sinuses on the left side, extending to the posterior orbital space in all sequences (two left: coronal, middle: axial, right: sagittal)

fracture, he was walker dependent with an Expanded Disability Status Scale (EDSS) of 6.5. He had no other chronic disease and had a negative drug history other than fampridine (10 mg twice daily).

On examination, the patient was alert and conscious. His vital signs revealed a body temperature of 37.1°C, blood pressure of 125/85 mm Hg, respiratory rate of 14 bpm, pulse rate of 72 beats/min, and oxygen saturation of 99%. The systemic examination was unremarkable. The ocular examination disclosed mild left proptosis, reduced visual acuity (4/10) on the left side, and fixed and dilated the left pupil. No papilledema was evident. Ocular movements were severely limited in all gaze directions in the left eye (Figure 1).

Moreover, there was a purulent discharge coming from the left nostril. Other neurological examinations were notable for lower limbs paresis (3/5 regarding the medical research council (MRC) score), generalized hyperreflexia, and bilateral up plantar reflexes.

Investigation and treatment

The laboratory examination revealed leukocytosis (leukocyte count of $18,700 \times 10^3/mm^3$), erythrocyte sedimentation rate (ESR) of 75 ml, C-reactive protein (CRP) of 63 mg/dl, blood sugar of 156 mg/dl, Immunoglobulin G (IgG) level of 714 mg/dl, and marked loss of CD19+ cells (< 0.1%). Other laboratory tests and chest computed tomography (CT) were within normal limits. Regarding the current outbreak of COVID-19, the polymerase chain reaction (PCR) assay of the throat swab sample was also done, which was negative for severe acute respiratory syndrome coronavirus 2 (SARS-CoV-2).

Brain and cervical magnetic resonance imaging (MRI) demonstrated multiple non-enhancing supratentorial, infratentorial, and cervical demyelinating plaques associated with generalized atrophy, consistent with his previous MRI (Figure 2).

Furthermore, the opacifications of paranasal sinuses were observed, which were more prominent in the posterior ethmoidal and sphenoidal sinuses on the left side, invading the posterior orbital space (Figure 3).

With suspicion of rhino-orbital mucormycosis, systemic antibiotics and antifungals were started, including intravenous meropenem, vancomycin, and amphotericin B liposomal (Ambisome Gilead Co.) (5 mg/kg daily). Then, he underwent endoscopic examination, where blackish necrotic tissues were observed. Subsequently, the patient underwent paranasal sinuses debridement followed by surgical debridement. We performed left temporal craniotomy and sub-temporal extradural approach to the middle cranial fossa to access the abscess formation and necrotic tissues. After evacuating the abscess from the medial parts of the middle fossa, a route was founded to the sphenoid sinus mucosa due to the destruction of the lateral wall of the sphenoid sinus related to fungal invasion. Successively, the inflamed mucosa was exenterated, and the specimens obtained from the sinuses were sent to the pathology laboratory. Examination of the results with hematoxylin and eosin (H&E) staining and direct experiment with 10% potassium hydroxide (KOH) showed irregular, wide, and non-septate hyphae along with the areas of necrosis (Figure 4).

The headache and nasal discharge were dramatically

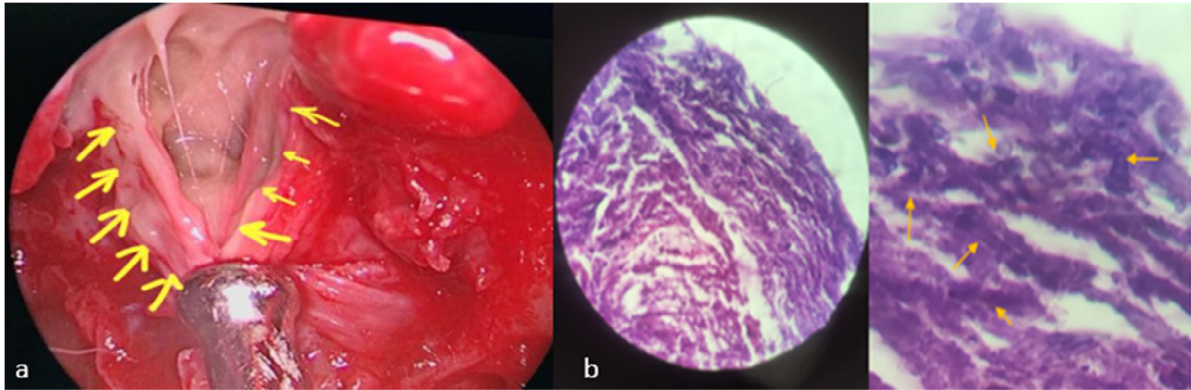


Fig. 4. a) a defect from the sphenoid roof to the skull base in the ethmoidal fovea (yellow flashes), **b)** evidence of typical aseptate, wide fungal hyphae (yellow flashes) along with areas of necrosis, epithelioid cell granulomas, multinucleated giant cells, and chronic inflammatory cell infiltrate in H&E staining with direct experiment with 10% potassium hydroxide (KOH)

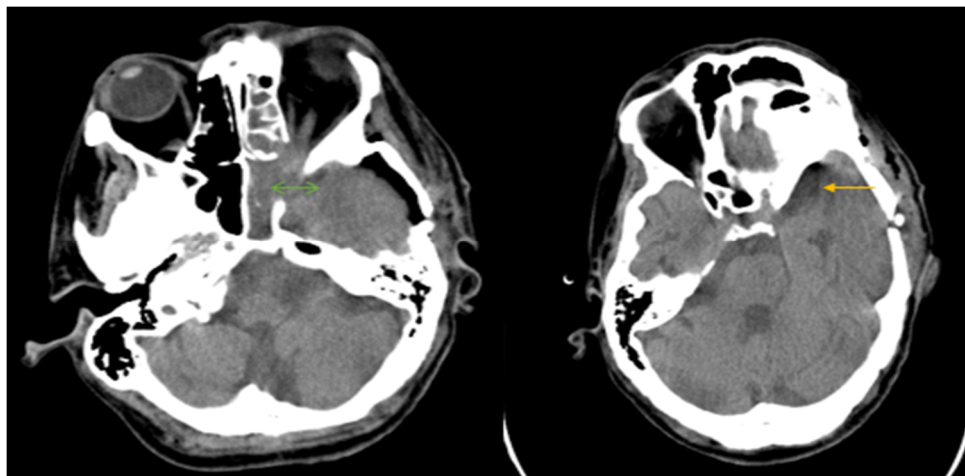


Fig. 5. Rt: Evidence of the abscess removal in post-op brain CT imaging (yellow flash), **Lt:** the route between the sphenoid and posterior ethmoidal sinuses due to the fungal invasion (green flash)

resolved after the surgery. The post-op brain CT revealed the complete removal of the abscess (Figure 5).

Liposomal amphotericin B was continued for 21 days. The inflammatory markers gradually decreased with a leukocyte count of $7200 \times 10^3/10^3/mm^3$, ESR of 15 ml, and CRP of 5 mg/dl at discharge. After a month, he was left with vision loss and impaired ocular mobility. He was eventually discharged home to complete his therapy course of bone tissue regeneration. In addition, he was strongly recommended to discontinue rituximab with a close clinical and imaging follow-up under the supervision of his MS specialist.

Discussion

This report provides the occurrence of rhino-sino-cerebral mucormycosis in a patient treated with rituximab for SPMS.

Rituximab, a monoclonal antibody targeting CD20, selectively allows the depletion of the circulating B-cell population, apart from the mature antibody-secreting plasma cells for a long-lasting period of 6-12 months. Since the introduction of rituximab in the treatment of lymphoma in 1997, it has been widely used in other hematologic and immune-mediated disorders, of which MS is of paramount importance [3,4]. However, many studies have shown an increased risk of infection with rituximab, particularly for those depending on humoral immunity, ranging from 2.2 to 9.8 person-years [2]. Similarly, in the MS population, a higher rate of serious infections (4.5%) was demonstrated in patients treated with rituximab, with no clear association to the number of infusions [8]. In light of previous evidence, the reactivation of viral infections, tuberculosis, severe COVID-19, and lower response to COVID-19 vaccination have been shown in association with rituximab in MS patients [4-6].

To the best of our knowledge, there are only a few reports of rituximab-associated mucormycosis in the literature, all of which occurred in immunocompromised patients with concomitant use of other immunosuppressive therapies. The majority of the patients reported pulmonary mucormycosis with a poor prognosis [9–12]. However, in the case we described, the patient was a case of SPMS who was; otherwise, healthy and had no underlying risk factors other than treatment with rituximab. Another unique aspect of our patient was that he responded dramatically to the treatment despite the extensive fungal invasion and was discharged in a good general condition. The favorable outcome in our patient could be attributed to his relatively intact immune system, normal levels of IgG and blood cells, stable hemodynamic variables at the time of referral, and timely diagnosis and treatment.

Notably, mucormycosis is an extremely rare fungal infection, ranging from 0.005 to 1.7 per million. It occurs most frequently in patients with DM, hematologic malignancies, organ transplants, and patients receiving immunosuppressive medications. The disease mainly takes the form of rhino-orbitocerebral involvement with a highly aggressive clinical course and an average mortality rate of 50% [7,13].

With all considerations in mind, the present report indicates a rare and potentially life-threatening fungal infection in an SPMS patient treated with rituximab. Although our data do not confirm a causal relationship between rituximab and mucormycosis, it highlights the importance of rapid and accurate diagnostic tests in suspicion of rare opportunistic infection in patients receiving rituximab. Moreover, in line with previous reports, our report supports a difference between the first and second-line DMTs regarding infection risks.

Conclusion

The present case report describes a rare and potentially life-threatening fungal infection (rhino-sino-cerebral mucormycosis) in an SPMS patient treated with rituximab. Although our finding does not draw a strong association between mucormycosis and rituximab, it highlights the need to evaluate the new neurological symptoms in patients treated with rituximab.

Ethical Considerations

Compliance with ethical guidelines

There were no ethical considerations to be considered in this article.

Funding

This research received no external funding.

Conflict of Interests

The authors declare that they have no conflict of interests, and no funding has been used for the manuscript.

Ethical Statement

Informed consent was obtained from the patients for publication of this report

Acknowledgments

The authors declare that they have no acknowledgment state.

References

1. Wiendl H, Gold R, Berger T, Derfuss T, Linker R, Mäurer M, et al. Multiple Sclerosis Therapy Consensus Group (MSTCG): position statement on disease-modifying therapies for multiple sclerosis (white paper). *Ther Adv Neurol Disord* [Internet]. 2021 Jan 18;14:175628642110396. Available from: <http://journals.sagepub.com/doi/10.1177/17562864211039648>
2. Varley CD, Winthrop KL. Long-Term Safety of Rituximab (Risks of Viral and Opportunistic Infections). *Curr Rheumatol Rep* [Internet]. 2021 Sep 16;23(9):74. Available from: <https://link.springer.com/10.1007/s11926-021-01037-3>
3. Vikse J, Jonsdottir K, Kvaløy JT, Wildhagen K, Omdal R. Tolerability and safety of long-term rituximab treatment in systemic inflammatory and autoimmune diseases. *Rheumatol Int* [Internet]. 2019 Jun 28;39(6):1083–90. Available from: <http://link.springer.com/10.1007/s00296-019-04272-1>
4. Ineichen B V, Moridi T, Granberg T, Piehl F. Rituximab treatment for multiple sclerosis. *Mult Scler J* [Internet]. 2020 Feb 25;26(2):137–52. Available from: <http://journals.sagepub.com/doi/10.1177/1352458519858604>
5. Barmettler S, Ong MS, Farmer JR, Choi H, Walter J. Association of Immunoglobulin Levels, Infectious Risk, and Mortality With Rituximab and Hypogammaglobulinemia. *JAMA Netw Open* [Internet]. 2018 Nov 2;1(7):e184169. Available from: <http://jamanetworkopen.jamanetwork.com/article.aspx?doi=10.1001/jamanetworkopen.2018.4169>
6. Tian X, Chen C, Ma L, Wei R, Li M, Wang X, et al. Efficacy and safety of rituximab in relapsing-remitting multiple sclerosis: A systematic review and meta-analysis. *J Neuroimmunol* [Internet]. 2020 Oct;347:577317. Available from: <https://linkinghub.elsevier.com/retrieve/pii/S016557282030326X>
7. Petrikos G, Skiada A, Lortholary O, Roilides E, Walsh TJ, Kontoyiannis DP. Epidemiology and Clinical Manifestations of Mucormycosis. *Clin Infect Dis* [Internet]. 2012 Feb 1;54(suppl_1):S23–34 Available from: http://academic.oup.com/cid/article/54/suppl_1/S23/284492/Epidemiology-and-Clinical-Manifestations-of

8. Chisari CG, Sgarlata E, Arena S, Toscano S, Luca M, Patti F. Rituximab for the treatment of multiple sclerosis: a review. *J Neurol* [Internet]. 2022 Jan 8;269(1):159–83. Available from: <https://link.springer.com/10.1007/s00415-020-10362-z>
9. Mir I, Basnet S, Ellsworth D, Mohanty E. Pulmonary Mucormycosis in Chronic Lymphocytic Leukemia and Neutropenia. *Case Rep Infect Dis* [Internet]. 2018;2018:1–4. Available from: <https://www.hindawi.com/journals/criid/2018/2658083/>
10. Hill M, Pennington K, Midthun D. Pulmonary Mucormycosis: A Rare Cause of Hydropneumothorax. *Chest* [Internet]. 2020 Oct;158(4):A479. Available from: <https://linkinghub.elsevier.com/retrieve/pii/S0012369220326465>
11. Hung HC, Shen GY, Chen SC, Yeo KJ, Tsao SM, Lee MC, et al. Pulmonary Mucormycosis in a Patient with Systemic Lupus Erythematosus: A Diagnostic and Treatment Challenge. *Case Rep Infect Dis* [Internet]. 2015;2015:1–5. Available from: <http://www.hindawi.com/journals/criid/2015/478789/>
12. Nandwani A, Jha P, Duggal R, Kher V. Invasive gastric mucormycosis and cytomegalovirus infection in an ABO incompatible renal transplant recipient. *Indian J Nephrol* [Internet]. 2015;25(6):373. Available from: <http://www.indianjephrol.org/text.asp?2015/25/6/373/157428>
13. Kontoyiannis DP, Yang H, Song J, Kelkar SS, Yang X, Azie N, et al. Prevalence, clinical and economic burden of mucormycosis-related hospitalizations in the United States: a retrospective study. *BMC Infect Dis* [Internet]. 2016 Dec 1;16(1):730. Available from: <http://bmcinfectdis.biomedcentral.com/articles/10.1186/s12879-016-2023-z>