

Anterior Wall of Maxillary Sinus As a New Autogenic Graft Source: A Case Report



Arash Tahmasebi¹, Seyed Hadi Hoseini¹, Donya Maleki^{2*}

1. Department of Oral and Maxillofacial Surgery, Faculty of Dentistry, Guilan University of Medical Sciences, Rasht, Iran

2. Student Research Committee, Faculty of Dentistry, Guilan University of Medical Sciences, Rasht, Iran

Use your device to scan and read the article online



Citation Tahmasebi A, Hoseini SH, Maleki D. Anterior Wall of Maxillary Sinus As a New Autogenic Graft Source: A Case Report. Case Reports in Clinical Practice. 2023; 8(4): 135-138.

Running Title Autograft from Maxillary Sinus



Article info:

Received: July 9, 2023

Revised: July 15, 2023

Accepted: August 13, 2023

Keywords:

Autograft; Case report; Dental implant; Maxillary sinus

ABSTRACT

This study introduces the anterior wall of the maxillary sinus as a viable and accessible graft site for small to moderate bone defects in the maxilla that pose challenges for implantation. A healthy 40-year-old woman was referred by a prosthodontist due to malpositioned implants. Following a comprehensive assessment, the decision was made to remove the implants. Upon executing this treatment plan, a medium-sized defect was revealed. The flap was elevated to expose the anterior wall of the maxillary antrum, from which an osseous graft was obtained. This graft was then fixed as a buccal wall of the defect and supported by a membrane. After a healing period of 6 months, two implants were successfully inserted. The anterior wall of the maxillary sinus can serve as a beneficial graft source. However, more extensive studies with appropriate design are required to reach a definitive conclusion.

Introduction

The selection of ideal locality for placement of oral implants based on the prosthetic treatment plan is still facing complexity, because reconstruction of different size bone defects, especially in cases of aggressive and unshapen bone loss, is making the implantations egress from its routine process-driven surgeons to venturing themselves so that they can achieve convenient results [1-4]. Comprehensive surgical methods such

as “split-ridge”, distraction osteogenesis (DO), and various grafts [1] have been introduced to overcome these convolutions, but there are still some cases that need ingenious approaches. In the following reports, an inventive method will be represented, in which benefits can be obtained from the anterior wall of the maxillary sinus as one of the less attention-paid sources.

Case report

A 40-year-old female patient was a case of

* Corresponding Author:

Donya Maleki

Address: Student Research Committee, Faculty of Dentistry, Guilan University of Medical Sciences, Rasht, Iran

E-mail: donyamaleki93@gmail.com

repositioning of two malpositioned implants replaced for left maxillary lateral incisor and canine according to prosthodontist opinion (Figure 1). The clinical and radiographic evaluation confirmed that in spite of acceptable osseointegration, the incorrect orientation of implants would not allow a functional prosthesis, so “leave to sleep” the implants were ruled out. As the integration type of implants was used, the chance of redirection was very low. Eventually, the removal of implants was suggested. The surgical process was discussed with the patient and the advantages of the graft provided from the anterior wall of the maxillary sinus were explained. Also, written consent was obtained. The routine presurgical test was prescribed to determine the patient health conditions. Under local anesthesia (Lidocaine 1:100 000 Epinephrine), a buccally full-thickness trapezoidal mucoperiosteal flap (with releasing incisions in the mesial of canine and distal of the first molar) was uplifted with periosteal elevator while the periosteum was intact. The implants were explanted by trephine bur (size 5) under adequate irrigation. A medium-sized cavity emerged. The flap was extended to access the anterior wall of the maxillary sinus. The required size of bone (12*8 mm²) was marked and the graft was separated using a piezoelectric device with regard to preserving the Schneiderian membrane (Figure 2). The prepared block graft was fixed by a screw so that it could provide a buccal wall for the present defect (Figure 3). Allograft powder (Iran, Kish Company, MBA/5-/3 mm) covered by the collagen membrane (Iran, Kish

Company) was used to accelerate the healing process. Following the irrigation of the site with normal saline, the flap was reapproximated and sutured by 4/0 Vicryl suture. The post-operative considerations were noted scrupulously. The sutures were removed 10 days later and after 6 months the area was reopened and the proportion of healing was assessed. The inserted graft was well-integrated. So, the screw was removed and the implants were placed as planned and the patient was referred to a prosthodontist to receive rehabilitation treatment. The patient was satisfied with the results.

Discussion

To achieve appropriate functional and esthetic outcomes in patients with osseous undercuts and defects undergoing implantation, different methods have been recommended such as bone reconstruction using grafts [3, 4]. To provide the graft, different sources are available, but which one has the most benefit in cases familiar to the reported situation in this article?

In comparison with allograft, xenograft, and alloplastic substances, it is obvious that the valency of induction and formation of autograft osseous as well as immune compatibility makes it the material of choice with more than 95% success rate [1-4]. Without a doubt, the reported confinements of allografts such as the restricted amount of gained bone, few suitable donor areas, and post-operation complications cannot be ignored [4].

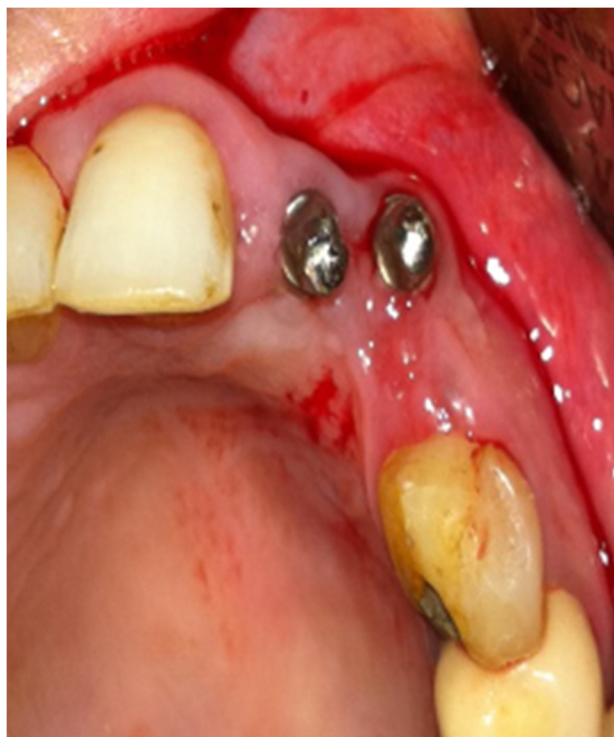

Fig. 1. The malpositioned implants replaced for left maxillary lateral incisor and canine.

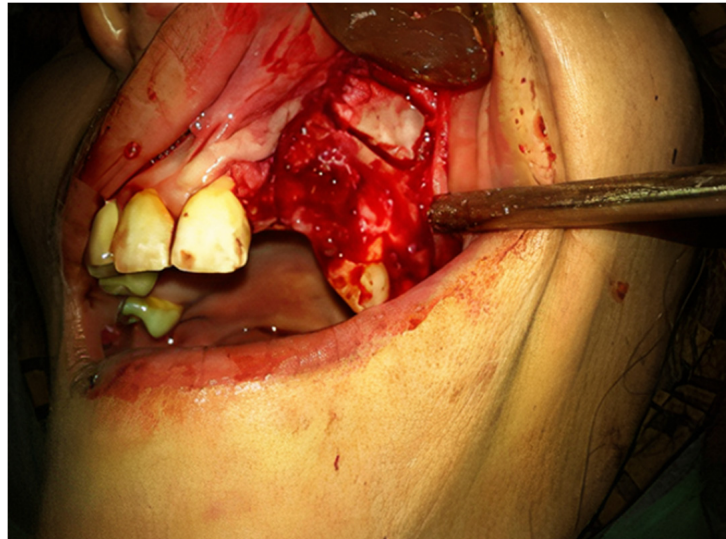


Fig. 2. The auto-graft provided from the anterior wall of the maxillary sinus.

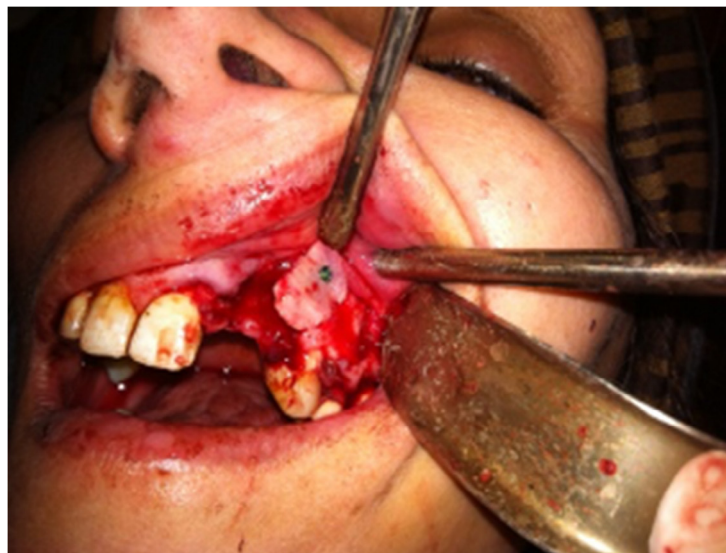

Fig. 3. The prepared block graft fixed by a screw as the buccal wall of the defect.

Optional autogenic donor location was divided into extraoral (cranial vault – iliac crest) and intraoral ones [3] which are chosen based on defects size and kind, rate of progress, and patient statements.[3, 4] Sakkas reported intraoral graft surgery was more acceptable for patients as one surgery was enough to transfer the graft from the donor site to the recipient site with fewer side effects while extraoral graft surgery generally is accompanied by unpredictable resorption[4]. It is notable to mention Faverani who favored the extraoral cranial vault graft believing it would not cause serious complaints unlike iliac crest graft but the needed expertness was the only matter. [3] Consequently, extraoral harvesting is avoided unless a great amount of graft is required [4].

Intraoral grafts were divided into the maxillary and mandibular sites. Mandibular sites consist of the mental region (symphysis), retromolar area/external oblique ridge, and ramus of the mandible [3].

As for the mental region, Raghoobar and Faverani proposed the contestation of technique sensitivity, high risk of morbidity, and widespread intensive care [3, 5].

Damaging the branches of the inferior alveolar nerve, especially the lingual nerve, was a major concern while using the retromolar area in accord with what Raghoobar reported [5]. Maxillary sites include tuberosity of the maxilla, palate, zygomatic alveolar buttress, and anterior maxillary sinus wall. Stübinger

believed these sites were better than the mandibular sites for the maxillary implantation's complexity since the recipient and donor spots were conterminous and a single surgery was done [6].

The graft obtained from tuberosity had a fragile state, structure, and consistency based on Reininger's article [7] confirmed by Veis et al. [8] Veis et al informed that the bone level did not develop well by the tuberosity graft [8]. Reininger reviewed that palate was hardly approachable and puncturing to the nasal cavity was possible [7]. The procedure performed to have the zygomatic body graft could cause permanent trauma of the infraorbital nerve which was not justifiable relative to the small content of the graft possessed [3, 7, 9]. The anterior wall of the maxillary sinus was an ideal option for small to moderate osseous defects and the required amount is almost 0.4 to 1.2 ml [10]. Not only did it have minimum bone resorption, but also the proximity of sites made the surgical duration shorter and post-operative morbidity fewer based on 4 articles mentioned on Reininger's research [7]. The possibility of Schneiderian membrane perforation was a conceivable complication of harvesting of maxillary antrum walls which could be avoided by using a piezoelectric device [7].

It is worth noting that graft of the anterior wall of the maxillary sinus was a "promising approach" for the reconstruction of small to moderate defects of the orbital floor suggested by Emodi [11] and Bande [12]. In the end, this article wants to offer the anterior wall of the maxillary sinus as a less paid attention but worthy source of graft in cases of maxillary bone reconstruction, though the selection of the suitable source of graft depends on the surgeon's preference and patient benefits.

Ethical Considerations

Compliance with ethical guidelines

There were no ethical considerations to be considered in this article.

Funding

No funding was received to assist with the preparation of this manuscript.

Conflict of Interests

The authors have no conflict of interest to declare.

References

- [1] D'Amato S, Itro A, Santagata M. Mandibular bone regeneration after bone slat technique. *Ann Stomatol (Roma)*. 2017;8(1):39-44. <https://doi.org/10.11138/ads/2017.8.1.039>
- [2] Wang D, Tabassum A, Wu G, Deng L, Wismeijer D, Liu Y. Bone regeneration in critical-sized bone defect enhanced by introducing osteoinductivity to biphasic calcium phosphate granules. *Clin Oral Implants Res*. 2017;28(3):251-60. <https://doi.org/10.1111/clr.12791>
- [3] Faverani LP, Ramalho-Ferreira G, Santos PHD, Rocha EP, Garcia Júnior IR, Pastori CM, et al. Surgical techniques for maxillary bone grafting - literature review. *Rev Col Bras Cir*. 2014;41:61-7. <https://doi.org/10.1590/S0100-69912014000100012>
- [4] Sakkas A, Wilde F, Heufelder M, Winter K, Schramm A. Autogenous bone grafts in oral implantology-is it still a "gold standard"? A consecutive review of 279 patients with 456 clinical procedures. *Int J Implant Dent*. 2017;3(1):23. <https://doi.org/10.1186/s40729-017-0084-4>
- [5] Raghoobar GM, Timmenga NM, Reintsema H, Stegenga B, Vissink A. Maxillary bone grafting form insertion of endosseous implants: results after 12-124 months. *Clin Oral Implants Res*. 2001;12(3):279-86. <https://doi.org/10.1034/j.1600-0501.2001.012003279.x>
- [6] Stübinger S, Robertson A, Zimmerer KS, Leiggenger C, Sader R, Kunz C. Piezoelectric harvesting of an autogenous bone graft from the zygomaticomaxillary region: case report. *Int J Periodontics Restorative Dent*. 2006;26(5):453-7. [Link](#)
- [7] Reininger D, Cobo-Vázquez C, Rosenberg B, López- Quiles J. Alternative intraoral donor sites to the chin and mandibular body-ramus. *J Clin Exp Dent*. 2017;9(12):e1474. <https://doi.org/10.4317/jced.54372>
- [8] Veis AA, Tsirlis AT, Parisis NA. Effect of autogenous harvest site location on the outcome of ridge augmentation for implant dehiscences. *Int J Periodontics Restorative Dent*. 2004;24(2):154-63. [Link](#)
- [9] Abdi I, Maleki D. Anterior Mandibular Composite Graft for Regeneration of Knife-Edge Ridges in Implant Surgery: A Treatment Case Report. *Front Dent*. 2020;17(10):1-5. <https://doi.org/10.18502/fid.v17i1.3968>
- [10] Abdi I, Maleki D, Maleki D. A review of advantages and disadvantages of different intraoral and extraoral autogenic osseous grafts in the reconstruction of bony defects. *J Dentomaxillofac Radiol Pathol Surg*. 2019;8(1&2):53-5.
- [11] Emodi D, Nseir S, Shilo D, Srouji H, Rachmiel A. Antral Wall Approach for Reconstruction of Orbital Floor Fractures Using Anterior Maxillary Sinus Bone Grafts. *J Craniofac Surg*. 2018;29(4):e421-6. <https://doi.org/10.1097/SCS.00000000000004454>
- [12] Bande CR, Daware S, Lambade P, Patle B. Reconstruction of orbital floor fractures with autogenous bone graft application from anterior wall of maxillary sinus: a retrospective study. *J Maxillofac Oral Surg*. 2015;14(3):605-10. <https://doi.org/10.1007/s12663-014-0716-7>