



## Leiomyoma of the Spermatic Cord in a 26-Year-Old Man

Habib Tavassoli<sup>1</sup>, Farzin Valizadeh<sup>2</sup>, Ali Samady<sup>3</sup>

1- Department of Pathology, Alavi Hospital, School of Medicine, Ardabil University of Medical Sciences, Ardabil, Iran

2- Department of Urology, Alavi Hospital, School of Medicine, Ardabil University of Medical Sciences, Ardabil, Iran

3- School of Medicine, Ardabil University of Medical Sciences, Ardabil, Iran

Received: 22 September 2016

Revised: 2 October 2016

Accepted: 31 October 2016

### ARTICLE INFO

Corresponding author:  
Ali Samady

Email:  
[alisamady89@yahoo.com](mailto:alisamady89@yahoo.com)

Keywords:  
Leiomyoma;  
Spermatic cord;  
Scrotum

### ABSTRACT

Leiomyomas are benign tumors originating from smooth muscles. Uterus is the common site they are originated. However, genitourinary leiomyomas are the least common type of non-uterine types. We are reporting a case of right-side scrotal spermatic cord leiomyoma in a 26-year-old man presenting as a painless mass. According to the ultrasonography report as an extratesticular mass, he underwent trans-inguinal tumor resection surgery. A well-defined creamy-white ovoid mass with whorling cut surface which was tightened to the posterior of the cord was resected and then sent to pathology service where histologically the diagnosis of leiomyoma was made. Leiomyoma, having concerned its rarity, can be a possible differential diagnosis of extratesticular masses

**Citation:** Tavassoli H, Valizadeh F, Samady A. **Leiomyoma of the Spermatic Cord in a 26-Year-Old Man.** Case Rep Clin Pract 2016; 1(4): 96-8.

### Introduction

Leiomyomata found in male genital tract are of extremely rare occurrences. However, these benign smooth muscle tumors represent the most common tumor in women (1), and supposed that they can arise from any other organs consist of smooth muscle. A few non-uterine cases as in renal capsule, renal pelvis, and bladder and also rare cases of epididymis, prostate, scrotum, glans penis, testis, and the kidney have been

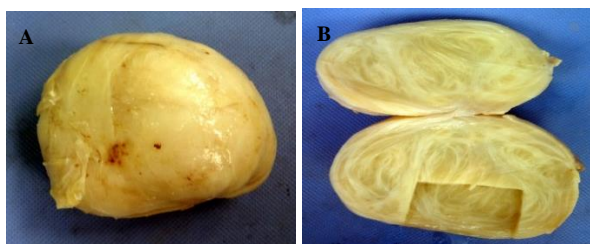
reported (2). Here, we are reporting a case of leiomyoma of the spermatic cord inside the scrotal sac diagnosed as an extratesticular mass in ultrasonography with the concern for the presence of a testicular neoplasm.

### Case Report

A 26-year-old man with a complaint of mass sensation in his right-side scrotum was referred from the urologist's office to Alavi hospital, Ardabil City, Iran. Physical

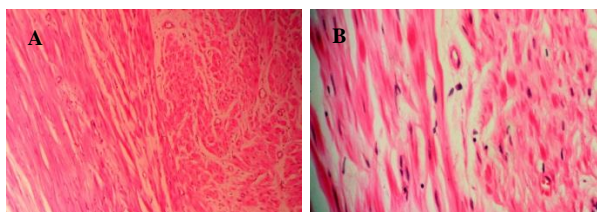
examination validated the presence of the mass. Ultrasonography revealed a heterogeneous mass without any distinct borders with diameters of  $70 \times 50$  mm drawing the right testicle down which was not showing obvious changings during Valsalva maneuver. There were also some dilated veins with diameters of 2-3.5 mm little expanding during Valsalva maneuver at his left testis proposing grade-one to -two varicocele.

However, there were not evidences of benign prostatic hyperplasia (BPH), hydrocele or any other diseases. Having proposed lipoma or liposarcoma due to ultrasonography report, the patient went under trans-inguinal excision of tumor operation. The mass was firm, well-defined, and tightened to the posterior of the cord (Figure 1, A and B).



**Figure 1.** Macroscopic appearance of the creamy-white tumor; its surface and whorling cut section pathognomic for leiomyoma (A and B)

The mass and its capsule were removed and then sent to pathology service. On pathologic evaluation, the main piece macroscopically was creamy-white ovoid tissue with well-defined borders measuring  $6.5 \times 5.5 \times 5.0$  mm, with cutting surface of the same color, whorly appearance, and rubbery consistency considering leiomyoma in histopathology study (Figure 2).



**Figure 2.** Histopathologic view of the tumor composed of interlacing fascicles of spindled smooth muscles (A: hematoxylin-eosin, objective  $\times 400$ ; B: hematoxylin-eosin, objective  $\times 1000$ )

The patient returned home two days after surgery with no further problems.

## Discussion

Leiomyomas appear to be one of the rarest paratesticular (extratesticular) tumors, small groups of neoplasms arising from the structures outer the testis. Paratesticular tumors are mostly benign tumors and only require intervention if they become massive or cause pain. Their tendency for malignancy is of a lower rate than that seen with solid intratesticular tumors with the rate of 90-95 percent (3). Adenomatoid tumors are included in the most common solid paratesticular masses, representing 30% of these lesions (4). Papillary cystadenomas and leiomyomas account for most of the other benign epididymal solid tumors (5). Leiomyomas can also be bilateral and may accompany a hydrocele or hernia (6). Leiomyomas may be categorized into the following 4 types:

1. Multiple pileleiomyomas (derivation of arrector pili muscle)
2. Solitary pileleiomyoma
3. Angioleiomyoma (solitary derivation of smooth muscles of blood vessels)
4. Genital leiomyoma [mainly from the scrotal wall smooth muscles (7)]

Genital leiomyomas tend to be the least common one of the 3 types.

Leiomyomas of genitourinary system are often asymptomatic, except for effects on urinary tract function (8).

These tumors, wherever found in the body, usually involve single organs, but multiple organ involvement has also been reported (9).

Macroscopically, they are greyish white masses with a rubbery consistency with whorled cut surface; and under microscope, they can be characterized by intersecting smooth muscle bundles, which tend to be more prominent around the vessels and ducts. They may show myxoid characteristics and calcifications (10). Necrosis, nuclear atypia, and mitotic activity are unusual (11). The final

diagnosis of the leiomyoma is made on its histopathologic examination based on a cellular proliferation of band spindle cells having a typical morphology with cigar-shaped nuclei and eosinophilic cytoplasm (12).

As a conclusion, leiomyomas found in the scrotum especially arose from spermatic cord are counted in extremely rare occurrences. With the features they have, they can simply lie on near differential diagnoses of serious tumors such as rhabdomyosarcoma or liposarcoma.

A painless right-side palpable scrotal mass made our patient be operated through which spermatic cord leiomyoma was resected.

### Conflict of Interests

Authors have no conflict of interests.

### Acknowledgments

We thank all archives staff of Alavi hospital, Ardabil city, for their assistance.

### References

1. Bulun SE. Uterine fibroids. *N Engl J Med* 2013; 369(14): 1344-55.
2. Bremner F, Kessel FJ, Behnes CL, Trojan L, Heinrich E. Leiomyoma of the tunica albuginea, a case report of a rare tumour of the testis and review of the literature. *Diagn Pathol* 2012; 7: 140.
3. O'Brien J, Loftus B, Barrett C, Torreggiani W.

- Leiomyoma of the testis: a rare testicular mass. *J Clin Ultrasound* 2008; 36(4): 240-2.
4. Woodward PJ, Schwab CM, Sesterhenn IA. From the archives of the AFIP: extratesticular scrotal masses: radiologic-pathologic correlation. *Radiographics* 2003; 23(1): 215-40.
5. Montgomery JS, Bloom DA. The diagnosis and management of scrotal masses. *Med Clin North Am* 2011; 95(1): 235-44.
6. Kuhn MT, MacLennan GT. Benign neoplasms of the epididymis. *J Urol* 2005; 174(2): 723.
7. Newman PL, Fletcher CD. Smooth muscle tumours of the external genitalia: clinicopathological analysis of a series. *Histopathology* 1991; 18(6): 523-9.
8. Gokçe A, Ekmekçioglu O. Leiomyoma originating from the vas deferens. *Turkish Journal of Urology* 2011; 37(1): 75-6.
9. Ghadian A, Hoseini SY. Transvesical enucleation of multiple leiomyoma of bladder and urethra. *Nephrourol Mon* 2013; 5(1): 709-11.
10. Barton JH, Davis CJ, Jr., Sesterhenn IA, Mostofi FK. Smooth muscle hyperplasia of the testicular adnexa clinically mimicking neoplasia: clinicopathologic study of sixteen cases. *Am J Surg Pathol* 1999; 23(8): 903-9.
11. deLuise VP, Draper JW, Gray GF, Jr. Smooth muscle tumors of the testicular adnexa. *J Urol* 1976; 115(6): 685-8.
12. O'Brien J, Loftus B, Barrett C, Torreggiani W. Leiomyoma of the testis: a rare testicular mass. *J Clin Ultrasound* 2008; 36(4): 240-2.