

Superior Vena Cava Syndrome Secondary to Lung Cancer: A Case Report



Victor Olamiposi Olaiya^{1*}, Vincenta Kuukua Agyekum¹, Adefunke Temitope Omotoso²

1. Department of Internal Medicine, Izhevsk State Medical University, Izhevsk, Russia.

2. Department of Internal Medicine, School of Medicine & Dentistry, University of Central Lancashire, Fylde Rd, Preston PR1 2HE.

Use your device to scan and read the article online



Citation Olaiya VO, Agyekum VK, Omotoso AT. Superior Vena Cava Syndrome Secondary to Lung Cancer: A Case Report. Case Reports in Clinical Practice. 2024; 9(3): 119-124.

Running Title Superior Vena Cava Syndrome Secondary to Lung Cancer



Article info:

Received: May 21, 2024

Revised: June 7, 2024

Accepted: June 19, 2024

Keywords:

Superior vena cava syndrome;
Lung cancer; Chronic obstructive pulmonary disease;
Oncology

ABSTRACT

Superior vena cava syndrome (SVCS) is a clinical condition caused by the obstruction of venous return through the superior vena cava (SVC). This report presents a 71-year-old male diagnosed with central lung cancer and chronic obstructive pulmonary disease (COPD) complicated by SVCS. The report details his clinical presentation, diagnostic workup, and management, including chemotherapy and symptomatic treatment. SVCS can significantly affect patient outcomes, especially in cases of malignancy, and requires timely intervention.

Introduction

Superior vena cava syndrome (SVCS) is characterized by the obstruction of blood flow through the SVC, most commonly due to malignancies such as lung cancer and lymphoma (Figure 1). It can also result from thrombus formation due to prolonged catheterization or external compression by mediastinal tumors [1]. SVCS is considered a medical emergency and presents with symptoms related to venous congestion, such as facial swelling, dyspnea, and venous distention in the neck and upper chest (Table 1). Early recognition and appropriate

management are essential to prevent life-threatening complications [2]. This report presents the case of a 71-year-old male with SVCS secondary to lung cancer.

Case Presentation

A 71-year-old male was admitted to the internal medicine department. He presented to the hospital with complaints of worsening dyspnea, facial swelling, and chest pain with symptoms of SVCS. The patient had a significant medical history:

- Diagnosed with COPD in 2018, with a 50-year smoking history.

* Corresponding Author:

Victor Olamiposi Olaiya

Address: Department of Internal Medicine, Izhevsk State Medical University, Izhevsk, Russia.

E-mail: olamummyvicky@gmail.com

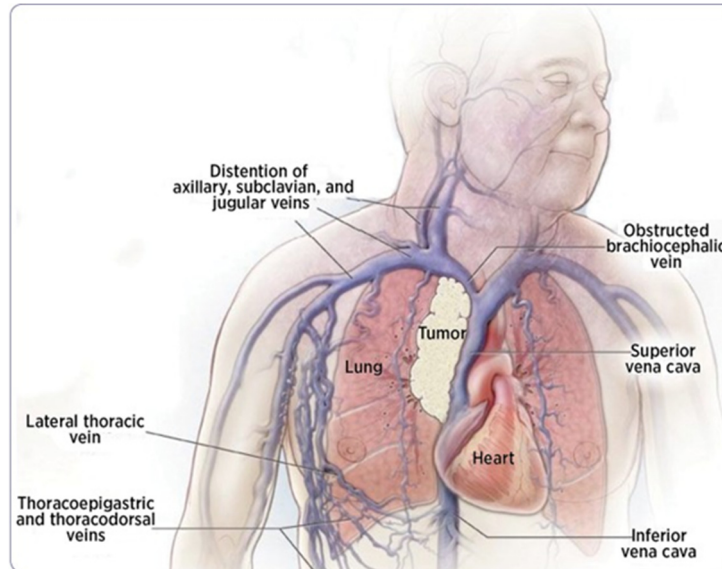


Fig. 1. Pathophysiology of tumor and superior vena cava. Reprinted, with permission, from www.medicoweb.com

Table 1. Frequency of SVCS symptoms (adapted from J. Yahalom [7])

| Symptom | Frequency (%) |
|-----------------|---------------|
| Facial swelling | 82 |
| Arm swelling | 68 |
| Dyspnea | 66 |
| Cough | 50 |
| Chest pain | 19 |
| Dysphagia | 19 |
| Headache | 18 |
| Dizziness | 13 |
| Visual symptoms | 9 |

- COVID-19 vaccination in 2021, followed by general health deterioration.
- Subsequent diagnosis of right lung cancer.
- Completed seven cycles of chemotherapy with disease progression (March to September 2023).

Upon examination, the patient was in moderate but stable condition. He exhibited the following signs of SVCS: cyanotic skin, distended neck and chest wall veins, positive Pemberton’s sign (Figure 3), and edema of the upper extremities and face.

He reported classic symptoms of SVCS, including headache, dizziness, hoarseness, dysphagia, and chest discomfort. The physical examination revealed significant venous congestion and respiratory distress.

Pertinent physical findings included blood pressure 124/64, respirations 20, pulse 72 regular, temperature 97.8°F, diffuse edema in the neck, and dilated, engorged blood vessels on the chest and under the tongue (Figure 2).

Imaging and Diagnostic Tests

- **Chest CT:** Showed a central right lung mass compressing the SVC, with metastases to mediastinal lymph nodes, right-sided pleural effusion, and bilateral pneumopleurofibrosis (Figure 4).
- **Spirometry:** Demonstrated severe obstructive lung disease with a forced vital capacity (FVC) of 2.08 L (59% predicted), forced expiratory volume in one second (FEV1) of 0.76 L (27% predicted), and an FEV1/FVC ratio of 37.7%, consistent with severe COPD.

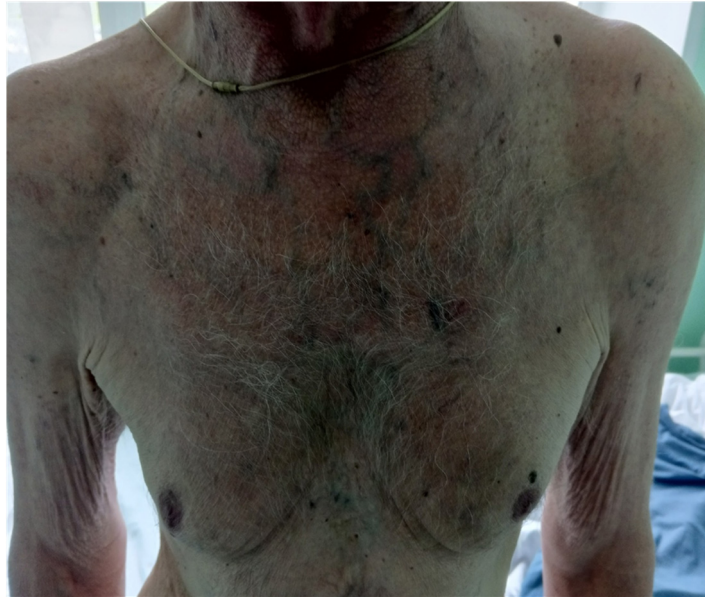

Fig. 2. Engorged blood vessels on the chest.

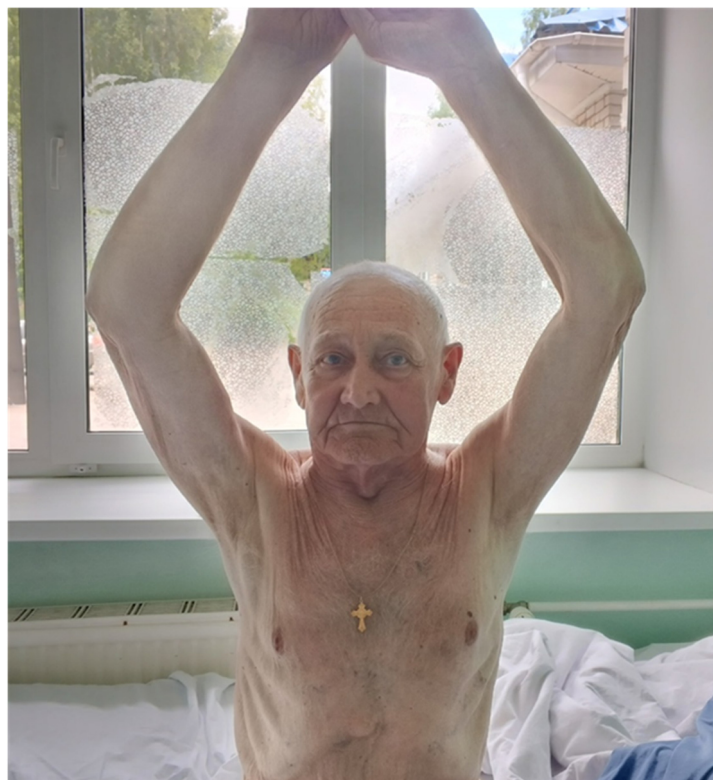

Fig. 3. Positive pemberton sign (indicative of SVCS marked by the presence of facial congestion and cyanosis, as well as respiratory distress after approximately one minute)

Patient's Medical Timeline

- **2018:** Initial diagnosis of Chronic Obstructive Pulmonary Disease (COPD).
- **2021:** Received COVID-19 vaccination & experienced subsequent general health decline.
- **Early 2023:** Diagnosed with right lung cancer.
- **March - September 2023:** Underwent seven cycles of first-line chemotherapy.
- **December 2023:** Detection of metastases and initiation of second-line chemotherapy.

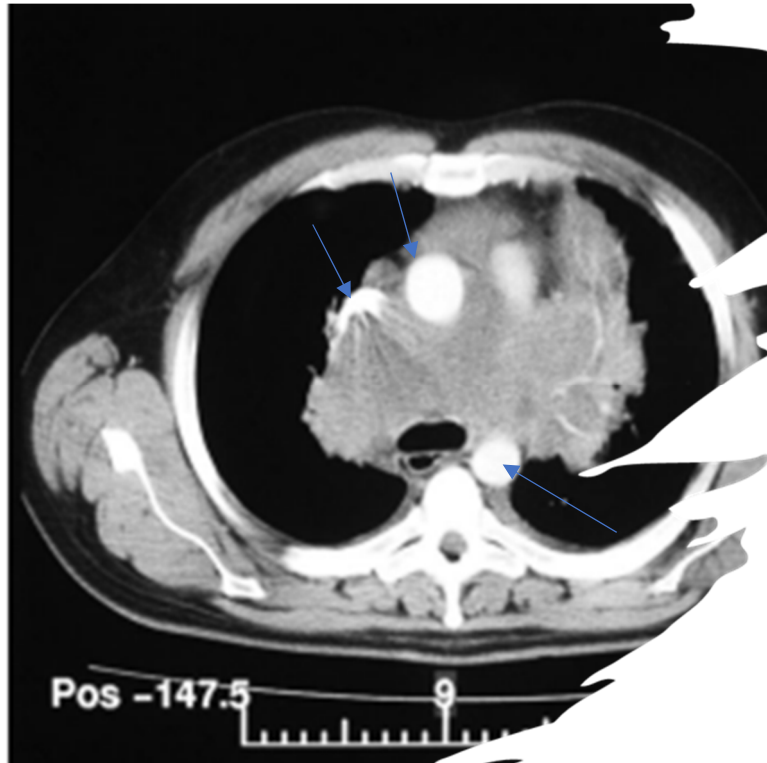


Fig. 4. CT scan showing central right lung mass compressing the SVC, with metastases to mediastinal lymph nodes

- **June 5, 2024:** Hospitalized with symptoms of Superior Vena Cava Syndrome (SVCS).

Diagnosis The final clinical diagnosis was Stage IV non-small cell lung cancer (NSCLC) T2N0M1 complicated by SVCS and severe COPD. The SVCS was attributed to the tumor’s direct compression of the SVC, leading to impaired venous return and venous congestion. Additionally, thrombotic obstruction from prolonged catheterization may have contributed to the pathogenesis of SVCS [4].

Treatment and Outcome

Management of SVCS requires both symptom control and treatment of the underlying cause. In this patient’s case, the focus was on relieving the venous obstruction and managing his advanced lung cancer. The treatment plan included:

1. Chemotherapy: The patient had undergone six cycles of first-line chemotherapy with carboplatin and paclitaxel, but his disease progressed after three months. A second-line chemotherapy regimen was initiated following the detection of metastases in December 2023.

2. Symptomatic Treatment:

- **Oxygen therapy** to relieve dyspnea.

- **Corticosteroids** to reduce inflammatory edema around the SVC.

- **Diuretics** to manage fluid retention and reduce edema.

3. Radiation Therapy: Although not utilized in this case, radiation therapy can significantly shrink tumours and compress the SVC, alleviating SVCS [5].

4. Endovascular Intervention: In severe cases of SVC obstruction, stenting or balloon angioplasty is considered. However, the patient’s clinical condition and tumour progression limited the application of these options.

The prognosis for patients with SVCS depends on the underlying etiology. In cases of malignancy, the overall survival is determined by the response to cancer treatment. For this patient, the progression of lung cancer, despite chemotherapy, indicated a poor prognosis. Management focused on palliative care and symptom relief [6,7].

Discussion

Superior vena cava syndrome (SVCS) is a life-threatening condition that requires urgent diagnosis and intervention, especially in cases related to

malignancy. The leading causes of SVCS include external compression of the SVC by a tumor, invasion of the vessel by malignant cells, or thrombosis due to indwelling catheters. Lung cancer, particularly NSCLC, accounts for the majority of SVCS cases [1, 4].

The patient in this case presented with the typical symptoms of SVCS, including dyspnea, facial edema, and chest pain. His long history of smoking and COPD contributed to the complexity of his presentation. Advanced imaging, mainly chest CT, confirmed the diagnosis by visualizing the tumor's compression of the SVC and mediastinal lymph node involvement [2].

Chemotherapy remains the primary treatment for SVCS caused by malignancy. In this case, the patient underwent both first- and second-line chemotherapy, but the disease continued to progress. Radiation therapy and endovascular interventions, such as SVC stenting, could have been considered if the patient's condition had permitted more aggressive treatment [3].

Management of SVCS in the context of progressive cancer presents significant challenges. While endovascular stenting is often effective for rapid symptom relief [5], the decision to pursue such interventions must be balanced against the patient's overall prognosis and goals of care.

The coexistence of severe COPD (FEV1 27% of predicted) further complicates management, as it limits therapeutic options and contributes to respiratory symptoms [6]. This case emphasizes the need for a multidisciplinary approach to managing patients with complex cardiopulmonary pathologies.

This case underscores the importance of a multidisciplinary approach to managing SVCS. Early diagnosis and intervention, including a combination of systemic therapy and supportive measures, are vital to improving patient outcomes. The management of SVCS must be tailored to the underlying cause and the patient's overall clinical condition.

Patient Perspective

The patient expressed gratitude for the care received and frustration with the persistence of symptoms despite treatment. He stated, "While I appreciate all the medical team's efforts, I am disappointed that my breathing has not improved as much as I had hoped. The swelling in my face and arms makes me feel uncomfortable and self-conscious."

Conclusion

Superior vena cava syndrome is a severe complication of advanced malignancies such as lung cancer. Early recognition and treatment of the condition are essential to alleviate symptoms and improve quality of life. This case highlights the importance of a comprehensive diagnostic and therapeutic approach to SVCS in patients with advanced lung cancer. While chemotherapy remains the cornerstone of treatment, a multidisciplinary approach that includes symptomatic management and, in select cases, endovascular interventions can be beneficial.

Ethical Considerations

There were no ethical considerations to be considered in this article.

Compliance with ethical guidelines

The patient provided written informed consent to publish this case report and accompanying images. If requested, the editor-in-chief of this journal can review a copy of the consent.

Funding

No funding was received to assist with the preparation of this manuscript.

Conflict of Interests

The authors have no conflict of interest to declare.

References

- [1] Straka C, Ying J, Kong FM, Willey CD, Kaminski J, Kim DW. Review of evolving etiologies, implications and treatment strategies for the superior vena cava syndrome. Springerplus. 2016 Feb 29;5:229. <https://doi.org/10.1186/s40064-016-1900-7>
- [2] Lepper PM, Ott SR, Hoppe H, Schumann C, Stammberger U, Bugalho A, et al. Superior vena cava syndrome in thoracic malignancies. Respir Care. 2011 May;56(5):653-66. <https://doi.org/10.4187/respcare.00947>
- [3] Spyrtos D, Papadaki E, Lampaki S, Kontakiotis T. Chronic obstructive pulmonary disease in patients with lung cancer: prevalence, impact and management challenges. Lung Cancer (Auckl). 2017 Aug 3;8:101-7. <https://doi.org/10.2147/LCTT.S117178>

- [4] Wan JF, Bezjak A. Superior vena cava syndrome. *Hematol Oncol Clin North Am.* 2010 Jun;24(3):501-13. <https://doi.org/10.1016/j.hoc.2010.03.003>
- [5] Lanciego C, Chacón JL, Julián A, Andrade J, López L, Martínez B, et al. Stenting as the first option for endovascular treatment of malignant superior vena cava syndrome. *AJR Am J Roentgenol.* 2001 Aug;177(3):585-93. <https://doi.org/10.2214/ajr.177.3.1770585>
- [6] Naliato M, Attinà D, Fabbri M, Agostini A, Russo G, Bazzocchi A, et al. Superior vena cava syndrome: A systematic review. *Diagnostics (Basel).* 2022 Sep 5;12(9):2133. <https://doi.org/10.3390/diagnostics12092133>
- [7] Yahalom J. Superior vena cava syndrome. In: DeVita VT Jr, Lawrence TS, Rosenberg SA, editors. *DeVita, Hellman, and Rosenberg's Cancer: Principles and Practice of Oncology.* 11th ed. Philadelphia: Wolters Kluwer; 2019. p. 2118-29.